

SURGICAL
MEDICAL
AND
OPERATIVE

Cornell University Library

BOUGHT WITH THE INCOME
FROM THE

SAGE ENDOWMENT FUND

THE GIFT OF

Henry W. Sage

1891


A. 145876

5/4/1901

CORNELL UNIVERSITY LIBRARY



3 1924 099 273 652



Cornell University Library

The original of this book is in
the Cornell University Library.

There are no known copyright restrictions in
the United States on the use of the text.

APPLIED ANATOMY.

APPLIED ANATOMY:

SURGICAL, MEDICAL,

AND

OPERATIVE.

BY

JOHN M'LACHLAN, M.D., B.Sc., F.R.C.S. ENG.,

MASTER IN SURGERY, UNIVERSITY OF EDINBURGH;

LICENTIATE OF THE SOCIETY OF APOTHECARIES, LONDON, ETC.

Third Edition.

ILLUSTRATED WITH 238 ENGRAVINGS.

VOL. II.

EDINBURGH:

E. & S. LIVINGSTONE, 15 TEVIOT PLACE.

LONDON: BAILLIÈRE, TINDALL, & COX;

SIMPKIN, MARSHALL, HAMILTON, ADAMS, KENT, & CO.

1890.

PRINTED BY
E. & S. LIVINGSTONE
4 MELBOURNE PLACE
EDINBURGH.

LONDON: SIMPKIN, MARSHALL, HAMILTON, ADAMS, KENT, AND CO.
AND BAILLIÈRE, TINDALL, AND COX.
GLASGOW: SIME; STENHOUSE.
DUBLIN: FANNIN AND CO.; GILL AND SON.
MANCHESTER: J. E. CORNISH.

PREFATORY NOTE TO VOL. II.

MY thanks are due to Dr MACEWEN, of Glasgow, who very kindly supplied me with the Woodcuts illustrating his operation for the radical cure of Hernia. The operation in question is given in his own words, in order that there might be no mistake.

J. M'L.

July 1889.

CONTENTS OF VOL. II.

CHAPTER	PAGE
PREFACE	v
LIST OF ENGRAVINGS	ix
XXIX. Head and Neck	1
XXX. Wounds of the Scalp	62
XXXI. The Upper Extremity	136
XXXII. The Lower Extremity	158
XXXIII. The Lower Extremity (<i>continued</i>)	174
XXXIV. The Chest	198
XXXV. The Spine	230
XXXVI. The Abdomen	261
XXXVII. The Abdomen (<i>continued</i>)	295
XXXVIII. The Abdomen (<i>continued</i>)	321
XXXIX. The Abdomen (<i>continued</i>)	339
XL. The Abdomen (<i>continued</i>)	380
XLI. The Pelvis	405
XLII. The Pelvis (<i>continued</i>)	429
XLIII. The Pelvis (<i>continued</i>)	450
XLIV. The Pelvis (<i>continued</i>)	476
XLV. Gynæcological Operations	506
XLVI. Origin and Insertion of Muscles	523
XLVII. Terms used in Eye Surgery	540
XLVIII. Addenda	548
INDEX	563

LIST OF ENGRAVINGS.



FIG.	PAGE
120. Middle Line of the Neck	5
121. Knife for Excision of Tonsil	36
122. Venesection from External Jugular	42
123. Lines of the Branchial Clefts	44
124. Development of Mouth	48
125. The Bones of a Typical Palate	48
126. Completely Cleft Palate	49
127. Operation for Hare Lip—First Form (First Stage)	52
128. Do. Do. (Second Stage)	52
129. Operation for Hare Lip—Second Form (First Stage)	52
130. Do. Do. (Second Stage)	52
131. Operation for Hare Lip—Third Form (First Stage)	52
132. Do. Do. (Second Stage)	52
133. Do. Do. (Third Stage)	52
134. Operation for Hare Lip—Fourth Form (First Stage)	52
135. Do. Do. (Second Stage)	52
136. Operation for Hare Lip—Fifth Method	54
137. Duncan's Method—Lip in Section	54
138. Duncan's Method—Stitching	54
139. Duncan's Operation—Finished	54
140. To pass the Sutures in Cleft Palate	56
141. The Scalp	64
142. Circle of Willis	69
143. Cerebral Emboli	70
144. The Internal Capsule	71
145. Fissure of Rolando and Motor Areas	78
146. Dr Reid's Method	79

FIG.	PAGE
147. Lobes of the Brain	81
148. Hey's Saw	86
149. Pott's Puffy Tumour (after SPENCE)	88
150. Kocher's Excision of the Tongue	104
151. Regions of the Nose	109
152. The Facial Nerve	120
153. Fascia about Axilla	141
154. Veins at the Bend of the Elbow—Right Side	144
155. Venesection	145
156. Section of the Wrist	151
157. Palmar Cutaneous Nerves	156
158. Dorsal Cutaneous Nerves	156
159. Structures between Poupart's Ligament and the Bone	158
160. Hip Joint Disease—Position of Knee	166
161. Hip Joint Disease—Lumbar Curve	166
162. Section of Thigh (from CUNNINGHAM)	172
163. Genu Valgum Triangle—Right Side	181
164. Macewen's Osteotome	182
165. A Chisel	182
166. Left Ankle, from Above	191
167. Section of Leg (from CUNNINGHAM)	192
168. Plantar Cutaneous Nerves	193
169. Dorsal Cutaneous Nerves	193
170. Relation of the Heart and Great Vessels to Chest Wall	199
171. Cause of Bruit de Diable	205
172. Section of Cord	234
173. Conduction of Motor and Sensory Impulses	237
174. Reflexes of Cord (after BRAMWELL)	238
175. Anterior Abdominal Wall	262
176. Anterior Abdominal Wall	264
177. Sheath of Rectus (from CUNNINGHAM'S "Abdomen")	265
178. Abdominal Walls (from CUNNINGHAM'S "Abdomen")	295
179. Posterior Abdominal Wall, from Behind	299
180. Colon and Peritoneum—Empty.	303
181. Colon and Peritoneum—Distended	303
182. Lembert's Suture—Surface View	310

List of Engravings.

xi

FIG.	PAGE
183. Lembert's Suture—Side View	310
184. Lembert's Suture Tightened	310
185. Stab through Base of Lung	312
186. Space concerned in Inguinal Hernia, from the Inside	341
187. Normal Condition of the Processus Vaginalis in the Adult	344
188. Spence's Hernia Director	349
189. Hernia Knife	349
190. Macewen's Needles	364
191. Site of Incision	365
192. Separating the Peritoneum	366
193. Treatment of Sac	367
194. Thread introduced to pull up Sac	368
195. Sac in New Position	369
196. Conjoint Tendon	370
197. Loop in Conjoint Tendon	371
198. External Pillar	372
199. Thread ready for Tying	373
200. Congenital Inguinal Hernia	375
201. Condition of the Processus Vaginalis in Congenital Hernia	376
202. Condition of the Processus Vaginalis predisposing to the Infantile and Encysted Forms of Hernia	377
203. Infantile Hernia	377
204. Encysted Hernia	378
205. Condition of the Processus Vaginalis in Funicular Hernia	378
206. Formation of the Femoral Sheath	381
207. Course and Coverings of Femoral Hernia (after HEATH)	383
208. An Ordinary Fatty Tumour	383
209. "Fatty Hernia"	385
210. Femoral Epiplocele	385
211. Vessels near Crural Ring—Normal	386
212. Aberrant Obturator—Non-dangerous Variety	387
213. Aberrant Obturator—Dangerous Variety	388
214. Ischio-Rectal Fossa	395
215. Professor Chiene's Staff	407
216. Lithotomy Tube	407
217. The Prostate in Lithotomy	419

FIG.		PAGE
218.	A False Passage	432
219.	Syme's Staff	439
220.	The Prostate	444
221.	Section of Testicle	450
222.	Tapping Vaginal Hydrocele	455
223.	Encysted Hydrocele of Cord	458
224.	Base of Bladder showing the Trigone	466
225.	Spence's Operation (after SPENCE)	467
226.	Whitehead's Operation—First Stage	481
227.	Whitehead's Operation—Second Stage	481
228.	General Structure of Abdomen	487
229.	Section of Penis	494
230.	Phimosis	496
231.	Paraphimosis	498
232.	Amputation of Penis—First Stage	499
233.	Amputation of Penis—Second Stage	499
234.	Psoas Abscess	502
235.	Hare's Angle	551
236.	Articulation of Carpal Bones	556
237.	Operation for Salivary Fistula	558
238.	Artificial Anus	559

APPLIED ANATOMY:

SURGICAL, MEDICAL, AND OPERATIVE.

CHAPTER XXIX.

HEAD AND NECK.

RELATIONS OF THE TRACHEA.

THE trachea extends from the lower border of the cricoid cartilage (or opposite the sixth cervical vertebra) to the body of the fourth dorsal vertebra—disc between the fourth and fifth (QUAIN)—where it divides into the two bronchi. The point of bifurcation corresponds, in front, to the junction between the manubrium and gladiolus of the sternum; at this point also it is crossed by the arch of the aorta. It is usually said to extend from the fifth cervical to the third dorsal vertebra; but in the above numbers I have followed the teaching of the Edinburgh School. Its position varies with the position of the head—flexed or extended; when the head passes from the ordinary position to one of extension, nearly an inch more of the trachea is drawn up into the neck above the sternum. The larynx and upper part of the trachea are also raised during deglutition, and during inspiration its length in the neck is diminished, because the upper margin of the thorax is raised. These changes of position are readily admitted because of the fibro-elastic membrane, which forms the basework of the trachea, and in which the cartilaginous rings are embedded. The movements taking place during deglutition are useful in sharply diagnosing all tumours connected with the trachea—*e.g.*, goitre;

the patient is directed to swallow, when, if the tumour is connected with the trachea, it will rise with it during that act.

In the Neck the trachea occupies the middle line, lying in front of the œsophagus and vertebral column. In **front** of it we find the skin, superficial fascia, communicating branches between the two anterior jugular veins, deep cervical fascia, and then the sterno-hyoid and sterno-thyroid muscles, isthmus of the thyroid body, the inferior thyroid veins, and the thyroidea ima artery, if it exists. The anterior jugular veins lie a little to one side of the middle line, and above the deep fascia. At the **sides** we find the common carotid arteries, the lateral lobes of the thyroid body, inferior thyroid arteries, and the recurrent laryngeal nerves. At the root of the neck, in the episternal notch, the innominate artery and the left carotid cross it obliquely to gain its right and left side, respectively.

In the Thorax.—In **front**, the upper part of the sternum, and the origin of the sterno-hyoid and sterno-thyroid muscles, the remains of the thymus gland, left innominate vein, transverse part of the arch of the aorta with its branches, and the deep cardiac plexus. **Behind** is the œsophagus; on the **right side** the pleura and right vagus; and on the **left side** the pleura, left vagus, left recurrent laryngeal nerve, and left common carotid artery. The length of the trachea is about four and a half inches, and its diameter about three-quarters of an inch. The *right* bronchus is shorter, wider, and more horizontal in its course; the *left* is longer, narrower, and more oblique in direction. It is usually said that foreign bodies, for these reasons, are more apt to pass into the left bronchus; but the larger size of the opening of the right bronchus, and the fact that therefore the septum is to the left of the middle line, would seem to indicate that foreign bodies would more readily find their way into the right bronchus. Further, it has been shown by AEBY, that the right bronchus proper is not more horizontal than the left, but, if anything, rather more oblique; the undivided part, however, of the bronchus is shorter, because it soon gives off a branch to the upper lobe of the right lung (*epiarterial bronchus*). According to this view, the upper lobe of the left lung is the homologue of the middle lobe of the right lung.

TRACHEOTOMY.

By this is meant the making of an opening in some part of the trachea. **Laryngotomy**—when the opening is made in the crico-thyroid membrane—usually by a single thrust; **Tracheotomy**—when the opening is made through some part of the trachea itself, either above or below the isthmus of the thyroid body; and hence we have the *high* and the *low* operations. **Laryngo-tracheotomy**.—In this operation the opening is made through the crico-thyroid membrane, the cricoid cartilage, and the upper rings of the trachea. In **Thyrotomy**, the thyroid cartilage is split in the middle line, in whole or in part, by a vertical incision, and the interior of the larynx exposed; the two halves are then held aside, while foreign bodies or morbid growths are removed from the cords or ventricles. In cases where the lower part only of the thyroid cartilage is split, it will be necessary to divide the upper two or three rings of the trachea, to give more room for manipulation; with partial division thus, the power of speech is less likely to be so seriously affected afterwards, as the vocal cords are less disturbed.

The opening in the wind-passage may be temporary or permanent. A **temporary** opening may be required for—(1) Obstructive œdema glottidis; (2) acute laryngitis; (3) spasms from pressure on, or irritation of, the recurrent laryngeal nerve; (4) emphysema of the loose connective tissue of the neck, as from a penknife wound; (5) scalds of rima, by boiling water or caustic fluids; (6) foreign bodies in the air passages; (7) masses of food in the gullet; (8) croup; (9) diphtheria; and (10) many operations about the jaws, tongue, and palate. In diphtheria the obstruction is always at the chink of the glottis, but in croup it is in the trachea and bronchi as well. A **permanent** opening may be required for—(1) Chronic diseases of the larynx, resulting in thickening of the mucous membrane, abscesses, necrosis of cartilages—as from syphilis, tubercular disease, fevers, and cancer; (2) polypi of the larynx; (3) laryngeal phthisis. Some Surgeons doubt whether it should be opened in croup and diphtheria. In croup, the dangers are—(a) Obstruction to the larynx; and (b) extension of the disease down to the lungs, So also in diphtheria we have similar dangers—(a) Obstruction

to larynx and pharynx; and (b) pulmonary inflammation, blood poisoning, and exhaustion. If the disease spreads downwards, opening the trachea may not save the patient's life; but it at least saves him from a very distressing kind of death, and it may possibly save his life. Hence, even in croup and diphtheria, opening the windpipe is a perfectly justifiable operation, so long as it gives temporary relief or affords the *least chance* of saving the patient's life. Besides, the operation of opening the windpipe is not meant to *cure the disease*, but only to get rid of the danger of immediate death from asphyxia, and to *rest* the larynx. In many cases of diphtheria, however, death is not due to asphyxia, but to asthenia, caused by the absorption of the poison into the circulation—if, indeed, it be not in the blood from the very first—and in this class of cases it would be worse than useless to perform the operation. It is also useless to open it in cases where the obstruction is low down in the trachea; to distinguish this from laryngeal obstruction, the laryngoscope must be employed, and much assistance will be gained by remembering that in **laryngeal** obstruction the larynx itself moves energetically with respiration, whereas in **tracheal** dyspnoea it is stationary.

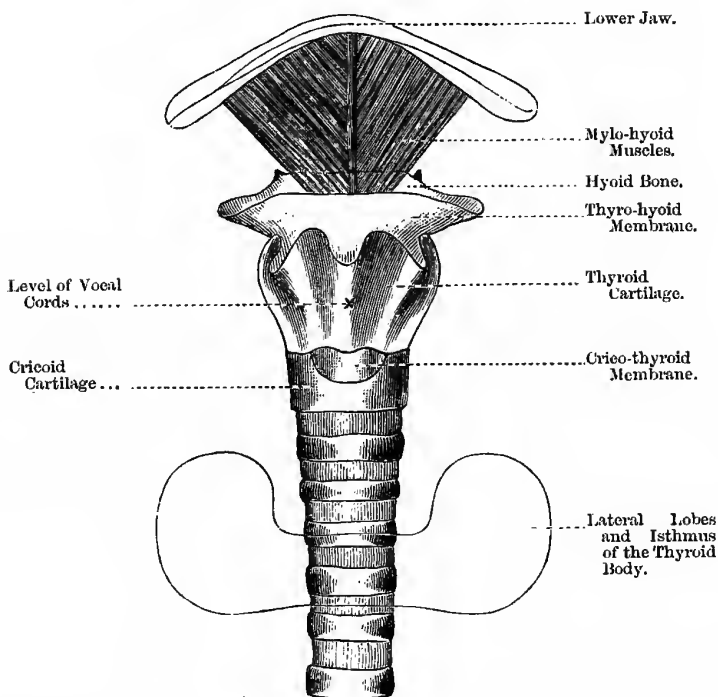
In the middle line of the Neck we find the following structures (Fig. 120):—(1) Symphysis of the lower jaw; (2) central tendon of the mylo-hyoid muscles; (3) body of the hyoid bone; (4) thyro-hyoid membrane; (5) thyroid cartilage; (6) crico-thyroid membrane and arteries; (7) cricoid cartilage, which can be distinguished from the rings of the trachea by its more resistant feel; opposite this cartilage, as already pointed out, is the "**carotid tubercle**" of the sixth cervical vertebra, and opposite this point also is the usual situation for applying a ligature to the common carotid, above the omo-hyoid; (8) two or three rings of the trachea; (9) isthmus of the thyroid body (usually crossing about the third or fourth rings); and (10) the trachea again. The level of the vocal cords corresponds to the middle of the anterior margin of the thyroid cartilage (QUAIN); GRAY, however, places the cords on a lower level—one quarter of an inch above the lower edge of the cartilage.

The Position of the Patient.—He is to be placed on a table, facing a good light, and his shoulders are well raised by pillows; the head is thrown as far back as practicable, and kept perfectly

straight and steady by the wrists of an assistant, standing at the patient's head. A small firm pad should be placed under the neck, so as to throw the windpipe forwards. The assistant is also to be provided with a blunt hook in each hand, by which he retracts the soft parts as they are divided—taking care not to

Fig. 120.

MIDDLE LINE OF THE NECK.



displace them at all to one side of the middle line, which is more apt to happen when the hooks are confided to the care of *two* assistants. Another assistant is to stand opposite the Surgeon, to sponge the wound and secure bleeding vessels with catch forceps (WELLS'S). A third may administer chloroform. By throwing the head well backwards the trachea is drawn up into the neck,

and so gives the Surgeon more room ; further, it helps to steady it—the mobility of the trachea being one of the difficulties of the operation—and also brings it nearer the surface, as well as ensuring, as far as possible, a clear air-way to the lungs. The first assistant must be specially cautioned to keep the head exactly straight and in the middle line, and at the same time to avoid squeezing in the mouth or nostrils.

Instruments required.—Scalpel, SPENCE'S hernia director, a good supply of WELLS'S forceps, dissecting forceps, blunt hooks, a sharp hook to fix and draw forward the trachea, trachea tubes and tapes, trachea dilator, sponges, ligatures, scissors, etc. The Surgeon stands on the right side.

Incision.—In the **high** operation, begin the incision over the middle of the thyroid cartilage ; in the **low**, begin over the cricoid cartilage, and carry it downwards, *exactly* in the middle line, for about two or three inches. By this incision (1) the skin, (2) fascia, and (3) fatty tissue are divided. On each side of the median line we find an anterior jugular vein, which are very often connected by a transverse communicating branch : these must, if possible, be avoided, or at once secured. (4) Cut through the inter-muscular fascia connecting the edges of the sterno-hyoids and sterno-thyroids, and separate them with the handle of the scalpel ; also turn aside the inferior thyroid veins, the *thyroidea ima* artery (if present), and the isthmus of the thyroid body, and some loose cellular tissue will now be brought into view. After the deep fascia of the neck is divided the *blade* of the knife must be laid aside ; after this use the handle of the knife or SPENCE'S hernia director. Turn aside this loose tissue with the point of the finger or the handle of the scalpel, and the trachea is then exposed, and may be opened (either above or below the isthmus of the thyroid body, as circumstances may determine) thus :—Transfix and draw it forwards by a sharp hook inserted into the cricoid cartilage, and push in the point of the knife—the blade being held between the finger and the thumb half-an-inch from the point, to avoid the risk of transfixing the œsophagus,—with its *back* towards the sternum (this is done whether the operation be above or below the isthmus), and cut through three or four rings, and introduce the tube, taking care first that all bleeding

has ceased—unless the bleeding be due to the semi-asphyxiated state of the patient, when obviously the best means to stop it is to open the trachea as quickly as possible. In the **high operation**, the fascia connecting the isthmus to the cricoid cartilage can be divided by a transverse incision, and the isthmus depressed by the handle of the scalpel, and held there by a blunt hook, in cases where it is necessary to increase the space; or the isthmus may be freely divided in the middle line if necessary, each side being first clamped by a pair of WELLS'S forceps. The opening in the trachea and the tissues covering it must correspond exactly, otherwise mucus and air will escape into the cellular tissue, producing emphysema. When the opening is made the handle of the knife must be inserted flat-wise and then turned at right angles, while the Surgeon turns away his head till the patient coughs, and after this he puts in a trachea tube, while the handle of the knife causes the opening to gape; make certain that the tube has passed into the trachea and not into the loose tissue beneath the deep cervical fascia. Some prefer to use a special trachea dilator. The tube is then to be fixed by means of tapes, attached to the *outer sheath*, which are then to be tied on one side of the patient's neck. Take care that the tapes are not too loose, lest both tubes be forced out during a fit of coughing, and the patient be suddenly choked.

The **Trachea Tube** must be of a size corresponding to the age of the patient: in children under eighteen months, a diameter of about one-sixth of an inch is said to be sufficient; from that age up to four years the diameter should be about a quarter of an inch. In any case it must be of such a size as to admit air freely, but without distending the trachea, and should always be double. The inner tube should be *loose* and a *little longer* than the outer tube, so that it may be driven out by coughing should it happen to become blocked up, and still the patient can breathe through the outer tube. Were it shorter, or even the same length as the outer tube, then, in cases of block, removal of the inner tube would not relieve the patient, as the outer sheath would still be plugged. The *outer* tube has often an opening on its upper and convex surface, by means of which, when the inner tube is removed, one can try, by closing the external opening with the

thumb, whether the patient is prepared to breathe through his larynx again; but in this case the inner tube must be always introduced when the patient takes food or drink. In no case should there be an opening in this situation through *both* tubes, for then the patient would also breathe through his larynx, and keep it in a condition of unrest. The tube, in openings of a temporary nature, can usually be removed from the sixth to the thirteenth day.

After Treatment.—The extreme ends of the wound are approximated by horse-hair sutures, or perhaps better left entirely open. The bed must be surrounded by a canopy which must be filled with a warm moist atmosphere, and yet contain plenty of fresh air; a careful nurse must be provided, whose duty it is to look after the tube and wound, keeping the inner tube clear, and its outer end covered with warm moist gauze or a small sponge. The causes of death after this operation are—(1) The disease necessitating the operation; (2) interlobular suppurative pneumonia, from blood being inhaled at the moment the trachea was opened; and (3) bronchitis from the inhalation of cold air, as the warming apparatus provided by nature (the nose) is out of use for the present, and its place must therefore be filled by artificial means, such as the bronchitis kettle, warm moist gauze, etc.

RÉSUMÉ of the high operation:—

1. Place the patient in a proper position.
2. Make a sufficiently long incision, beginning over the middle of the thyroid cartilage, and keeping exactly in the *middle line*.
3. Divide the skin, fat, and superficial fascia, and secure or draw aside any evident vein, such as the anterior jugulars.
4. Divide the deep cervical fascia, and draw apart the sterno-hyoid and sterno-thyroid muscles.
5. With the handle of the knife expose the trachea and isthmus of the thyroid body, and feel for the lower edge of the cricoid cartilage.
6. Pinch up the fascia over the trachea at this point, and divide it by a small transverse incision close to the

cricoid cartilage; separate it from the trachea by means of SPENCE'S hernia director, free it still more from the cricoid cartilage if necessary, and push down the isthmus with the handle of the scalpel.

7. Transfix and draw forward the trachea, and open it in the middle line, with the blade of the scalpel held between the finger and thumb about half-an-inch from its point, the back of the knife being directed towards the sternum.
8. Keep the opening patent by the handle of the scalpel, or SPENCE'S double blunt hook; let patient cough, then introduce and fix the tube.

NOTE.—(1) If the incision be not exactly in the middle line, it will be difficult to keep the tube in its place; and, besides, the carotid arteries might be injured. (2) Above the isthmus the trachea is quite superficial, and, as a rule, has no veins of consequence in front, except a communication between the superior thyroids or anterior jugulars; where the isthmus crosses (about the third or fourth rings), there is usually a plexus of veins, besides the isthmus itself; below the isthmus, the trachea is more deeply placed, being covered, in addition to the superficial structures, by the sterno-hyoid and sterno-thyroid muscles, the large inferior thyroid veins, and sometimes by a special arterial branch to the thyroid body—the “thyroidea ima.” (3) In stout, short-necked persons, the lower part of the trachea is more deeply placed.

The chief difficulties of the low operation are:—(1) The trachea is deeper, as it gradually recedes from the surface as it passes downwards; (2) the inferior thyroid veins and the anterior jugulars, with a cross branch between them, are in the way; (3) the danger to the isthmus is greater, because we must cut *towards* it, in order to avoid the important structures behind the upper part of the sternum; (4) the thymus body may be in front of this part; (5) the occasional presence of the “thyroidea ima;” (6) the left innominate vein may take an unusually high course, and is all the more likely to be in the way when the head is thrown back; and (7) the carotids may arise by a common trunk, and in such a case the right passes in front of the lower part of the trachea in the neck, in order to reach its usual situation.

TRACHEOTOMY IN CHILDREN.

Here the relations of the parts are somewhat altered. The neck is shorter ; "but, relatively, the space is greater between the isthmus of the thyroid body and the top of the sternum, so that the cervical part of the trachea is longer than in the adult" (SPENCE). But in the child the trachea is smaller, more deeply placed, and more movable than in the adult, and less resistant to the finger, so that it may readily be squeezed flat, or pushed aside; without one being aware of it unless care be exercised; further, it is more flattened anteriorly than in the adult; also, the danger from hæmorrhage is greater, on account of the large size of the venous plexus in connection with the thyroid and thymus glands. There is more subcutaneous fat too; and the carotids are in closer relation to the trachea, so that a *slight* deviation from the middle line may wound one or other of these important arteries. The innominate artery and left innominate vein are higher in the child than in the adult. The presence and large size of the thymus body in the child will further complicate the operation. According to Dr SYMINGTON the usual position of the larynx in relation to the vertebral column in the new-born child is from the lower border of the atlas to the middle of the fourth cervical vertebra; in the adult it extends from the middle of the third cervical to the lower border of the sixth cervical. He does not believe that this high position is due to its relatively small size, as often stated; and he further believes that its downward movement is caused by the growth of the facial portion of the skull.

A small hard pillow, such as a stocking stuffed with towels, is placed under the neck, and the episternal notch is taken as the **guide**, the incision beginning a finger's-breadth above this; this point is chosen as the guide, because in the child it is difficult to be quite sure about the position of the cricoid cartilage, as it is softer than in the adult. It is very important to keep both the head and the incision exactly in the middle *line*.

Tracheotomy is *the* operation for children. In the child the crico-thyroid space is too small to allow of the introduction of a tube of sufficient calibre to support life, and therefore tracheotomy should always be preferred. Not only is the opening too small,

but it is also too near the larynx and vocal cords, and hence the tube may cause much irritation and even ulceration of the larynx and necrosis of the cartilages, as the conditions in the child requiring this operation are usually of an *acute* inflammatory nature.

In the child it is better for the Surgeon to grasp and steady the whole of the structures, including the trachea, between the two carotids (*i.e.*, excluding the carotids) between the finger and thumb of his left hand; in this way he will, with most certainty and with greatest ease reach and open the trachea, and with less risk of wounding important neighbouring organs. Whether this operation is performed in children or in adults do not put it off till the patient is moribund, and never leave the operation uncompleted, when once begun, whether the patient be alive or dead. It should be performed whenever the voice is lost or nearly lost, and the degree of obstruction is marked as shown by the indrawing of the lower ribs, the epigastrium, and the episternal notch, during inspiration. It should be remembered that an enlarged thymus gland in infants may cause great dyspnoea, and even suffocation.

LARYNGOTOMY.

The crico-thyroid membrane is quite superficial, and may be felt as a slight depression about one inch below the "pomum Adami." If the case is urgent, open by plunging in the knife at once; if not, we may take the matter more coolly. Over the space make a vertical incision in the middle line through the skin, about an inch in length, and then make a *cross* cut through the membrane. The only danger likely to arise is hæmorrhage from the small arteries which cross and anastomose in front of the membrane (the crico-thyroid branches of the superior laryngeals). They are seldom a source of trouble; and by making a *cross* incision they are not likely to be wounded. Cases, however, are on record where serious and even fatal hæmorrhage occurred from these vessels; I have myself seen a subject in the dissecting-room where a trunk as large as the radial artery crossed in front of the crico-thyroid membrane.

Laryngotomy is to be preferred in the adult because:—(1) The opening is often quite as good as in the trachea; (2) it is far

safer, from the simple anatomy of the parts ; (3) it is more quickly performed ; and (4) diseases which necessitate the operation in the adult have little tendency to spread downwards. It should be used, as a rule, in the adult male ; it is best in cases of foreign bodies impacted in the larynx, limited chronic disease, as syphilitic ulceration, acute or chronic œdema glottidis, tumours of the larynx, spasm of the muscles of the larynx from reflex irritation, as in cases of aortic aneurism. But in cases of foreign bodies in the trachea, bronchi, or pharynx, and as a preliminary to other operations about the head and face, where there is danger of blood passing down the trachea, then tracheotomy should be performed.

Œdema Glottidis.—Œdematous infiltration about the larynx may occur in simple acute laryngitis in the adult, but is very often erysipelatous in character, and is chiefly confined to the sub-mucous areolar tissue round the epiglottis, aryteno-epiglottidean folds, and arytenoid cartilages, ventricle and false cords. In these situations the sub-mucous tissue is very abundant and loose and freely movable, and readily becomes infiltrated and distended with serous effusion—so much so, as almost to occlude the rima glottidis. But this effusion and distension never extends below the true vocal cords, being limited at this point by the direct adhesion of the mucous membrane to the fibrous tissue forming the cords, without the intervention of any sub-mucous coat. The swollen folds overlap the chink of the glottis and cause in the first instance difficulty of *inspiration*, which is prolonged and stridulous, but after a time expiration is affected as well.

INTUBATION OF THE LARYNX.

For the modern form of this operation we are indebted to Dr J. O'DWYER, of New York. It is intended to take the place of tracheotomy, in suitable cases, more especially in the case of children suffering from croup or diphtheria ; it is a bloodless operation, and for this reason alone is likely to be preferred by the patient's parents or friends. **Instruments**—(1) A gag ; (2) an introducer ; (3) an extractor ; and (4) five tubes of different sizes. The tubes vary in length and size ; at the upper end of each tube is a diamond-shaped head with rounded angles, which rests upon the ventricular bands and prevents the tube from slipping into the

trachea. The anterior aspect of the head is bevelled off where it rests against the base of the epiglottis, and at its anterior part is a small eye, through which a double thread is passed. Below the neck is a fusiform enlargement, to make the tube self-retaining. Each tube is fitted with a jointed obturator, in the upper end of which is an opening to receive the introducer. The stem of the introducer is fitted with a sliding tube, which may be pushed forwards by a thumb-piece to release the obturator from the laryngeal tube when the latter is in position in the glottis. The extractor is constructed on the principle of a dilator. When used, the closed blades are passed into the end of the laryngeal tube; a lever on the handle is then pressed down to open the blades, which impinge against the inner aspect of the tube, and hold it firmly so that it may be withdrawn.

The Operation.—A suitable tube should be threaded with silk or linen thread, making a loop about sixteen inches in length. The obturator should then be screwed upon the introducer and the tube attached; the instrument is then ready for use, and should be placed upon a table within easy reach. The child is wrapped in a shawl and held upright in the nurse's lap, with its head resting against her left shoulder; an assistant stands behind, to hold the gag and steady the child's head. The gag is inserted on the left side. The Surgeon then passes his left index finger over the tongue, behind the epiglottis, and feels the arytenoid cartilages; then the introducer, with the tube attached, is passed under the forefinger and directed into the larynx, and, when through the glottis, is held by the index finger while the obturator is disengaged. The thread attached to the tube is allowed to remain till the child has cleared the trachea and got over the dyspnoea caused by the introduction; the finger is then once more placed upon the head of the tube, the thread divided and withdrawn. The object of the thread is to enable the tube to be withdrawn, should it have been passed into the pharynx. No anæsthetic is used, nor does the child complain of pain. Should any difficulty be experienced in the first attempt, the apparatus should be withdrawn to give the child air. That the tube has entered the larynx will be indicated by violent coughing and easy respiration. The tube should be removed probably from the fourth

to the sixth day, in order to avoid the risks of undue pressure. In extracting the tube, the child is placed in the same position as for its introduction; try, first gently without an anæsthetic, but should you fail, then an anæsthetic should be given.

The **advantages** of the operation are, its ease of performance (to the expert), the absence of shock and hæmorrhage, and the fact that one can more readily gain the consent of the parents for the operation. The greatest difficulty, as well as danger, is the administration of food: the head of the tube interferes with the movement of the epiglottis, and the child is unable to swallow fluids without coughing, and, in consequence, suffers very much from thirst. The danger from pneumonia is very great, as solid and fluid food finds its way into the trachea. This objection has, however, to a certain extent been overcome by the use of an artificial epiglottis, whereby it is possible for patients, if held in the supine position, with the head completely thrown back over the nurse's knee, to take an abundance of food, both liquid and solid.

The **dangers** of the operation are:—(1) The tube may be coughed up, and before skilled assistance arrives the child may die. (2) The tube may slip into the trachea. (3) The tube may be plugged with membrane, and asphyxiate the child. (4) The membrane may be pushed down before the tube, and give rise to intense dyspnoea, or even asphyxia. (5) The great risk of the entry of food into the trachea, and subsequent pneumonia.

The operation is **recommended** for—(1) Diphtheria; (2) croup; (3) œdema glottidis; and (4) in chronic stenosis of the larynx.

THE LARYNX.

The cartilages of the larynx are nine in number—three single and three paired. The **single cartilages** are—(1) The shield-like *thyroid*, consisting of two lateral wings, and an angle in front, which is very prominent at the upper part, this part being known as Adam's apple, or the *pomum Adami*. (2) The signet-ring-like *cricoid*, below the thyroid, the deepest part being behind; it is thicker and stronger than either the thyroid cartilage or the rings of the trachea, and for this reason it forms a very useful landmark in the neck. It is about on a level with the carotid tubercle of

the sixth cervical vertebra. (3) The *epiglottis*, like an obovate leaf in shape, placed behind the tongue, and in front of the superior opening of the larynx; during respiration it is vertical, and curved slightly forwards over the base of the tongue; but during deglutition it is carried or pushed downwards and backwards, so as to close the upper opening of the larynx. It is attached to the thyroid cartilage below, by the *thyro-epiglottic ligament*; to the hyoid bone in front, by the *hyo-epiglottic ligament*; and at the upper part to the tongue, by the median and two lateral *glosso-epiglottidean ligaments*; to its sides the aryteno-epiglottidean folds are attached. The **paired cartilages** are—(1) The two *arytenoids*, perched upon the upper border of the cricoid at its posterior aspect; they are pyramidal in form, and the anterior angle, at its base, gives attachment to the true vocal cords. (2) The *Cornicula laryngis* (cartilages of SANTORINI) are perched upon the apices of the arytenoids, and serve for the attachment of the posterior end of the aryteno-epiglottidean folds. (3) The *cuneiform cartilages* (cartilages of WRISBERG) are placed, one on each side, in the aryteno-epiglottidean folds.

The True Vocal Cords.—The true vocal cords are two bands of yellow elastic tissue, attached in front to the middle of the receding angle between the wings of the thyroid cartilage, and behind to the anterior angle of the base of the arytenoid cartilages; their lower border is continuous with the thin lateral parts of the crico-thyroid membrane. They are called *true*, as they are concerned in the production of sound; they are further known as the *inferior thyro-arytenoid ligaments*. The mucous membrane covering the true cords is very thin and closely adherent, as there is no submucous tissue, and it is destitute both of mucous glands and ciliated epithelium.

The False Cords, or the *superior thyro-arytenoid ligaments*, are simply two folds of mucous membrane with a little fibrous tissue between. Between the false cords above and the true below is situated the **ventricle of the larynx**; this leads to the *laryngeal pouch*, which in the human race is very small, but in some of the lower animals it is very large—*e.g.*, some kinds of monkeys, and the various members of the group *Felis Domesticus vel Catus*, and to this is due, no doubt, the hideous noises produced by the latter

animals in their nocturnal revels. Small foreign bodies, such as peas or pills or small fruit stones, may pass the "wrong way" and lodge in the ventricles, and quickly cause death from reflex spasm of the vocal cords; the ventricles are supplied by the superior laryngeal. The **length** of the cords in the adult male is about five-eighths of an inch (HOLDEN); in females and boys they are shorter than in the adult male. The greater the length of the cords, other things being equal, the deeper the voice.

The Rima Glottidis is the opening between the true vocal cords in front, and the bases of the arytenoid cartilages behind; it consists therefore of two parts—(1) The vocal part in front, between the cords; and (2) the respiratory part behind, between the cartilages. It is the narrowest part of the larynx, and in the male it measures rather less than an inch in length, and is about a third to half-an-inch in breadth when dilated; in the female it is less by two or three lines. During **quiet breathing** the opening represents a narrow isosceles triangle with the base behind, the sides, at the posterior part, being slightly bent inwards at an obtuse angle. In inhaling a **very deep breath**, they are separated to the widest possible extent, and represent a wide, almost pentagonal, opening. During the **emission of a high note**, the opposite cords and cartilages are almost in contact, leaving a narrow parallel slit between them.

The intrinsic Muscles of the Larynx.—(1) **Crico-arytenoideus posticus**—Each muscle *arises* from the posterior surface of the cricoid cartilage, passes upwards and outwards, and is *inserted* into the posterior external tubercle of the arytenoid. (2) **Crico-arytenoideus lateralis**—Each muscle *arises* from the upper border of the lateral part of the cricoid cartilage, passes upwards and backwards, and is *inserted* into the posterior tubercle of the arytenoid cartilage. (3) **Arytenoideus**—A transverse band of muscular fibres passing from the posterior surface of one arytenoid cartilage to the same part of the other. (4) **Crico-thyroid**—Each muscle *arises* from the side of the cricoid cartilage, and is *inserted* into the lower border of the thyroid, including the lesser cornu. (5) **Thyro-arytenoideus**—*Arises* from the angle between the wings of the thyroid cartilage, and is *inserted* into the front part of the base of the arytenoid cartilage; they lie parallel with and to

the outer side of the true vocal cords. All the muscles, except the arytenoideus, are paired.

The Joints of the Larynx.—(1) **The Crico-thyroid Joint**—Between the inferior cornua of the thyroid cartilage, and the lower and posterior part of the side of the cricoid cartilage. The movements that stretch or relax the vocal cords take place at this articulation, *i.e.*, the movements that govern the *pitch* of notes; the axis of the joint is transverse, and the thyroid cartilage moves up and down like the handle of a bucket: the arytenoid cartilages may also be tilted backwards at the same time. (2) **The Crico-arytenoid Joints**—Between the arytenoid cartilages and the upper part of the cricoid behind; the movements that govern the width of the rima glottidis take place at this articulation. The axes of these joints are vertical, the movements being chiefly rotatory.

The Movements of the Larynx:—

1. At the Crico-thyroid Joint—

Crico-thyroids render the true vocal cords tense.

Thyro-arytenoids relax the true vocal cords.

2. At the Crico-arytenoid Joint—

The posterior crico-arytenoids	{	widen the rima glottidis (the <i>abductors</i>).
The lateral crico-arytenoids		{
The arytenoideus		

The Arteries of the Larynx.—The laryngeal branches of the superior and inferior thyroids.

The Nerves of the Larynx.—The superior and the inferior, or recurrent, laryngeal branches of the vagi, with twigs from the sympathetic. The superior supplies the mucous membrane of the larynx with sensation, the crico-thyroid muscles, and half of the arytenoideus. If this nerve be irritated, as when a crumb of bread goes the wrong way, two events take place—(a) An inhibition of inspiration, and (b) an exciting of the expiratory centre—a cough; this is important, as the first prevents it being drawn in further, and the cough forces it out. If the trunk of the nerve be pressed on—as by a carotid aneurism high up, enlarged glands, or enlarged thyroid,—we have the peculiar brassy cough, but without expectoration. It should be noted

also, that irritation of this nerve will cause *reflex* spasm of the glottis and death from asphyxia—*e.g.*, a foreign body in one of the ventricles. The **inferior**, or **recurrent**, branch is principally motor, and supplies the intrinsic muscles not supplied by the superior. Pressure upon the trunk of this nerve first causes *spasm* of the muscles of the larynx, due to irritation of the nerve—later, *paralysis*, from destruction of the nerve, or from the intense pressure. The *superior laryngeals* lie behind the internal carotid artery; the *right recurrent laryngeal* hooks round the first part of the subclavian, lying on the apex of the pleura and lung, and farther up, lies behind the common carotid and the inferior thyroid arteries; the *left recurrent laryngeal* hooks round the arch of the aorta, and then, like the right, ascends by the side of the trachea in the groove between it and the œsophagus. Subclavian, aortic, or carotid aneurism, and malignant disease of the walls of the œsophagus, therefore, may press on and involve the recurrent nerves, and may cause death from spasm of the glottis, as well as by direct pressure on the trachea. The *left* nerve is more frequently paralysed than the right, probably from its longer course, and its relation to the arch of the aorta.

With the Laryngoscope the following structures can be seen:—The base of the tongue, the upper surface of the epiglottis with its lip and cushion, the glosso-epiglottidean folds or ligaments, the arytenoid cartilages, the true and the false vocal cords, the ventricles of the larynx, the aryteno-epiglottidean folds on each side, with two rounded elevations, corresponding to the cartilages of WRISBERG and SANTORINI; and sometimes, in deep inspiration, one may even see the rings and bifurcation of the trachea.

Results of Paralysis.—The **superior laryngeal**: this causes anæsthesia of the larynx and epiglottis, so that particles of food can readily enter the larynx; the vocal cords cannot be made tense, so that the voice is hoarse and deep, and the cords may be seen swinging loose. The paralysis may be caused by the pressure of tumours and aneurisms, but is usually a sequel to diphtheria, or a symptom of bulbar paralysis.

The **inferior or recurrent laryngeal** may also be paralysed by the pressure of tumours in the posterior mediastinum and

aneurisms; or the paralysis may be due to degenerative changes of the large ganglionic nerve cells in the medulla and pons—*e.g.*, in glosso-labio-pharyngo-laryngeal paralysis (or, more shortly, *Bulbar paralysis*). Both nerves are liable to be affected in central disease, and also occasionally in some forms of bronchocele or goitre, enlarged bronchial or cervical glands, from lymphadenoma. or scrofulous affections, and in cancer of the upper part of the œsophagus, though in this latter condition one only may be affected; the right nerve alone is often involved in the inflammatory and cicatricial changes consequent on phthisis of the apex of the right lung. When both nerves are paralysed, the cords are fixed and immobile, in the "*cadaveric position*," very like what is found in ordinary quiet breathing, not so close as in phonation, nor so open as in deep inspiration.

Bilateral Paralysis of the Adductors, or the muscles that close the glottis, is sometimes found in hysteria and debility, and is marked by complete aphonia, and the cords remain in the position of inspiration.

Unilateral Paralysis of the Adductors may result from chronic poisoning by lead and arsenic, or from diphtheria, also from disease of the nerves or nerve centres; aneurism of the arch of the aorta may cause paralysis of the left adductor; aneurism of the right subclavian or carotid, paralysis of the right adductor; but in these cases it often affects the abductor as well. There is aphonia or dysphonia, and the character of the cough, sneeze, and laugh are greatly altered in tone.

The laryngeal nerves may be paralysed at their origin, or from injury to the nerve trunks. Paralysis at their **origin** is seen in multiple sclerosis and bulbar paralysis, and usually affects both sides. **Peripheral** paralysis may occur near the roots of the spinal accessory and vagus, or attack the vagus after it has been joined by the spinal accessory, or the recurrent nerve may alone be affected; such peripheral paralysees are usually unilateral, and are caused by such conditions as aneurism of the arch of the aorta, mediastinal tumours, usually affecting the left nerve; aneurism of the innominate and right subclavian, usually affecting the right nerve; while thyroid tumours, or goitre, and cancer of the œsophagus may affect one or both.

Paralysis of one Recurrent Nerve.—The paralysed cord lies in the cadaveric position, the healthy cord possesses its full range of movement, and on phonation it crosses the middle line, so that the arytenoids are crossed and the glottis assumes an oblique position; the edge of the paralysed cord is slightly excavated. The healthy cord, therefore, accommodates itself to its paralysed fellow, so that the patient can still speak, though his voice is altered, being weak, and easily merges into the falsetto if the pitch of the voice be raised.

Paralysis of the Abductors or Glottis Openers (the posterior crico-arytenoids).—When both are affected the vocal cords lie close together in the middle line. It is indicated by pure inspiratory dyspnoea with stridor, associated with an almost normal voice. It is a very dangerous condition, as the approximated cords become still further approximated in inspiration, forming a kind of valve like the two sides of a reversed V, giving rise to intense inspiratory dyspnoea; on phonation the parts assume their normal condition. When this condition becomes marked, it will be necessary to perform tracheotomy. When one side is affected, the affected cord lies in the middle line, but respiration is free (unless combined with direct pressure), and there is only dyspnoea and stridor on exertion, as the opening in the glottis is sufficient for ordinary breathing. The abductors are apt to be paralysed from pressure on the recurrent laryngeal, as from aortic or innominate aneurism.

Bilateral Paralysis of the Abductors (*posterior crico-arytenoids*) may be caused by central disease, or affections implicating both vagi or both recurrent laryngeal nerves, as bronchocele, enlarged bronchial or cervical glands from lymphadenoma or scrofula, and cancer of the œsophagus.

Unilateral paralysis may be due to the same causes, but is more frequently due to peripheral affections, and not so often to central. The usual causes are—Aneurism of the arch of the aorta, cancerous or glandular tumours of the mediastinum (*superior* or *posterior*), affecting especially the left nerve; cancer of the œsophagus, enlarged strumous glands, and tumours of one side of the trachea, often affect one nerve, usually the left, but sometimes the right.

Paralysis of the Arytenoideus.—In phonation, the cords act normally, but the posterior third gapes, forming a little triangle,

as the arytenoid cartilages are not approximated; the air escapes through this opening and the voice is hoarse.

Paralysis of the Thyro-arytenoids.—During phonation, the free margins of the cords are excavated, they seem narrow and blurred; the glottis assumes the shape of a narrow oval. One or both cords may be affected.

The most common **Simple Tumours** of the larynx are papillomata and fibromata; they usually spring from the anterior parts of the vocal cords.

Malignant Disease is practically always cancerous in nature, very usually epithelioma; if it begins in the larynx, it usually starts over the *pharyngeal aspect of the arytenoid cartilages*; it may also spread from or to the upper part of the œsophagus.

The commonest **Ulcerations** are—Tertiary syphilitic, tubercular (*laryngeal phthisis*), and epitheliomatous. The **Syphilitic** may arise from superficial ulceration, softening of a gumma, or from perichondritis; it usually attacks the base of the epiglottis first, and spreads round the aryteno-epiglottidean folds. **Tubercular Disease** usually begins in the inter-arytenoid fold and the laryngeal surfaces of the arytenoid cartilages; the cartilages appear as two large, pale, pyriform swellings, the broad ends of which point upwards and outwards. It then spreads along and destroys the *true vocal cords*; further, the cartilages of SANTORINI and WRISBERG are lost, and the inter-arytenoid notch can no longer be distinguished.

EXCISION OF THE LARYNX.

The position of the patient and operator are the same as in tracheotomy. The following are the **chief steps** of the operation:—

1. Make a vertical median incision from the hyoid bone to the second ring of the trachea, cut through the deep fascia and separate the structures from the front and sides of the trachea, but do not interfere with the isthmus of the thyroid body, though the lateral lobes will have to be pushed aside.

2. Secure all bleeding vessels, both arteries and veins, principally the superior thyroid vessels and middle thyroid veins.

3. Draw forwards the trachea with a sharp hook and cut it across, taking care not to injure the œsophagus which lies just behind it.

4. An accurately fitting vulcanite syphon tube is now to be inserted into the upper end of the divided trachea, through which the patient may breathe, and which will at the same time exclude all blood from the trachea.

5. Lastly, separate the larynx from its posterior and upper attachments, and in dissecting out the cricoid keep the edge of the knife against it so as to avoid injuring the gullet.

When the surfaces have healed and the gap in the throat partly contracted, GUSSENHAUER'S artificial larynx, or the modification of it introduced by the late Dr FOULIS, of Glasgow, may be used.

Chief Structures divided—(1) The skin, superficial fascia, platysma, and deep fascia. (2) The sterno-thyroid, thyro-hyoid, inferior constrictor, stylo-pharyngeus, and palato-pharyngeus; the sterno-hyoid and the omo-hyoid may be pushed aside. (3) The anterior jugular vein, superior thyroid vessels and their branches, probably facial and lingual plexus of veins in this region, and middle and thyroid vein. (4) *Nerves*—Twigs of facial and superficial cervical, and superior and inferior laryngeals. (5) Trachea. (6) The thyro-hyoid ligaments, the hyo-epiglottic ligament, and the glosso-epiglottidean folds of mucous membrane.

CUT THROAT.

This may be—(1) **Above the hyoid bone**, when probably the following structures will be divided:—Skin and superficial fascia, radicles of anterior jugular veins, deep fascia, anterior bellies of the digastric muscles, mylo-hyoids, genio-hyoids, genio-hyoglossi, and probably right through into the floor of the mouth, implicating the tongue. Lingual artery, branches of the facial vessels, hypoglossal nerve, lingual nerve, and submaxillary gland. In this case the patient is unable to swallow at all. (2) **Below the hyoid bone**—The integumentary structures, anterior jugular veins, facial and superior thyroid veins, sterno-thyroid, thyro-hyoid, and omo-hyoid muscles, thyro-hyoid membrane, inferior constrictor, internal branch of superior laryngeal nerve, superior laryngeal artery, and probably also the superior thyroid and lingual arteries too. This cut may divide the epiglottis and open into the pharynx; there is considerable difficulty in swallowing, and great risk of *oedema glottidis*. (3) **Below the box of the larynx**, a rare form—The integuments,

anterior jugular veins, the sterno-hyoids, sterno-thyroids, omo-hyoids, possibly the sterno-mastoids, thyroid gland, superior and inferior thyroid arteries, the thyroid veins, especially the inferior, recurrent laryngeal nerves, trachea, and œsophagus, and the pre-vertebral muscles. In most cases the head is thrown so well back that the gash may extend right down to the vertebræ without injuring the carotid arteries, and therefore without causing immediate death; the lower down the cut is made, the more likely are these vessels to be opened.

The dangers are—(1) Great and fatal hæmorrhage at once from a large artery, or more slowly from the venous plexuses; (2) less rapid death by being gradually choked by the blood inhaled into the windpipe; (3) later, septic pneumonia from the entrance of blood into the bronchi and pulmonary vesicles; (4) bronchitis from the entrance of cold air; and (5) asphyxia from sudden œdema glottidis. When a large vessel, like the carotid artery, is divided, death is sudden, and the weapon usually falls from the hand, on account of the sudden loss of blood causing syncope and muscular relaxation for the time being. In cases, however, where no large vessel is divided, death is more slowly produced, being usually caused by asphyxia, and after death the weapon will generally be found firmly grasped in the hand. The risk of œdema glottidis is so serious that it is probably better for the patient to at once perform tracheotomy, then stitch up the gash in the throat, and treat it as an ordinary wound. Suicidal wounds are usually oblique from left to right, and from above downwards—unless the person be left-handed—and are deeper on the left than on the right side.

OPERATIONS ON THE ŒSOPHAGUS.

Relations in the Neck.—It is about nine inches in length, and extends from the lower border of the cricoid cartilage, or the sixth cervical vertebra, to the stomach—about the level of the ninth dorsal vertebra. In **front** is the trachea and the thyroid gland; the œsophagus projects a little to the *left* of the trachea in the neck; **behind**, it rests against the vertebræ, following the curves of the column, and also rests on the longus colli muscle; on **each side** are the common carotid arteries, the thyroid gland,

the recurrent laryngeal nerves, and inferior laryngeal arteries. In the lower cervical and upper dorsal region the thoracic duct ascends obliquely between it and the bodies of the dorsal vertebræ, from right to left. The narrowest parts of the tube are (*a*) at its commencement; (*b*) next, where it passes through the diaphragm; and (*c*) where it is crossed by the left bronchus.

Relations in the Thorax.—In **front**—the trachea, the arch of the aorta, left carotid, left subclavian, left bronchus, and the posterior surface of the pericardium; **behind**, the vertebral column, longus colli muscle, the intercostal vessels, and at the lower part, the aorta; **laterally**, the pleuræ, the vena azygos major on the right, and the descending aorta on the left. The *right vagus* passes down in front of the œsophagus, and the *left* behind it. Foreign bodies impacted in the gullet, especially if they have sharp corners, are very apt to set up ulceration and to penetrate neighbouring parts, such as the aorta—leading to sudden and fatal hæmorrhage. Cancer of the gullet, on the other hand, is very apt to ulcerate through into the trachea or bronchi; but it may involve any of the structures surrounding that tube—as the pleuræ, pericardium, subclavian, carotid, and thoracic duct. It is not a straight tube, but has three curves—(1) That of the vertebral column, (2) in the neck to the left side, and (3) in the thorax, back again to the middle line and then to the left, and forwards to its opening in the diaphragm. In the thorax, the œsophagus lies between the two pleural sacs—partially touching both, but being in special contact with the right bag.

The œsophagus may be **obstructed**, either from actual changes in its walls, foreign bodies in its interior, or from pressure of the neighbouring structures. Obstruction from changes in its walls may be—(1) **Merely spasmodic**, usually in nervous women, and recognised by the fact that the dysphagia is not constant. (2) **Traumatic**, due to organic changes in the submucous tissue, as cicatrisation after injuries—such as simple and specific ulceration, swallowing acid or caustic fluids, etc. (3) **Malignant**, usually epitheliomatous in nature, and situated either—first, at its upper end; second, at its lower end; or third, where it is crossed by the left bronchus. At these points, as already stated, the tube is narrowed, and probably therefore the irritation is greater than

it is elsewhere. (4) A special form, met with in **drunkards**, is due probably to cirrhosis of the gullet (DUNCAN). The above forms of obstruction must be carefully distinguished from that produced by neighbouring parts, as retro-pharyngeal or retro-œsophageal abscess, aortic aneurism, enlarged mediastinal glands, or malignant disease of the bodies of the vertebræ; the most common by far is an aortic aneurism pressing upon the trachea, and this therefore must always be first looked for and excluded before attempting to pass bougies.

To pass the Bougie.—Put the left index finger to the back of the tongue, so that it touches the epiglottis, and pass the point of the bougie beyond this till it touches the posterior wall of the pharynx, with an inclination downwards; now remove the finger, ask the patient to swallow, and gently push it down; always be cool and gentle, and should it stick, remove it and try again. The head should not be thrown too much backwards, but should be put into the position one naturally takes up while vomiting.

Treatment of Malignant Stricture of the Œsophagus.—(1) Keeping the patient alive as long as possible by feeding, but without using any other means; the patient is fed with soft food or pap, as long as possible by the mouth, and when this is impossible, by the rectum—being slowly starved to death. (2) The occasional passage of a bougie; but this, although it may assist swallowing, irritates the growth and makes it grow faster, and thus shortens life. (3) Insertion of a hollow metal tube through the stricture; this is open to the same objections as the bougie, and is even worse, for the tube may drop into the stomach, and necessitate gastrotomy for its removal. (4) Gastrostomy, which is probably the best operation in most cases, if done sufficiently early.

The Lymphatics of the lower two thirds of the œsophagus end in the posterior mediastinal glands; those of the upper part, in the deep cervical, lying along the carotid sheath. These regions must therefore be examined in cases of supposed malignant disease.

The principal operations performed on the œsophagus are—

1. **Œsophagotomy**, opening the œsophagus for the purpose of removing a foreign body—a temporary opening.

2. **Œsophagostomy**, opening the œsophagus in order to make a mouth there to feed the patient—a permanent opening. The position of the patient is the same as for ligature of the common carotid.

Instruments required.—Scalpels, directors, retractors (broad copper), blunt hooks, catch forceps, dissecting forceps, a bulbous-headed bougie, sponges, needles, ligature, etc.

Make an **incision** about four inches in length along the anterior border of the *left* sterno-mastoid (as the œsophagus in the neck lies to the left of the middle line), beginning about the level of the cricoid cartilage. The incision is almost the same as that necessary in ligature of the left common carotid, low down, but a little nearer the middle line. By making the incision a little higher, the operation of **Pharyngotomy** may be performed. Divide the skin, platysma, and fascia, and draw aside the sterno-mastoid, or divide its sternal head. Carefully dissect down, with the handle of the knife, or fingers, between the carotid sheath on the outer side, and the trachea and larynx on the inner side. Draw the sterno-hyoid and sterno-thyroid muscles towards the middle line, the thyroid body upwards, the carotid sheath with its contents and the sterno-mastoid outwards, and if the omo-hyoid be in the way, divide it. Great care is now necessary to avoid wounding the thyroid arteries—especially the inferior—passing to the lower angle of the thyroid body behind the carotid sheath; also to avoid injuring the left recurrent laryngeal nerve, which lies between the œsophagus and trachea. The œsophagus being exposed, pass a bulbous bougie, or probang, through the mouth into it, and cause its walls to project; this is made to serve as a guide for the necessary incision; otherwise the air passages might be cut into. The operation of œsophagostomy has been anything but a successful one; there is a great risk of setting up deep cellulitis in the tissues of the neck; but apart from that, the patient very often dies. It is better in almost all cases, I believe, to perform the operation of gastrostomy early.

After Treatment.—The patient must be fed through a narrow tube (No. 10 catheter) passed through the mouth, past the wound in the œsophagus, for a few days, till granulations form on the sides of the wound, and close up the inter-muscular cellular planes. No sutures are required for the wound in the œsophagus, or for the external wound either, though after the granulations have formed it may be stitched up if thought necessary. The **danger** of this operation is the risk of setting up cellulitis in the extensive

inter-muscular cellular planes of the neck. As the wound in the œsophagus is parallel with its long axis, there is no risk of subsequent stricture. If a permanent opening is desired, the edges of the opening in the œsophagus must be stitched to the lips of the skin incision.

THE PHARYNX.

This is a membrano-muscular sac, about four and a half inches in length, extending from the under surface of the basi-sphenoid portion of the skull to the cricoid cartilage. **Behind**, it is connected by loose areolar tissue, with the vertebræ and the longus colli, and anterior recti muscles. It is connected **above** to the base of the skull, being attached to the basi-sphenoid, the petrous part of the temporal bone, internal pterygoid plate, the pterygo-maxillary ligament, the lower jaw, posterior nares, mouth, hyoid bone, larynx, and styloid process. In relation to its **outer** surface, we find the common and internal carotid arteries, the internal jugular veins, the glosso-pharyngeal, the spinal accessory, the vagus, and the ninth cranial nerves, and the sympathetic trunks. It has **seven openings**—the two posterior nares (*choanæ narium*) the two Eustachian tubes, the mouth, larynx, and œsophagus.

In aneurism of the internal carotid one can readily understand how it tends to bulge into this cavity, pressing in the thin unresisting pharyngeal wall rather than to make its way to the skin surface through the dense cervical fascia, sterno-mastoid, digastric, stylo-hyoid and stylo-pharyngeus muscles, all of which structures resist its passage in that direction.

Pharyngeal Abscesses are lateral or posterior—(1) The **lateral** are *circumscribed* abscesses, usually just behind the tonsil; they project inwards, and may simulate an aneurism or malignant disease of the tonsil. There is deep-seated pain in the neck, and pain behind the ear and shooting up the side of the head, along the auriculo-temporal nerve; they are said to occur chiefly in rheumatic patients. The pus may make its way out through the gap in the cervical fascia, and present in the parotid region, or at the posterior border of the sterno-mastoid; if it does so, then it should be opened at these points by HILTON'S method; if it is opened from the inside, be careful to turn the edge of the knife inwards.

(2) **Posterior or retro-pharyngeal abscess.**—These abscesses are found at the back of the pharynx, bulging forwards; they are usually due to cervical caries; it may also bulge towards the side of the neck. If possible, it should be opened at the posterior edge of the upper part of the sterno-mastoid by "HILTON'S method;" if not, it may be aspirated through the mouth. Were it opened in the mouth by a bistoury in the usual way, the sudden gush of pus might choke the patient. (3) There is another possible source of a retro-pharyngeal abscess, viz., the lymph glands in the submucous tissue in front of the vertebræ, towards the upper part of the pharynx. Some of the lymphatics from the nose empty themselves into these glands, which may occasionally suppurate; but in this case there is an absence of symptoms pointing to disease of the cervical vertebræ. The abscess, too, is more likely to be circumscribed, though the loose submucous tissue favours the spread of pus round the pharyngeal wall.

Foreign bodies are apt to stick in the pharynx, and may cause sudden death from lying over the upper opening of the larynx; this is the usual cause of sudden death from "choking" during eating. It is important to remember that in these cases the foreign body is almost always within reach of the finger, and the treatment therefore is at once to put the finger down and hook it up.

Parotid Duct (STENSON'S).—Its course is indicated by a line drawn from the lower margin of the concha of the ear to midway between the red margin of the lip and the ala of the nose; it is about one finger's-breadth below the zygoma. Above it is the transverse facial artery, and below it are some branches of the facial nerve; its length is about two and a half inches, and it begins about the middle of the masseter. It perforates the cheek obliquely, or almost at right angles to its former course, opposite the crown of the second molar tooth of the upper jaw, perforating the buccinator muscle. It is necessary to remember its course, as it may be divided in wounds or operations about the face, and give rise to **salivary fistula**. The fistula is recognised by the great flow of a watery fluid during mastication, which is alkaline in reaction, and has the power of converting a solution of starch—first into dextrine and then into grape sugar, as shown by the chemical tests for these substances. Thus—

Iodine + starch = blue: Iodine + dextrine = red, which disappears on warming, and does not reappear on cooling: Cupric sulphate and caustic potash + grape sugar and heat = reddish yellow precipitate of cuprous oxide. The fluid should also give a blood-red colour on the addition of neutral ferric chloride—from the presence of potassium sulpho-cyanide. I have seen one case where the fistula opened just behind the ear. The principles of treatment are the same as in all fistulæ—to make it easy for the secretion to go the right way, by enlarging the opening into the mouth, when the abnormal opening will usually close of its own accord.

FIFTH NERVE.

Division of the Fifth Nerve on the Face.—The supra-orbital notch or foramen is situated about the junction of the inner with the middle third of the supra-orbital margin. From this point a perpendicular line, drawn with a slight inclination outwards, so as to cross the interval between the two bicuspid teeth, passes over the infra-orbital and mental foramina.

The supra-orbital is covered by the orbicularis palpebrarum; in exposing this nerve, care should be taken not to wound the palpebral ligament (a prolongation from the periosteum of the orbit) of the lid, as blood would then be extravasated into the orbit and under the conjunctiva, and the chances of suppuration greatly increased. The periosteum of the orbit, it will be remembered, splits into two layers at the margin of that cavity, one of which is continuous with the external periosteum of the skull, while the other forms the tarsal or palpebral ligament.

Operation.—The skin of the forehead is drawn upwards and the eyelid downwards, and a short curved incision, parallel with the eyebrow or along some natural wrinkle, the centre being opposite the supra-orbital notch or foramen. Tease through the fibres of the orbicularis with a director, when the nerve is exposed, lying against the pericranium, and may either be stretched with a blunt hook, or a part removed. It may be done “subcutaneously,” *i.e.*, without seeing the nerve, by making a very small incision over its course, inserting a blunt hook, and scraping it along the bone—hoping in this way to catch up the nerve.

The **infra-orbital** is covered by the levator labii superioris, and is about three-eighths of an inch below the margin of the orbit. It may also be stretched subcutaneously, in the same way as the supra-orbital; the better method, however, is by direct incision.

Operation.—The upper lip and cheek are drawn downwards and the lower lid upwards, and a short curved incision is made, with its centre opposite the foramen, and so arranged that, when healed, the cicatrix will fall into the natural lines of the face. The skin and the fascia, together with the levator labii superioris, are divided, exposing the nerve, which can then be stretched forcibly, or else an inch of it cut out altogether. It must be pulled well out, so as to rupture its *anterior dental branch*, as the teeth are the usual cause of the neuralgic pain. The nerve has also been divided **beyond the origin of the anterior dental branch**, by making an incision, parallel with, and just below the margin of, the orbit, cutting through the orbicularis and the levator labii superioris, and turning the latter muscle down, dividing the periosteum at the orbital margin, and pushing it up, with fat, eyeball, and all, so as to expose the bony floor. Tension is then made upon the nerve at the infra-orbital canal, and a strong tenotome is used to divide the nerve as it lies in the canal, and which is made to penetrate the antrum; when the nerve is divided it is easily drawn out of the canal, and by this means the anterior dental is ruptured. The part thus dragged out is then cut off. Unless strict antiseptic precautions be observed, this operation is apt to be followed by suppuration of the antrum and orbit.

It may also be divided in the **spheno-maxillary fissure**. Expose it at the infra-orbital foramen as before, and make a small puncture just below the outer commissure of the lids; after this pull upon the nerve by a pair of forceps, and introduce a blunt-pointed tenotome through the small incision, and put it backwards and downwards till its point is felt to be in the fissure, when it is made to shave along its maxillary border. As soon as it is divided the nerve will easily pull out of the canal. To expose the nerve in the **spheno-maxillary fossa**, a \neg -shaped incision is required, the vertical part extending from the outer margin of the orbit downwards to a point opposite the last molar tooth, and the horizontal part backwards to the root of the zygoma. The malar bone and

zygoma are then cut through, and the arch turned down along with the masseter muscle; the fatty tissue and the temporal muscle are then pushed forwards by a blunt instrument, and, if necessary, divided, or the coronoid process may be divided, and the temporal muscle thrown up as a whole, the posterior wall of the upper jaw found, which will guide to the fossa. The nerve is then hooked up, and as much as possible removed. The bleeding from the venus plexus in this situation, and from the branches of the internal maxillary artery, may be free; and the operation has been followed by stiffness of the lower jaw. It is also possible in this way to reach and destroy, or excise, MECKEL'S ganglion.

The **Mental Branch of the Inferior Dental** is found below the depressor anguli oris muscle, midway between the alveolus and the lower border of the jaw in the adult. It may either be stretched "subcutaneously" or by the direct method, in a manner similar to the preceding nerves, and should, if possible, be reached by an incision through the mucous membrane of the mouth.

The **Trunk of the Inferior Dental** may be exposed by making an incision over the ramus of the lower jaw, trephining over the point where it enters the dental canal, and then excising a portion of the nerve. It can also be reached by making an incision immediately in front of the masseter, displacing the fatty tissue and the buccinator muscle forwards, and then, by means of a blunt hook, the nerve may be caught and stretched or divided. The **objections** to this method are—(1) The great risk of dividing the branches of the facial nerve, and (2) one is very apt to open into the cavity of the mouth.

In **trephining the ramus**, remember that the nerve enters the canal on a level with the upper border of the molar teeth, at a point rather nearer the posterior than the anterior edge of the ramus. In this operation two important points should be kept in mind—(1) To make the external incision in such a way that the facial nerve will not be injured; either make it parallel with the nerve at the point where you wish to trephine, or else go below the level of the nerve and make a curved incision over the angle of the jaw, and turn up the masseter. In this way the branches of the facial nerve are lifted up with the flap. (2) The second important point is not to open into the cavity of the mouth, for then it will be

impossible to keep the wound aseptic. In making the incision, we must also avoid wounding STENSON'S duct. We may trephine—(1) So as to find the nerve before it enters the bone, or (2) so as to find it in the bone. It is probably better to take it just before or at its entrance into the bone, because at this point the lingual nerve may also be divided through the same opening. Both nerves in this situation lie on the internal pterygoid muscle, the lingual nerve being about half-an-inch anterior to the inferior dental. Between the cavity of the mouth and the nerves in question we have—(1) Part of the internal lateral ligament of the lower jaw, (2) the internal pterygoid muscle, (3) part of the superior constrictor of the pharynx, and (4) the mucous membrane of the mouth.

In using an incision parallel with the branches of the facial nerve, over the point where we wish to trephine, the following **Structures** will probably be **divided**—(1) The skin and the superficial and deep fascia, (2) some outlying lobules of the parotid gland or socia, (3) the facial vein or some of its large tributaries, (4) the masseter muscle, (5) the periosteum, and (6) bone. After having made the incision through the soft parts and the periosteum, this latter structure should be turned aside with the elevator; the trephine is then applied, and the circle of bone removed, the nerves hooked up, and as much as possible of their trunks excised. By the parallel incision the branches of the facial nerve, the transverse facial vessels, and the duct of the parotid gland will usually escape injury.

The Auriculo-Temporal Nerve may be reached as it crosses the root of the zygoma, and *behind* the temporal artery; expose the nerve by an incision parallel to its course, and stretch it, taking care of the temporal vessels.

Before, however, resorting to such extreme measures for the relief of neuralgia, etc., it is a good plan always to examine the mouth, and direct the patient to get rid of all rotten teeth, which are perhaps the most common cause of neuralgia.

Division of the Lingual Nerve ("Gustatory").—This being the nerve of common sensation to the anterior two thirds of the tongue, its division has been practised inside the mouth, with the view of relieving the pain of cancerous ulcers of that organ, and

diminishing the profuse salivation in cases where operation is out of the question. It is a branch of the third division of the fifth, and opposite the second molar tooth it is simply covered by the mucous membrane of the floor of the mouth.

1. **Hilton's Plan.**—This is to divide the nerve opposite the second molar tooth, where it can be raised by a blunt hook, seen, and divided; here it is only covered by the mucous membrane. But in cases where the disease has involved the floor of the mouth this plan is inapplicable, and, further, the guides to the spot in question are not quite definite.

2. **Mr Lucas** gags the patient and then passes a strong silk ligature through the tip of the tongue, and pulls it forwards, and to the opposite side to that on which he is to divide the nerve. In this way the nerve is seen standing out as a firm cord, extending from the angle of the jaw along the side of the tongue. A sharp hook is next passed beneath it, the mucous membrane divided over it, and the nerve then cut, stretched, or a portion removed, as the Surgeon may think fit.

3. **Moore's Plan.**—He divides the nerve further back than Mr HILTON, and takes as his guide the last molar tooth.

Guide.—A line drawn from the middle of the crown of the last molar tooth to the angle of the jaw. The junction of the upper with the middle third of this line indicates the point where it should be divided. It lies about half-an-inch from the tooth, between it and the anterior pillar of the fauces, parallel with, but behind and below the prominent alveolar ridge on the inner side of the body, and ascending ramus of the lower jaw. Enter the knife about three-quarters of an inch behind and below the last molar tooth, and cut down to the bone, and the nerve is certain to be divided. It is doubtful if mere *division* of a nerve will cure neuralgia, as the nerve usually unites again with great rapidity; it would probably be better, therefore, to remove an inch or so of the nerve, as it has been found that anything under an inch will almost certainly unite, so great is the growth from the central end of the divided nerve. The reason why the nerves unite so very readily and surely after division or excision for neuralgia, is because they are, as a rule, in bony canals, and the canal acts as guide to the central end, leading it to the proximal

end; hence, the central end, instead of forming a bulbous mass, unites with the proximal. The cause of neuralgia of the fifth nerve is very frequently bad teeth, but there are other causes besides the so-called "idiopathic." The nerves are enclosed in rigid canals lined with periosteum and are accompanied by venous and arterial plexuses; any slight swelling of the periosteum, therefore, may press on the nerve and give rise to pain. Vasomotor changes also, by dilating the arteries, may produce the same effect, as well as passive venous congestion. It is a curious fact how an aching tooth seems to grow better all at once when one sets out for the dentist's consulting room: the cause is probably due to contraction of the vessels, from the peculiar mental state stimulating the vaso-motor centre.

THE TONSILS.

The tonsils are glandular organs, consisting of much adenoid tissue and mucous glands. In the substance are a number of recesses (twelve to fifteen) from which numerous follicles branch out into the gland; the recesses open by small orifices on the surface. Around the follicles are a number of closed capsules of adenoid tissue, resembling the solitary glands of the intestines. The follicles and recesses contain a thick greyish secretion; when inflamed, plugs of thickened mucus and softened epithelium fill the openings on the surface, causing great foetor of breath, from the decomposing epithelium, and give rise to an appearance often called "diphtheria"—from the whitish-yellow patches plugging the recesses. It is extremely difficult to distinguish *follicular tonsillitis* from true diphtheria with certainty; if the redness and patches are also found upon the uvula, in all probability it is diphtheria, but if limited to the tonsils it is impossible to say with certainty. There can be little doubt but that unhealthy tonsils are a very frequent cause of tubercular disease of the glands of the neck, and even more widespread tubercular disease; it is a question also whether they are not the source of entrance into the blood of many of the organisms causing so-called idiopathic diseases, as acute necrosis, fevers, etc. Sewer gases seem to have a special tendency to affect chronically enlarged and inflamed tonsils, especially in cases where the gases gain admission to

sleeping rooms. The tonsils are situated between the anterior and the posterior pillars of the soft palate; on the *outer side* they rest against the superior constrictor, and just outside this again we find the ascending pharyngeal and the internal carotid arteries. On the surface, they correspond to the angle of the lower jaw. The tonsils are a long way from the mouths of the Eustachian tubes, and, even when they are enlarged, they could not cause deafness by pressing on these tubes; the deafness accompanying this condition is due to hypertrophy of the pharyngeal tonsils (“*adenoid vegetations*” of the naso-pharynx). When inflamed, the lymphatic glands at the angle of the jaw, just over the tonsil, enlarge, and hence give rise to the false impression that the enlarged *tonsils themselves* can be felt beneath the skin.

The **Arteries** of the tonsils come from *dorsalis linguæ*, facial in the neck (ascending palatine and tonsillar), and internal maxillary arteries (the descending palatine), and sometimes an aberrant large branch from the internal carotid, and which may cause serious hæmorrhage in excision of the gland. The **Nerves** are derived from the glosso-pharyngeal, and the second division of the fifth through MECKEL’S ganglion. In malignant disease there is intense pain shooting up the side of the head along the temporal and auriculo-temporal nerves which the patient thinks is ear-ache, and hence puts a plug of wool in his ear.

Lymphatics.—The lymphatics from the tonsil pass to the glands near the great horn of the hyoid bone and deep cervical set, also to the deep parotid, and through them to the group at the angle of the jaw. In cancerous tumours, therefore, these groups will enlarge.

Removal of the Tonsils.—In health the tonsils do not project beyond the level of the palatine arches. If they are much enlarged they interfere with respiration, causing defective development, attacks of fever, sore throat, and predispose to diphtheria, and should therefore be removed; this may be done by a probe-pointed bistoury, with plaster round its heel, so that the lip and tongue may not be cut (see Fig. 121). Seize the tonsil by a vulsellum, pass the knife *directly backwards* in the line of the second molar tooth, and cut downwards and inwards, and on no account turn the edge of the knife *outwards*, lest the internal carotid artery

or the ascending pharyngeal branch of the external carotid, be injured, there being nothing covering these vessels at this point except the pharyngeal aponeurosis and the superior constrictor of the pharynx. The adult should not require chloroform as the tonsils are not very sensitive, but children require it. The child is gagged and the tonsil removed either by the knife or guillotine, only be very careful that blood does not pass into the larynx.

The **knife** (Fig. 121) to use is a straight, probe-pointed bistoury, cutting to the point; it must be *very sharp*, so as not to necessitate *sawing* of the tonsil. The tonsil should not be "excised" when acutely inflamed—(1) Because it is more painful; (2) it may bleed pretty freely; (3) and most important, it is brittle, and crumbles away in the grip of the vulsellum. Leave it till it is chronic, when the tissue is sufficiently tough to hold by the vulsellum. Mr SPENCE directs that the tonsil should be cut *from below upwards and inwards*.

The recesses on the inner surface of the tonsil are shaped like Florence flasks; hence, the narrow necks are apt to become blocked up, and then the wide part below forms a very suitable receptacle for fermentative changes, and for the growth of septic and other organisms. Some believe that to this condition we must attribute the hypertrophied tonsils and the enlarged glands in the neck, and therefore propose that, instead of "excising" the tonsil, we should pass a blunt hook into the orifices and tear up the brittle tonsil substance, so as to destroy the narrow neck and secure

Fig. 121.
KNIFE FOR EXCISION
OF TONSIL.



The knife is a straight probe-pointed bistoury cutting to the point.

free drainage. This, to the patient, seems a less formidable operation, and could be best done when the tonsil is brittle—just after an acute attack of tonsillitis; the question, however, is still *sub judice*.

Abscess of the Tonsil.—To open an abscess of the tonsil, the bistoury must be passed directly backwards in the line of the second molar tooth, with the edge directed inwards and upwards; should the patient refuse to have it “opened,” he must be told of the risk—viz., that it may burst during the night, when he is asleep, and choke him. The abscess usually tends to point at the upper part, about the junction of the anterior palatine arch with the palate, or almost in the palate itself.

THE TEMPORO-MAXILLARY ARTICULATION.

This is described as an arthrodial, but it also partakes of the character of a hinge joint, and has in addition a rolling movement, resembling in these particulars the knee joint.

Ligaments.—(1) The **external lateral**, from the tubercle of the zygoma downwards and backwards to the outer surface and the posterior border of the neck of the lower jaw. (2) The **internal lateral**, from the spine of the sphenoid to the inner margin of the dental foramen; between this ligament and the jaw we find the internal maxillary artery, and the inferior dental vessels and nerves. (3) The **stylo-maxillary**, from the apex of the styloid process to the angle and posterior border of the ramus of the lower jaw; this ligament separates the parotid from the submaxillary gland. (4) The **capsular**, a thin, loose structure surrounding the joint. (5) The **inter-articular cartilage**, which consists of white fibro-cartilage, and is placed horizontally between the condyle and the glenoid cavity. It is connected by its circumference to the various ligaments surrounding the joint, and in front specially to the tendon of the external pterygoid muscle. There are usually two *synovial membranes*.

The **Nerves** of the joint are derived from the auriculo-temporal and the nerve to the masseter muscle. There are two sets of movements in this joint—(1) Side to side and forwards and backwards, which are accomplished by a horizontal, gliding movement of the fibro-cartilages and condyles upon the glenoid cavities. These

movements are to a great extent caused by the external pterygoid muscle, and the importance, therefore, of its attachment to both the bone and cartilage is evident; were it not so, "subluxation" or "internal derangement" would be much more frequent than it is. (2) Hinge-like movements, which take place between the condyle and the cartilage.

Movements.—The mouth is opened by the anterior belly of the digastric, mylo-hyoid and geno-hyoid muscles, and gravity. It is closed by the masseter, the anterior part of the temporal, and the internal pterygoid. The chin is protruded by the simultaneous action of the external pterygoids, and retracted by the posterior fibres of the temporal. The grinding movement is caused by the alternate action of the two external pterygoids.

The condition of the lower jaw at different periods of life is of considerable importance in medico-legal practice. **At birth**, the bone consists of two lateral halves, united by cartilage; the body is a mere shell containing the sockets of the milk teeth, and consists of the alveolar portion of the body only—the part *above* the oblique lines—and the angle is obtuse. Towards **puberty** the basilar part, or the part *below* the oblique line, has grown to a considerable extent, and the angle is less obtuse. In the **adult**, the two parts of the body—the alveolar and basilar—are fully developed, the mental foramen is midway between the upper and the lower borders, the ramus is almost vertical, and joins the body nearly at right angles. In **old age**, when the teeth fall out and their sockets are absorbed, the basilar part alone remains, and hence the most of the body is below the oblique line; the dental canal and the mental foramen are close to the upper edge of the body, the rami are oblique, the angle is obtuse, and the chin approaches the nose.

Dislocation of the Lower Jaw.—This is perhaps *the* most common *muscular* dislocation. It is usually caused by some sudden exertion on the part of the patient, or spasmodic action of the depressors of the jaw, as in gaping, fits of laughter, attempting to take too large a bite, etc. It may be—(1) unilateral or incomplete; (2) bilateral or complete, according as one or both of the condyles are displaced. When the mouth is opened the condyle, with the inter-articular fibro-cartilage, glides forward on to

the eminentia articularis; but if this be continued too far, and if, at the same time, the *external pterygoid* muscle contracts forcibly, the condyle slips forward into the zygomatic fossa. In this way a dislocation is produced. Considerable difficulty is sometimes experienced in reducing these dislocations; as to the exact cause of this there is some difference of opinion. NÉLATON believes that it is caused by the coronoid process locking against the malar bone, and in one case at least this has been shown to be possible; but Mr HEATH simply attributes it to excessive muscular action, the bone being pulled upwards by the temporal, internal pterygoid, and masseter muscles. Probably during the wide gape some of the sensory twigs of the fifth are squeezed, and the stimulus thus communicated to the nerve may reflexly cause contraction of the muscles that pull forward and depress the jaw. It is most likely to be the auriculo-temporal nerve that is irritated in the same way, for example, as in ear yawning. The capsular ligament is not ruptured, and reduction is, as a rule, easily accomplished by disengaging the condyle, by pressing down with the thumbs, guarded by a towel, in the mouth behind the last molar tooth, while at the same time the chin is pushed upwards and backwards by the fingers.

Fracture of the Lower Jaw.—It is caused by severe direct violence. The most common situation is near the canine tooth, on one or other side, as at this point the jaw is weakened by the deep fang of that tooth as well as the mental foramen; it is next most frequently fractured at the angle, and lastly close to the symphysis: occasionally the neck of the condyle, or the coronoid process may be broken. Very often the fracture is double, near the canine tooth on one side and at the angle on the other. The mucous membrane is nearly always lacerated, and the fracture is therefore compound; the mental branch of the fifth is very often injured, either by the fracture directly, or a week or two after, by the growth and ossification of the "callus;" this is indicated by an anæsthetic patch on the chin and lips. The teeth are generally displaced, or may be split and fall down between the broken surfaces; all split portions and fangs must be carefully removed before the bones are moulded into position. The fragments are usually displaced by the force that broke the bone. As regards muscular

action, at the angle the masseter and the internal pterygoid practically balance each other; when the fracture is near the canine tooth, the mylo-hyoid tends to pull the broken bone inwards; in a fracture on each side of the symphysis, the central portion would be pulled downwards and backwards by the mylo-hyoid, genio-hyoid, the genio-hyoglossus, and the other depressor muscles of the jaw. Great care must be exercised in the treatment of this form lest the tongue fall back, or be forced back by the splint or bandage, and choke the patient.

Treatment.—Mould the jaw into proper shape, and then keep the lower jaw fixed against the upper one by a four-tailed bandage; in this way the upper jaw acts as a splint. Some wire the teeth together, but this is apt to spoil them; others use a poroplastic or gutta percha splint, moulded to the jaw, embracing it in front and below; this is of doubtful utility, as the displacement is not outwards but towards the mouth. THOMAS drills and wires the broken fragments together. The patient will have to be fed through the gap behind the last molar tooth, or where other teeth have been lost, with *fluid* food; all talking must be interdicted.

The Four-tailed Bandage.—Take a cotton bandage, three inches wide and four to four-and-a-half feet in length (a little more than twice the circumference of the head), and fold it on itself at its middle; then make a slit large enough to admit the patient's chin—but *not in the centre* of the breadth, but in such a way that two inches may be on one side and one on the other. Lastly, make it four-tailed by splitting it lengthwise, in the same manner as the chin slit, to within two inches of the slit on each side; in this way there are two broad and two narrow tails.

To apply.—Insert the point of the patient's chin into the slit, in such a way that the broad part of the bandage is *underneath* the jaw, and take the two broad tails and bring them up and tie loosely over the vertex; then carry the narrow ends back to a point behind and below the occipital protuberance and tie them there; or, better, cross them there, lead them forwards to the forehead, and tie in front. Readjust and tighten the broad half of the bandage, and put in safety pins at the points where the bandages cross each other; this will prevent them slipping. This bandage may be used alone, or outside the moulded gutta percha splint.

“Subluxation” is probably caused by a want of harmony between the movements of the condyle and the fibro-cartilage, from some fault of the external pterygoid muscle; hence, the bone slips for a moment in front of the cartilage—which it can easily do as the capsule is so loose—where it is held fixed for a little, but can usually be put to rights by the patient himself, the reduction being accompanied by an audible snap. This corresponds to HEY’S “internal derangement” of the knee joint, and should be treated in a similar manner.

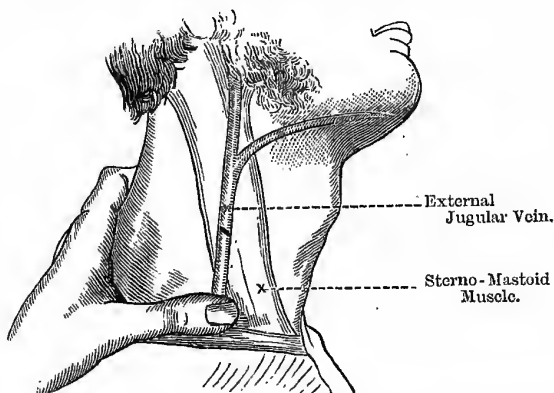
Bursæ in the Neck.—(1) There is one in front of the “*pomum Adami*”; (2) another between the thyroid cartilage and the posterior surface of the hyoid bone; (3) and one between the genio-hyoid and the genio-hyoglossus muscles. The third may not be present; either of the bursæ may occasionally be enlarged. The first is the one usually enlarged, and when it is so, it forms a tense rounded tumour, in front or at the side of the thyroid cartilage, and *moves with the larynx during deglutition*. Swellings that rise thus during deglutition are the bursal cysts above mentioned, swellings of the thyroid gland (*bronchocele* or *goître*), and cysts in connection with the thyroid. By this sign, among others, one can distinguish these swellings from aneurism of the carotid, sebaceous and dermoid cysts. The one between the muscles of the tongue, when enlarged, may simulate a ranula, only it projects chiefly into the neck, in front of the larynx, and not so much into the floor of the mouth, and is in the middle line; it also forms one of the varieties of “hydrocele of the neck.”

Venesection from External Jugular.—This may be useful in cases of croup in young children, apoplexy in adults, or in venous congestion of the head or chest. The course of the vein may be indicated by a line drawn from the angle of the jaw to the middle of the clavicle. The vein is crossed obliquely by the fibres of the platysma, their relative positions being represented very nearly by the letter X. To secure a good flow, the cut in the vein must be oblique, because if longitudinal the edges would not gape. But the external jugular must not be opened by a single oblique thrust at once, because the cut would then be parallel with the fibres of the platysma, which by their contraction would prevent the free exit of the blood, and might give rise to extravasation and

thrombus. It should be opened about the middle of the neck while it lies on the sterno-mastoid, because at this point it is most superficial and more firmly fixed. (1) Compress the vein at the lower part of the neck (*i.e.*, on the proximal side) with the thumb of the left hand to make it "rise," and also to prevent the entrance of air after the vessel is opened; some do this by means of a thick compress over the lower part of the vein, held in position by a bandage passed around the neck and under the opposite axilla instead of simply using the thumb (Fig. 122). (2) Make an incision *in the skin only*, obliquely to the course of the vein.

Fig. 122.

VENESECTION FROM EXTERNAL JUGULAR.



(3) Divide the fibres of the platysma transversely. (4) Open the vein by an oblique incision (exactly the same direction as that made in the skin, but rather smaller). To stop the bleeding place a pad of boracic lint over the wound and hold in position by a domett bandage and plenty of cotton wool.

Internal Jugular Vein.—This is the continuation of the lateral sinus, and just at the base of the skull it is dilated into a *sinus* or *gulf*. It lies to the outer side of the internal and common carotids, and joins with the subclavian to form the innominate vein. At first it lies on the rectus lateralis and to the outer side of the internal carotid and the eighth pair of nerves; lower down

the glosso-pharyngeal and the ninth nerve pass forwards between the artery and the vein, while the spinal accessory passes obliquely outwards behind (sometimes in front of) the vein, and the vagus passes downwards behind and between the artery and vein. On the right side, at the root of the neck, the vein is a little way to the outer side of the common carotid, but on the left side it usually crosses the artery at this point. The right internal jugular crosses the first part of the subclavian artery. In the jugular foramen this vein lies in the posterior compartment, the end of the inferior petrosal sinus in the anterior, and the three divisions of the eighth pair of nerves in the middle compartment.

Arteriotomy from Anterior Branch of Temporal.—This may be necessary in affections of the eye, *e.g.*, in iritis when there is great pain, although leeches are usually preferred. Its pulsations can be felt about one inch and a quarter behind the external angular process of the frontal bone. Compress on the *distal* side of the intended opening, to fill and distend the vessel (veins should be compressed on the *proximal* side). Expose it by cutting through the superficial structures and the dense fascia covering it, and then make an oblique opening into it, taking care not to cut it completely through. To stop the flow, cut the artery completely through, when its coats will, as a rule, contract and retract sufficiently to stop the bleeding; if not, secure by acupressure, or ligature the cut ends. A pad is then to be placed over the wound, and held in position by a “stella” bandage.

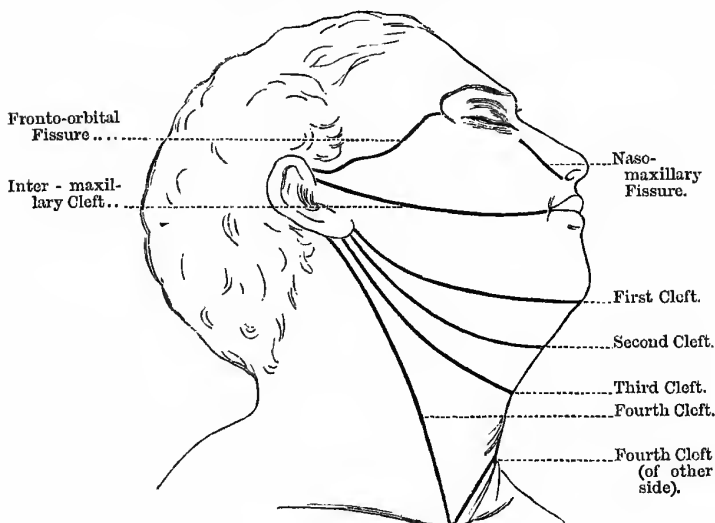
BRANCHIAL CYSTS AND FISTULÆ.

About the beginning of the second month of foetal life the pharynx forms an open cavity bounded on each side by four branchial or visceral arches with their corresponding clefts. The upper end of the cartilage of the *first visceral arch* (MECKEL'S cartilage) is ossified into the malleus, and in the membrane surrounding the rest of this cartilage the lower jaw-bone is formed; when the lower jaw is very small or altogether wanting, it is from some arrest of development of this arch. From the cartilage of the *second arch* are developed the incus and stapes, the styloid process, and the lesser cornu of the hyoid bone, and possibly also the stylo-hyoid ligament. From the *third arch* is formed the great cornu

and body of the hyoid bone. The *fourth arch* assists in forming the soft tissues of the neck. From the *first cleft* the external auditory meatus, the tympanic cavity, and the Eustachian tube are developed; the other clefts should unite during early foetal life. The position of the *second cleft* is between the lower jaw and the hyoid bone; the internal orifice of this cleft corresponds to the fossa of ROSENMÜLLER. The *third cleft* is sometimes met with passing from over the thyroid body towards the great cornu of

Fig. 123.

LINES OF THE BRANCHIAL CLEFTS.



the hyoid bone; it may sometimes communicate with the trachea. The *fourth cleft* passes along the anterior edge of the sterno-mastoid, and may communicate with the trachea or œsophagus (Fig 123).

Branchial Fistulæ are formed in two ways—(1) Where the entire tract remains open; and (2) where one end is closed, the other end opening on the skin, the trachea, or œsophagus. They form indurated tracts with a thick, honey-like secretion, which thickens over the cutaneous orifice; should it communicate with

the trachea or œsophagus, air or food will pass through. The only cure is to excise the whole tract; should it communicate with the air or food passages, then perform Mr DUNCAN'S operation of separating the cutaneous from the mucous surface, and stitching each to each.

Branchial Cysts are formed by closure of the cleft at both ends while the middle part is not obliterated. In this way a portion of the epiblast is included and embedded in the deeper tissues, forming the so-called dermoid cysts, and which most frequently develop into prominence from the tenth to the thirtieth year. It is doubtful, however, whether a dermoid cyst and a branchial cyst are the same; the germ of a *branchial cyst* is laid down *before the appendages of the skin* are developed, and, therefore, should only contain *epithelium*. But the wall of a dermoid cyst contains hair follicles, sweat and sebaceous glands, and occasionally teeth, nails, fingers, etc. Many names are applied to these congenital cysts. ROSER calls them branchial cysts; LANGENBECK, dermoid cysts of the sheath of the internal jugular vein; SCHEDE, deep-seated atheromatous tumours; VIRCHOW, tumours of the branchial clefts; MANNOIR, hydrocele colli congenita; LUSCHKA called them hygroma colli, and said that they were probably a cystic degeneration of the "carotid ganglion"; and LUECKE, atheromatous cysts of lymphatic glands. Very often these tumours have a close connection with the sheath of the internal jugular vein, and hence they will be slightly movable from side to side, but perfectly immovable from above downwards. The serous *branchial cyst*, or **hydrocele**, is found in children or in young adults; the walls are very thin and vascular, and the contents serous. They are often situated at the root of the neck, behind the sterno-mastoid, and may dip down to the first rib and pleura, and are unilocular, and may be symmetrical. Many of the **ranulas** about the base of the tongue are probably dermoid in nature; this variety is recognised by its deep position and fixity, and the absence of the usual opalescent or bluish appearance. The term **hygroma** is more properly applied to multilocular fibro-cystic tumours, probably from the intra-uterine transformation of a subcutaneous nævus of ordinary type, or it may be a lymphatic nævus; sometimes one may find a bit of nævoid tissue in the neighbourhood, or a great growth of hair.

It may be partly solid and partly cystic; it occurs in the subcutaneous tissue in the middle line of the neck, in front of the trachea; it also forms one variety of the congenital sacro-coccygeal tumours.

RANULA.

This is a name applied to a cystic tumour in the sublingual region, pushing up the tip of the tongue, and carrying the body of the organ upwards and backwards. It interferes with the use of the tongue, and the voice is harsh and croaking, like the sound produced by the croaking of frogs; hence the term *ranula*. It also interferes with deglutition, and may even affect respiration, threatening suffocation, especially in cases where the swelling forms or increases rapidly, as it does in the form known as "*acute ranula*."

Varieties.—(1) The usual form, with glairy mucous fluid. It forms a prominent swelling of a peculiar bluish tinge, from the contained fluid being seen through the mucous membrane, usually situated on one side of the middle line. The cyst wall is exceedingly thin, and seems to be formed by part of the natural structures; it is almost impossible, and quite useless, to attempt to dissect out the cyst in the usual form of ranula.

Its nature is disputed—(a) Some regard it as a true neoplasm—a cyst of new formation; (b) others as a "retention cyst" formed by obstruction of a mucous follicle under the tongue (= a *mucous cyst*); and (c) by others, again, it is regarded as a "retention cyst," due to obstruction of *some of the acini (not the main ducts)* of the sublingual or the submaxillary glands, as by a calculus. This view is **supported** by the uniformly constant position and the relations of the tumour, and the slightly sacculated appearance of the cavity when opened, and the absence of a separate cyst wall. The **objection** is that the contents are not like saliva, and that we meet with similar swellings *on the lips*, whose contents are also exactly like the glairy mucous fluid of the ranula. (d) There is another possible origin in the *sublingual bursa mucosa*, or space between the genio-hyoglossus and the mucous membrane of the floor of the mouth, lined with squamous epithelium. (e) A ranula may also arise in connection with the glands of BLANDIN and NUHN. These

glands are found on the under surface of the tongue, near its tip, under the mucous membrane. The glands are of the racemose type of structure, and form two small oblong masses. This view of the possible origin of these tumours receives support from the fact that the tongue often seems to be hollowed out into one huge thin-walled cyst when the finger is introduced.

Treatment.—Simple incision and drainage, as sometimes recommended, is absolutely useless, and a seton is painful, troublesome, and unnecessary. The plan to be adopted is to seize the upper wall of the swelling with a pair of the old artery forceps, and cut out a large oval portion with a pair of scissors, evacuate the contents, and keep this opening patent, by passing a probe into it every day, till it heals from the bottom upwards; some paint the interior of the cavity with a strong solution of iodine or nitrate of silver, so as to make the obliteration quicker and more certain. The mucous labial cysts, and similar growths of the tongue, are treated in the same way.

(2) Another variety of ranula is the **dermoid cyst**, with porridge-like contents, consisting of epithelial cells, hairs, etc. This form occurs in the situations of the embryonic visceral clefts—either in the middle line or at the side, between the mylo-hyoid muscle and the mucous membrane; it is deeper than the first variety of ranula, and has not the bluish opalescent appearance, but it has a distinct and separate cyst wall, so that it can be entirely removed, both cyst and contents. This variety often projects under the angle of the jaw, and may be attached to the sheath of the carotid vessels. The **treatment** is to expose and enucleate the cyst, with the handle of the scalpel, if possible without opening the cyst.

(3) A third variety is of the nature of an **enlarged bursa**, either the *sublingual bursa mucosa*, or the bursa occasionally found above the hyoid bone, between the genio-hyoid and the genio-hyoglossus muscles; this variety may project very markedly into the neck, and, of course, is always in the middle line; it forms one variety of "*hydrocele colli*."

Cervical Auricles are often associated with branchial fistulæ, and when so are usually placed along the anterior border of the sterno-mastoid, the fistula lying beneath and partly covered by the auricle.

HARE LIP AND CLEFT PALATE.

To understand these conditions it will be necessary to say a few words as to their development. Between the first visceral arch and the frontal protuberance of the embryo is situated the buccal depression, which in time becomes the mouth. The

Fig. 124.

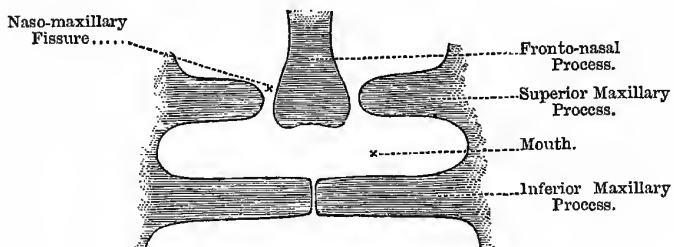
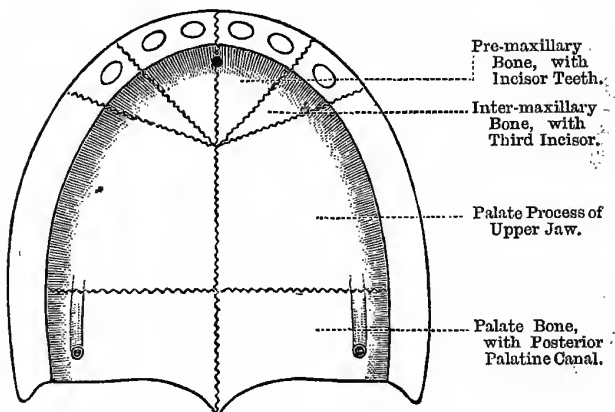
DEVELOPMENT OF MOUTH.

Fig. 125.

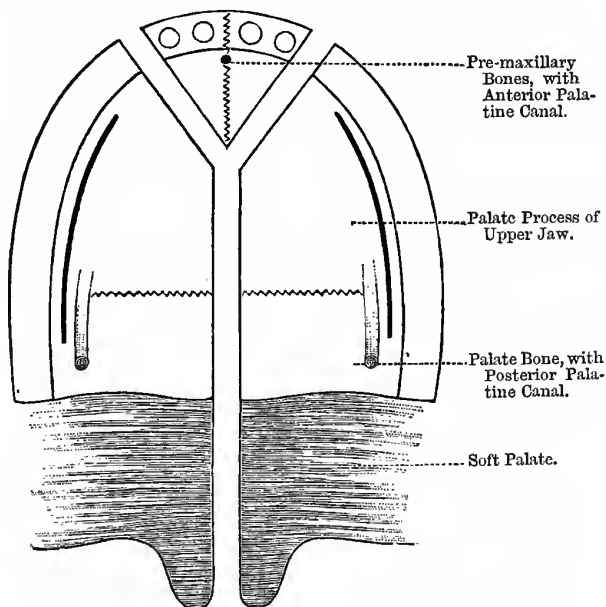
THE BONES OF A TYPICAL PALATE.

frontal protuberance sends down the fronto-nasal process from which are developed the vomer, the triangular cartilage, and soft coverings of the nose, the pre-maxillary and, when present, the inter-maxillary bones, with their contained incisor teeth, and the

central part of the upper lip. The first visceral arch divides at its anterior extremity into a superior and an inferior maxillary process. The inferior processes on each side unite at a very early period to form the lower jaw, and the superior maxillary

Fig. 126.

COMPLETELY CLEFT PALATE.



The dark line on each side indicates the position of the incisions in cases of operation for the cure of cleft hard palate. The incisions must not injure either the anterior or the posterior palatine vessels, and, therefore, must not go too far forwards or be prolonged too far backwards.

processes and the frontal process should also unite together, probably between the sixth and twelfth weeks of foetal life, to form the upper lip and complete alveolar ridge (Fig. 124). Any arrest of development during this period will result in more or less complete hare lip, and as the frontal process forms the centre

parts of the upper lip and jaw, it is easy to see that the gap must necessarily be at one or other side, or on both sides, as the case may be. There is a fissure between the fronto-nasal process and the parts that form the upper jaw and cheek, passing from the inner canthus to the ala of the nose; occasionally there is complete non-closure of this fissure coupled with hare lip on the same side. In this rare condition the lachrymal sac with the canaliculi and the nasal duct are absent, or form an open gutter. In regard to the **palate**, at the sixth week of foetal life the mouth, nose, and pharynx form one large undivided space. Soon, after this, however, a process begins to grow inwards from the alveolar ridge on each side, which ultimately form the hard and soft palates, except the part in front of the oblique sutures formed by the pre-maxillary, and sometimes in addition by the inter-maxillary bones, which are developed from the frontal protuberance (Fig. 125). The palate should be completed about the ninth week. In the lips and palate, therefore, the line of union is Y-shaped, the upper diverging arms representing the pre-maxillary sutures, while the straight part represents the line of union between the two sides of the palate. Non-union may occur along the whole of this line, giving the most extreme degree of combined hare lip and cleft palate, in which case the part of the frontal process which should have formed the central part of the upper lip and alveolus is attached to, or rather has not separated from, the tip of the nose (Fig. 126). It may vary from this, the most extreme form, to a mere slit or dent in one lip, usually the left. The sides of the cleft are usually of unequal depth, a point that must be kept in mind in operating.

Varieties of Hare Lip—

1. **Single Hare-lip**: from a mere nick in the free edge of the lip, to a complete cleft into the nostril. The bone may or may not project unduly at one or other side.
2. **Double Hare-lip**:
 - (a) Without bony deformity (of pre-maxillary bone).
 - (b) With marked bony deformity.

Either form may be accompanied or not with a greater or less degree of cleft palate. In cases of single hare-lip with marked flattening of one nostril, Mr ANNANDALE separates the cleft half

of the lip very freely from the jaw, but leaves the sound half attached, so as to give a fixed point to pull the other side towards the middle line, in order to lessen the flattening of the nostril. In cases of double hare-lip, the inter-maxillary bone and the tissues covering it, are, as a rule, only used to form the columna and to push up the point of the nose.

In operating for hare-lip, the following **Structures** will be divided from without inwards:—(1) The skin; (2) the superficial fascia; (3) the orbicularis oris muscle; (4) the coronary vessels; and (5) the mucous glands and mucous membrane. Note the position of the vessels between the muscle and the mucous membrane.

In operating, the chief points to attend to are—(1) To pare the edges *freely*, so as to give a raw surface with sharp corners and not rounded edges; (2) to loosen the mucous membrane between the lip and the gum freely, to avoid tension on the sutures, and obviate the necessity of such things as trusses, etc.; and (3) to make the vertical depth of the lip too great at first, so as to prevent any nick or dent in the lip afterwards. For this purpose some are content to trust to free paring of the edges and loosening of the mucous membrane and neat apposition with sutures (Figs. 127, 128); others (as the late Mr SPENCE) make the raw edges concave, from above downwards (Figs. 129, 130). NÉLATON, in cases where the fissure does not extend up to the nose, does not pare off the parts from the sides of the cleft, but leaves them attached to the free edge of the lip, and brings them down so as to make a diamond-shaped wound instead of the usual triangular cleft; a somewhat similar plan may be adopted in cases where a marked "nick" is left after a previous operation (Figs. 131, 132, 133). The sides are then brought together, and instead of a depression there is a distinct projection at the site of the former deficiency. In other cases only one of the tags is left, which is then brought across the cleft and stitched to the opposite side. In other cases parts of both tags may be left and turned down, so as to form a little projection at the free border of the lip (Figs. 134, 135). The best age for operating will depend on the strength and health of the patient, unless the want of strength is due to the condition in question, but otherwise no time is too

OPERATION FOR HARE LIP—FIRST FORM.

Fig. 127.

FIRST STAGE.

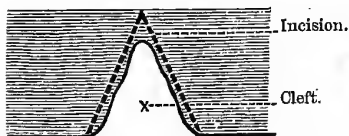
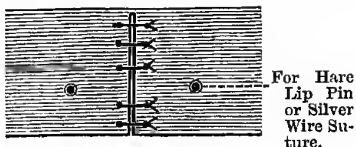


Fig. 128.

SECOND STAGE.



OPERATION FOR HARE LIP—SECOND FORM.

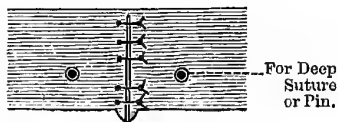
Fig. 129.

FIRST STAGE.

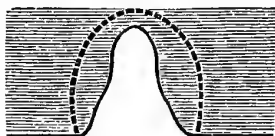

Fig. 130.

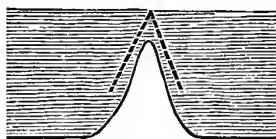
SECOND STAGE.



OPERATION FOR HARE LIP—THIRD FORM.

Fig. 131.

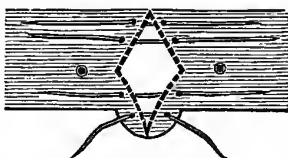
FIRST STAGE.



Incision.

Fig. 132.

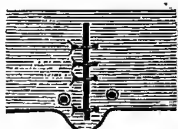
SECOND STAGE.



Sutures in Position.

Fig. 133.

THIRD STAGE.



Sutures Tightened.

OPERATION FOR HARE LIP—FOURTH FORM.

Fig. 134.

FIRST STAGE.

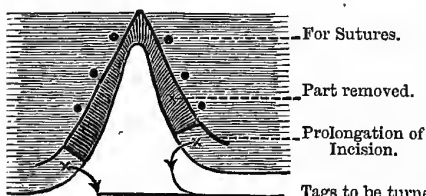
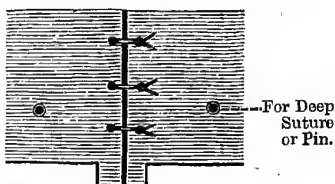


Fig. 135.

SECOND STAGE.



For Deep Suture or Pin.

soon, as the amount of blood lost is next to nothing, and the operation enables the mother to feed the child better, and also tends to bring the sides of the cleft in the palate together. It may be done from a few weeks after birth up to the third or fifth month, usually always before the first dentition. If not done by that time, it must be left till after the completion of the first dentition—after the second year.

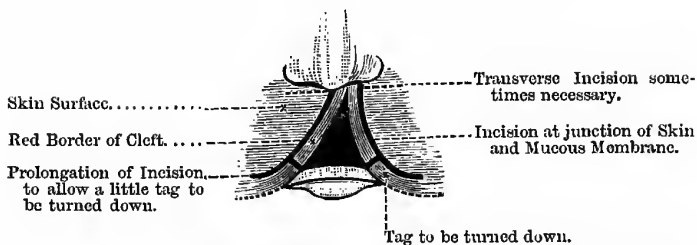
Instruments required.—A well-worn and very sharp scalpel, several pairs of WELLS'S forceps, dissecting forceps, hare-lip pins, wire-cutting nippers, silk sutures for the mucous membrane, horse-hair sutures for the skin, silver wire for deep sutures, adhesive plaster, catgut ligatures, flexible collodion, scissors, sponges—large and small, some fastened on small sticks, or on special sponge holders, or else grasped by a pair of PÉAN'S forceps,—bone pliers, and a large sheet in which to wrap and hold the child. To steady the parts after operation, a button suture is probably better than the old hare-lip pin and twisted suture.

In cases of double hare-lip, where there is *no deformity of the inter-maxillary bones*, the edges of the central part are pared, and it is pushed up to form the columna of the nose. Where *there is bony deformity*, the bone may be either pushed back or removed altogether; to push back, one may use simple force, or partially divide its neck and then force it back; if large and strong, and very projecting, it should be removed, at the same time making use of the muco-periosteal and cutaneous tissues to form the columna of the nose. This should be done as a preliminary operation, some time before closing the cleft.

Many years ago, DR JOHN DUNCAN first taught that the proper way to operate for fistula—*e.g.*, fæcal fistula—was, not to *pare* the edges, but to split them. The advantages of so doing are—(1) No tissue is lost, so that the sides are more easily brought together; and (2) it affords a *broad* raw surface, along which union may take place. The mucous surfaces are turned inwards and stitched, and then the skin surfaces turned outwards and also stitched. The principle of this excellent method has been gradually applied to other fistulae, congenital or acquired; it was further adapted by Professor CHIENE to the cure of ruptured perinaeum, and recto-urethral fistula; and quite recently, at his

Fig. 136.

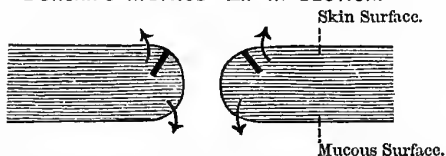
OPERATION FOR HARE LIP—FIFTH METHOD.



To show Cleft with Incisions used when Dr Duncan's method is adopted.

Fig. 137.


DUNCAN'S METHOD—LIP IN SECTION.



Incision at junction of Skin and Mucous Membrane. Arrows indicate how the flaps thus formed are to be turned.

Fig. 138.

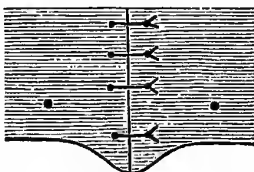
DUNCAN'S METHOD—STITCHING.



Arrows show how the Skin Flaps are drawn together.

Fig. 139.

DUNCAN'S OPERATION—FINISHED.



suggestion, it has been extended by Dr DUNCAN to the treatment of hare-lip, with the best possible results. Nothing is pared away at all, and instead of the thin scar-like union, we have a broad thick lip (Figs. 136 to 139).

The lip is split at the point where the red mucous membrane joins the white skin, and not in the centre, therefore, of its thickness; the mucous membrane is folded inwards towards the mouth, and the skin surface folded outwards, and then each stitched to each. It may be necessary to make short transverse incisions at one or both ends of the vertical cut, in order to allow the skin to fold outwards without wrinkling; and a further short transverse incision may be made at the lower end and a little piece turned downwards, in order to have a slight projection at the free edge of the lip, to avoid any approach to a nick afterwards.

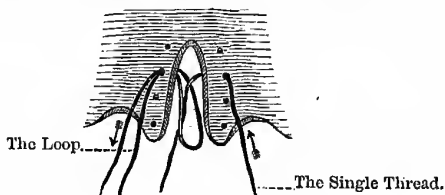
In suturing the lip some Surgeons use three kinds of sutures—(1) A silk suture is passed through the mucous membrane of the inner side of the lip, and left untied; (2) a deep silver-wire suture is then passed through the tissues of the lip, to steady the parts and act as a splint, but is also left loose; and (3) horse-hair sutures are used to bring the skin edges together. The sutures thus introduced are tied in the reverse order—viz., the horse-hair, silver-wire, and, lastly, the silk suture through the mucous membrane of the prolabium. The suture through the mucous membrane (silk) is introduced first, because when the others are tightened it would be almost impossible to introduce it; before tightening it, see that there is no blood clot between the edges of the mucous membrane, as it is important for the after result to secure neat apposition and early union. On account of the narrowing of the nostrils, and the altered condition of the child's mouth in general, for a short time after the operation, it is apt to become semi-asphyxiated, or may even choke altogether, from its tongue sticking against the roof of its mouth; the nurse should therefore be warned about this, and be prepared, with the handle of a teaspoon, to bring the tongue down to the floor of the mouth should signs of choking supervene. In cases where silver sutures are used, the mother must be warned about them, lest shawls or other articles of dress be caught by the end of the wire, and the sutures torn open; for the same reason, the ends of the wire should be covered up as much as possible.

If a hair-lip pin be used its point must also be carefully guarded ; it should be removed in forty-eight hours, otherwise it will cause suppuration.

Staphylorrhaphy, or operations for the cure of clefts in the soft palate. In this case it is of great importance to avoid tension on the stitches, as otherwise they are apt to cut their way out. In cases where hare lip and cleft palate co-exist then the lip must be cured first, and very often after this the palate improves wonderfully. The operation should be done, if possible, before the child begins to learn to speak. The best age is about the end of the second year, or sometime between the first and second dentitions, say between four and five. It should not be done before this, as there is a good deal of blood lost, and children bear loss of blood *very* badly. As a child with cleft palate cannot suck, it will be necessary to adopt some artificial means of feeding it. In cases where the cleft in the hard palate is very wide, cure by operation is out of the question, the case being one for the dentist ; in fact, it is a question whether many of the so-called suitable cases should not be left to the dentist, as the subsequent cicatricial contraction often leads to great deformity of the palate from the approximation

Fig. 140.

TO PASS THE SUTURES IN CLEFT PALATE.



of the two alveolar processes, and great difficulty of articulation : it is not merely a question of operative dexterity. In less marked cases we may adopt LANGENBECK'S plan of levering up the muco-periosteal tissue with an elevator and making the flaps from the two sides meet across the gap. Before doing so, however, it is necessary to make liberating incisions along the inner side of the alveolus, taking care that they do not go back beyond the last molar tooth or forward beyond the canine tooth, lest the anterior

and posterior palatine vessels, on which the nutrition of the periosteal flap depends, be divided (see Fig. 126). The vessels are to be raised and carried with the flap; the mucous membrane of the hard palate and the periosteum form one layer, so that it is impossible to separate them. In very bad cases an attempt may be made to shift bones and all (FERGUSSON). In some cases where the cleft is wide and from end to end, a curved needle can be passed through one side, and then the other, by the aid of HAGADORN'S needle-holder, or a doubly curved needle on a handle may be used. In other cases, to avoid the difficulty of passing the thread through the right side (the patient's) from behind forwards, pass a single thread through one side of the cleft and a loop through the other, both from before backwards; then pass the single thread into the loop and withdraw the loop, which will thus leave the thread in position (Fig. 140). If desired, a silver suture may also be attached to the silk thread, which is in turn withdrawn, leaving the silver suture in position. Pass all the sutures before tying any of them, and in tying, begin at the highest suture. In tying silk sutures pass one end through a running noose on the other, run it on till the edges are approximated, and then fix by tying a single common knot.

The term **Uranoplasty** is sometimes applied to operations for the cure of fissures in the hard palate; the student must remember that the term has got nothing to do with the urine, or with plastic operations on the penis or urethra, as they sometimes seem to think, to the no small amusement of examiners. A narrow, highly-arched palate is one of the effects of inherited syphilis, and a somewhat similar condition is observed in cases of idiocy.

For the **Soft Palate**—(1) Liberating lateral incisions may be simply made with the scissors, through the entire thickness of the velum, in the way recommended by Mr BRYANT. (2) FERGUSSON'S plan of dividing the perpendicular part of the levator palati midway between the Eustachian tube and the hamular process, by means of a rectangular knife passed through the cleft in the palate. (3) POLLOCK'S method of dividing both the tensor and the levator by means of a knife passed through the soft palate close to the inner side of the hamular process. It may also be necessary to divide the palato-glossus and the palato-pharyngeus muscles (the anterior and posterior pillars of the fauces), which can easily be

done by a touch of the knife. The point where the greatest difficulty in approximation is experienced is just where the soft palate joins the hard. Here the soft palate is attached to the hard by dense antero-posterior bands of fibrous tissue, between the anterior and posterior mucous surfaces. In order to secure easy approximation it is necessary to divide everything between the two layers of mucous membrane, or even to divide everything except the mucous membrane in the mouth-aspect of the soft palate, for the most important part of the whole operation is to avoid tension on the stitches. Dr DUNCAN, after having approximated the two sides, simply feels with his finger for any tense structure anywhere and divides it, until there is an entire absence of tension.

In this operation the following Structures, composing the Soft Palate, are divided from before backwards:—

1. Mucous membrane.
2. Submucous tissue, glands, vessels, etc.
3. Palato-glossus muscle.
4. Aponeurosis of the tensor palati.
5. Palato-pharyngeus, anterior fasciculus.
6. Levator palati and azygos uvulæ muscles.
7. Palato-pharyngeus, posterior fasciculus.
8. Submucous tissue, glands, vessels, etc.
9. Mucous membrane.

To assist the memory notice that they run in pairs, the first and ninth, the second and eighth, and so on.

Instruments required.—A long-handled well-worn scalpel, FERGUSSON'S rectangular knife, curved scissors, forceps to grasp the palate while paring it, special needles on handles for passing the sutures, HAGADORN'S needle-holder, gag, periosteum elevators, chisel, silk sutures, catgut ligatures, dissecting forceps, silver-wire, sponges on sticks, or special sponge holders, or grasped by PÉAN'S forceps, chloroform, etc.

Dermoids of the Palate.—These arise from faulty closure of the cleft between the two sides of the palate. They are of two kinds—*Epithelial Pearls* and *Dermoids proper*. (1) The **Epithelial Pearls** are small bodies, from the size of a millet seed to a pea, that hang down by short pedicles from the median raphé of the

palate, and are composed of epithelial cells. (2) **Dermoids proper** also occur here, and at first sight may be mistaken for an additional tongue, being of the same colour and consistence as that organ.

THE TEETH.

In connection with the inter-maxillary and pre-maxillary bones, and the occasional presence of three incisor teeth on each side instead of the usual number, in man, it is interesting to observe the presence and disappearance of a similar condition in the lower animals. In the Ungulata, or hoofed quadrupeds, including the Pachydermata (*e.g.*, tapirs), the Solidungula (*e.g.*, the horse, the ass, and the zebra), and the Ruminantia (*e.g.*, the ox, the sheep, and antelope), three incisors is the rule. In the typical ruminant, as the ox, we find three in the lower jaw, but none in the upper, only a callous pad of hardened gum against which the lower incisors impinge. In the Carnivora, also, as the lion and tiger, three incisors is the rule. Approaching the higher group of the animal kingdom, the Quadrumana, we find that the true lemurs, found in Madagascar, and which may be regarded as the lowest order of the group, have usually three incisors, though they may be very much modified, as when met with in man. In the Platyrrhine group the dentition is almost the same as in man, only the premolars are more numerous; and in the highest or Catarrhine group, which includes the anthropoid apes, the dentition is exactly the same as in man.

Eruption of the Teeth in Man.—The **milk** set are twenty in number, and appear during the following *months* :—

Incisors.	Canines.	Molars.
7-9	18	12-24

This only represents a half of one jaw, but the rest are just the same, only the lower teeth usually appear a little in advance of the upper. The **permanent** teeth are thirty-two in number, and appear during the following *years* :—

Incisors.	Canines.	Bicuspid.	Molars.
7-8	11-12	9-10	6, 12-13, 17-25

Or the years may be arranged thus :—

<i>m.</i>	<i>i.</i>	<i>i.</i>	<i>b.</i>	<i>b.</i>	<i>c.</i>	<i>m.</i>	<i>m.</i>
6	7	8	9	10	11-12	12-13	17-25

At six years of age the child possesses the greatest number of teeth—viz., forty-eight—twenty deciduous and twenty-eight permanent.

There are a few important clinical and medico-legal points to be noticed in connection with the *permanent* teeth:—

1. In **Hereditary Syphilis**, the *upper central permanent incisors* are short, narrow, and peg-shaped, widely separated, and slant towards each other; they are “notched” from defective development of the middle lobe, giving them a screw-driver-like outline. The angles are rounded off, and their sides are convex in outline. In pure syphilitic teeth the enamel is smooth and regular, except at the part where the notch occurs; in the first instance, the place occupied by the notch is filled up by spines, but these wear off and leave the crescentic notch in the biting edge. This condition of the teeth is often accompanied with interstitial keratitis and choroiditis disseminata (HUTCHINSON). It is probably due to the action of the specific stomatitis upon them while they are yet soft and uncut.

2. In “**Mercurial**” Teeth (HUTCHINSON), the result specially of mercurial stomatitis in childhood, the *first molars* of both jaws are the test teeth. In this case the deficiency chiefly concerns the enamel, and the exposed dentine is dirty, rugged, and pitted, and in some cases the enamel is cut off at one level all round, leaving a stump of exposed dentine; there is no characteristic notch, as in syphilis. The honeycomb excavations and the horizontal markings in the enamel distinguish them from syphilitic teeth. The first molars suffer most, as they are the first to develop; the origin of the mercurial stomatitis is that the child has probably suffered from fits in infancy, and been dosed with calomel. This condition of the teeth is often accompanied with *lamellar*, or *zonular*, *cataract*—a condition that also points to infantile convulsions at an earlier period. It is possible, of course, to find both these conditions of the teeth present in varying proportions: the notched and pegged condition of syphilis, and the pitted, discoloured appearance of mercurial stomatitis.

3. It is very important to remember the dates of eruption of the permanent teeth in the treatment of cases of **irregularity** or **overcrowding**; in some cases the teeth, as it were, cannot all find

room, and the first-comers may take more than their own share of space. This irregularity is usually among the teeth anterior to the bicuspid, and it may be necessary to remove some of the permanent teeth in order to make room for the others, and it becomes a question of the "survival of the fittest." Remember that the *canines* are the most durable, and in this respect, therefore, the most valuable; but they do not make their appearance till the eleventh or twelfth years, and, therefore, their temporary predecessors should not, if possible, be removed, as they, as it were, keep a place for the permanent ones. Note also that the first molars, the first of the permanent set to appear, are the least durable, and therefore, in this respect, of but little value, and may be sacrificed without any scruples, if necessary.

4. In **Extracting Teeth** with the forceps, remember two points—(a) That, like the stones of an arch, the fangs of the teeth are broadest on their outer aspect, and (b) that the outer wall of the socket—except in the case of the last molars of the lower jaw—is much thinner and weaker than the inner one; hence, therefore, in using the forceps, the force must be applied in an *outward* direction, otherwise much difficulty will be experienced.

5. In using the **Elevator**, to get rid of roots or stumps, remember that the transverse partitions are less dense in structure and yield more readily than either the outer or the inner walls, and direct the force towards, or against the spongy partitions rather than against the lateral walls.

6. From a medico-legal point of view, the date of eruption of the second molar tooth should be noted in cases of supposed violation of the **Factory Acts**, as children are often sent to work in factories before the age of thirteen; of course, the presence or absence of the second molar tooth is not conclusive, but, along with other points, it is of considerable value.

7. Note, lastly, that bad teeth, or rotten stumps, are a fertile cause of various disorders—(a) They are an exceedingly common cause of neuralgia or headache, (b) they are also the cause of one form of acute ear-ache, (c) they may cause spasmodic closure of the jaws, and (d) they are a very frequent source of enlarged glands in the neck.

CHAPTER XXX.

WOUNDS OF THE SCALP.

THESE, however slight, should be watched very carefully, because of the close anatomical relations that exist between the internal and the external structures of the cranium, and the possibility, therefore, of the effects of the injury implicating the brain and its membranes; and all the more so when we bear in mind that, from the nature of the textures wounded, they are far more likely to be followed by erysipelas and diffuse septic cellulitis than wounds in other parts of the body. Sometimes, too, the external injury may seem very trifling, and yet the internal injury be very great; every case should be carefully watched for at least a fortnight. In wounds *into* the scalp there is no gaping of the edges of the wound, but in incisions *through* the scalp there is much gaping, opening up the "dangerous area" and exposing the pericranium at the bottom of the wound. All cases of head injuries must be kept under observation for at least a fortnight, as inflammatory processes are often not developed for a considerable time after the accident. The chief anatomical peculiarities of the scalp are—(1) The great amount of dense fibrous tissue that enters into its formation. (2) Its great vascularity, and, consequently, (3) its great vital activity. (4) Its vascular connections with the cranial bones and dura mater; this is especially the case with the cellular tissue on its deep surface, which is largely permeated by blood-vessels, which enter the bones and communicate in the diploë with branches from the dura mater. At several places, also, large vessels pass directly through from the scalp or face, and communicate with the various sinuses and arteries within the cranium—*e.g.*, at the occiput, the meningeal branches of the occipital artery anastomose with those of the

vertebral: behind the ear, a large vein passes through the mastoid foramen to the lateral sinus: on the vertex, another vein passes through the parietal foramen to the superior longitudinal sinus: on the face, at the inner angle of the orbit, the angular artery and vein anastomose with the nasal branch of the ophthalmic artery and ophthalmic vein, and other branches of the ophthalmic artery anastomose with the middle meningeal. There are other communications through the anterior and posterior condyloid foramina, foramen ovale, foramen lacerum posticum, and most other openings at the base. Leeches may be applied at many of these parts to relieve congestion of the brain. Another important communication exists between the facial vein and the cavernous sinus (besides the one through the orbit) through the pterygoid plexus, a plexus formed by the middle meningeal vein, deep temporals, pterygoids, masseteric, buccal and inferior dental, and which is situated between the external pterygoid and temporal muscles, and partly between the two pterygoids themselves, and is connected on the one hand with the facial vein and on the other with the cavernous sinus through the foramen Vesalii.

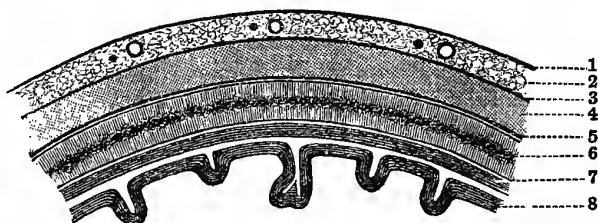
The **Veins** of the diploë are four in number—the *frontal*, which opens into the supra-orbital vein; the *anterior temporal*, which opens into one of the deep temporal veins; the *posterior temporal*, which ends in the lateral sinus; and the *occipital*, which is the largest of the four, and which opens either into the occipital vein or into the occipital sinus. The walls are formed only of epithelium resting upon a little elastic tissue, and have many *culs de sac*. These communications between the external vessels and those of the diploë, and also of the latter, with the sinuses of the dura mater, explain the great danger of erysipelas and other inflammatory conditions, such as carbuncle (especially “malignant facial carbuncle”), attacking the face and scalp, and all the more so in cases where there is, or has been, an open wound, and probably therefore septic matters have gained an entrance. The inflammation causes thrombosis in some of the venous trunks, usually the facial; these thrombi probably are, or soon become, septic, break down, and give origin to minute septic emboli, which spread widely and give rise to all the signs of pyæmia. Or the inflammation may pass directly backwards along the veins to the

cerebral sinuses. Malignant facial carbuncle usually commences in the lip, and has a special tendency to attack young adults. The facial vein is specially liable to be affected in simple septic or specific infective inflammations, as carbuncle, cancrum oris, and malignant pustule, and lead to serious or fatal results. The walls of this vein do not collapse so readily as those of most superficial veins; it is destitute of valves, and communicates with the cerebral sinuses on the one hand, and the internal jugular vein on the other, and thus every facility is afforded for the absorption and diffusion of septic products.

A blow with a blunt weapon, at right angles to the bone, may produce a wound with apparently clean-cut edges, just like

Fig. 141.

THE SCALP.



- | | |
|--|---|
| 1. The Skin. | 4. Layer of loose Cellular Tissue
—“dangerous area.” |
| 2. Superficial Fascia, with Vessels
and Nerves. | 5. Pericranium. |
| 3. Tendon of Occipito-frontalis. | 6. The Bone. |
| | 7. Dura mater. |
| | 8. Brain. |

an ordinary incised wound; the difference is, that with the blunt instrument, hair-bulbs are found projecting from the surface, and the wound will not heal by the first intention, as slight sloughing will be produced; whereas, with a **sharp instrument** the hair-bulbs are cut across, and with a magnifying-glass the edges are seen to be perfectly clean-cut, and the wound will probably heal by the first intention.

Between the grey matter on the surface of the brain and the outside, the following Structures intervene (Fig. 141):—1. **The Scalp**, consisting of—(a) The skin; (b) the superficial fascia, with fatty tissue and the arteries and nerves of the scalp; (c) the

central tendon of the occipito-frontalis. The subcutaneous tissue consists of fibrous bands, for the most part directed *vertically*, being firmly fixed to the skin above and the fascia below; the horizontal meshwork is very scanty; between the fibrous bands are lobules of dense fat. It will be seen, therefore, that it is just the reverse of the usual forms of subcutaneous tissue, where the vertical fibres are very scanty. The palm of the hand and the sole of the foot resemble the scalp in texture, and in all three places it is impossible to pinch up the skin between the finger and thumb. Then follows (*d*) a layer of loose cellular tissue, over which the above three layers, which are really *one*, can be moved freely; this is often called the "dangerous area" of the scalp, from the ease with which suppurative processes are set up in wounds extending to this layer, and which then spread in all directions. Were it not for the presence of this layer, too, the time-honoured Indian custom of "scalping" could not be performed; but all that is necessary is simply to make a circular incision at the proper place down to this layer, and then by a sharp tug the included portion separates. 2. **The Bone.**—This may be regarded as consisting of—(*a*) The pericranial aponeurosis, which is firmly attached to the "sutural ligaments" at the various sutures; (*b*) outer table of the skull; (*c*) the diploë, with its large venous trunks; and (*d*) the inner table, characterised by its great brittleness (*lamina vitrea*), and hence it may be fractured without any fracture of the external table, and is usually more extensively broken than the external—*e.g.*, in punctured fracture; it is also thinner than the outer table. 3. **The Brain**, including—(*a*) The dura mater; (*b*) the subdural space (the so-called "*arachnoid cavity*"); (*c*) the curtain-like arachnoid; (*d*) the subarachnoid space, containing the cerebro-spinal fluid, upon which the brain floats, as upon a water bed, especially in the middle and posterior fossæ, but in the anterior fossa the brain rests directly on the bone; (*e*) the pia mater; and (*f*) the brain substance proper.

Attachment of the Pericranial Aponeurosis and Occipito-Frontalis.—It is *firmly* attached to the fat and fascia superficial to it, but only *very loosely* connected with the parts beneath by means of fine cellular tissue. **Posteriorly**, it is attached to the superior curved lines of the occipital bone; at the **sides**, to the

mastoid process, attollens and attrahens aurem muscles, and zygoma ; in front, it is blended with the corrugator supercillii, orbicularis palpebrarum, and the pyramidalis nasi. The two bellies of the occipito-frontalis arise in front and behind at the points indicated, and both are inserted into the broad tendinous aponeurosis which extends over the top of the head. The connection of the anterior belly with the muscles round the orbit is taken advantage of in PAGENSTECHER'S operation for ptosis; subcutaneous ligatures, one or more, are inserted from above the eyebrow to the ciliary edge of the upper lid; this acts like a seton, and forms a band of subcutaneous cicatricial tissue by which the upper lid is rendered movable by means of the occipito-frontalis.

In Bruises of the scalp, extravasation may take place either *into* or *under* the aponeurosis, or thirdly, under the pericranium; these swellings are known as *cephalhæmatomata*. In suppuration *beneath* it, the pus gravitates to the most dependent parts, until arrested by its attachments; and, according to its position, may form a bag bulging over the orbits, the root of the nose, or above the zygoma, or passing down towards the neck behind: fluid blood would also behave in a similar manner. Sometimes it spreads over the whole extent of the head, and yet the scalp does not die because it carries its blood supply with it. (1) Extravasation **into the scalp** may simulate a depressed fracture. Owing to the density of the scalp texture, the extravasation is limited, and forms a circumscribed flattened swelling; the edges feel extremely hard from the coagulation of the blood in the interstitial textures of the scalp, while the centre, where the blood is not yet coagulated, is soft, and gives rise to the supposition that there is a depressed fracture. Further, inflammatory lymph is effused round the edge of the blood clot, and this, with the coagulated blood and granulation tissue, form the hard rim. By firm, downward pressure, however, the unbroken cranial bone may be detected beneath; and besides, the hard edge is not incompressible, sharp, and irregular, but *rounded*, and to a certain extent is compressible, and should be movable over the bone beneath. Further, the firm edge rises gradually, and is itself raised above the level of the bone outside it. In depressed fracture the hard edge is not raised above the bone beyond it, nor can it in the least be indented by the finger

nail. (2) The blood may be effused **under the occipito-frontalis**, and may be either diffuse or circumscribed; as a rule it is diffuse, giving a crackling sensation to the finger, and easily moved from place to place. (3) The blood may be effused **under the pericranium**; this form is most frequently met with in children at birth, and is caused by the pressure of the pelvic bones or by the use of the forceps, and is usually seen over one of the parietal bones. It is firmly fixed to the bone, and is limited by the "sutural ligaments" to the bone over which it commenced; and, further, the scalp should be movable over it. This must also be distinguished from a depressed fracture by the rules already laid down.

Abscesses also may form in the same three positions, and follow the same laws. In making incisions into the scalp in cases of septic cellulitis, in the dangerous area, the position of the various vessels must be kept in mind and carefully avoided: the vessels are — (1) The supra-orbital; (2) the temporal, with its anterior and posterior divisions; (3) the posterior auricular; and (4) the occipital. The ordinary **caput succedaneum**, formed by the effusion of liquor sanguinis from the over-full vessels, is found between the occipital frontalis and the pericranium, in the loose cellular tissue.

The pericranium stands in the place of periosteum to the bones of the skull; but even though it is removed over a considerable area the bone is not so likely to die as when an ordinary bone is stripped of its periosteum, since its nourishment is principally derived from the diploë and dura mater. Further, in cases of necrosis of the bones, it is doubtful whether the pericranium ever forms new bone, and in this way also it differs from the periosteum of other bones. The dura mater acts as periosteum on the other side; it is very firmly attached to the base of the skull, but much less firmly to the vault, and hence it is readily separated in this position by a blow or blood extravasation. The bone is principally nourished by the dura mater (endosteum), and therefore differs in this third respect from an ordinary bone, which is chiefly nourished by the periosteum. Necrosis of the skull is very often syphilitic beginning usually as gummatous periostitis: this is specially common about the forehead—*corona veneris*, or the "mark of the beast," as it is called. Necrosis of the outer table is more common

than the inner, because it is more exposed to injury, and its blood supply is less.

Meningeal Arteries.—(1) In the anterior fossa of the skull we have small branches from the anterior and posterior ethmoidal arteries. (2) In the middle fossa we have—(a) The middle meningeal entering through the foramen spinosum; (b) the small meningeal entering through the foramen ovale; (c) the meningeal branch from the ascending pharyngeal entering through the foramen lacerum medius. (3) In the posterior fossa we have small branches from the occipital and vertebral arteries.

The largest and most important of these is the middle meningeal. It is liable to be ruptured by blows on the temple, producing fracture of the parietal or temporal bones, or great wing of the sphenoid—more especially in the case of the parietal and sphenoid, as it enters the skull through the foramen in the spinous process of the sphenoid, and frequently traverses for a short distance a bony canal *in* the anterior inferior angle of the parietal bone, and here it is very apt to be ruptured. But the various sinuses, especially the lateral, at the base of the cranium are also liable to be ruptured—*e.g.*, hæmorrhage into the orbit and eyelid points to rupture of a cavernous sinus; bleeding from the ear, followed by the discharge of a clear fluid, may be due to fracture of the petrous part of the temporal bone, with laceration of some of the sinuses in that neighbourhood (inferior or superior petrosals and lateral).

The position of the middle meningeal artery—about an inch and a quarter behind the external angular process of the frontal bone, and about the same distance above the zygoma—as well as the structures cut through to reach it, have been already given. (See “Ligature of the Middle Meningeal, vol. i., page 104.)

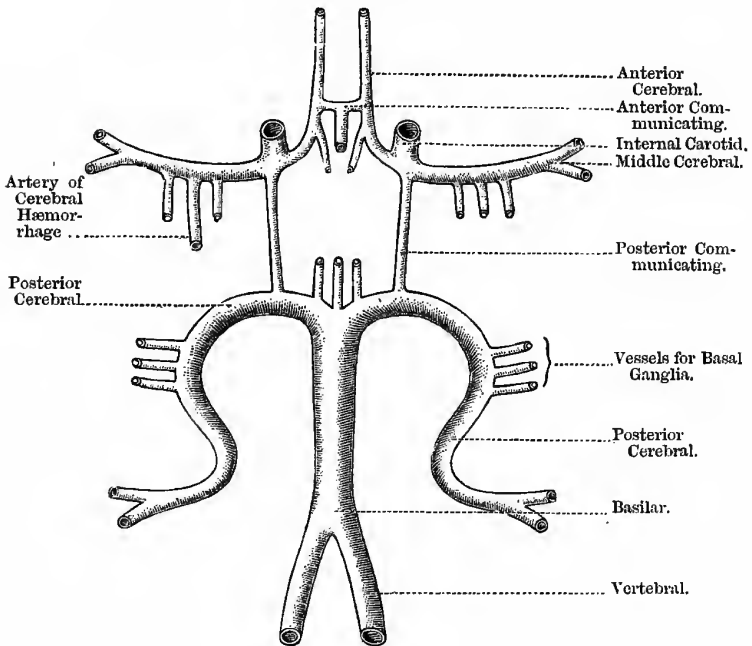
THE BRAIN.

Its Blood Supply (Fig. 142).—The *Circle of Willis* is formed by the union of the internal carotids and vertebral arteries. The vertebrals join at the upper part of the medulla to form the basilar artery, and this again soon divides into the posterior cerebral arteries, from which the posterior communicating pass to join the internal carotids. The internal carotids divide into the anterior and middle cerebrals; the anterior are united by the anterior communicating,

thus completing the circle. From this circle two sets of vessels arise—the *basal* and *cortical* systems. The **Basal** supply the basal ganglia and interior of the brain, do not anastomose freely with each other, and have no communication with the cortical system; they come off as six groups from various parts of the circle, and enter the brain directly at the various perforated spots. Among

Fig. 142.

CIRCLE OF WILLIS.

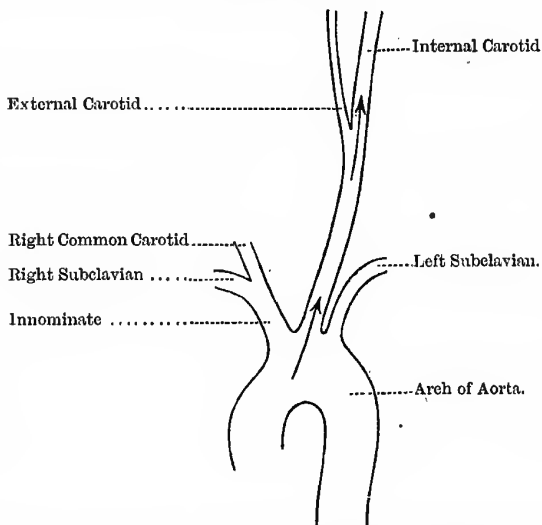


the groups arising from the left middle cerebral is one called by CHARCOT the “artery of cerebral hæmorrhage.” It is larger than the rest, and enters the substance of the caudate nucleus by crossing the upper part of the posterior division of the internal capsule, and is the vessel usually ruptured in apoplexy; it is sometimes misnamed the “lenticular artery,” or the “lenticulo-striate” branch.

The **Cortical** supply consists of the terminal branches of the cerebral arteries, which divide into a very fine plexus in the pia mater, and then enter the grey matter as long capillaries, each supplying a special area. It will be seen, therefore, that the cerebral arteries are "terminal," and when plugged an "infarct" is produced, just as in the kidney and spleen.

Fig. 143.

CEREBRAL EMBOLI.



The arrows indicate how an Embolus more readily passes up the left Common and Internal Carotids to the Brain.

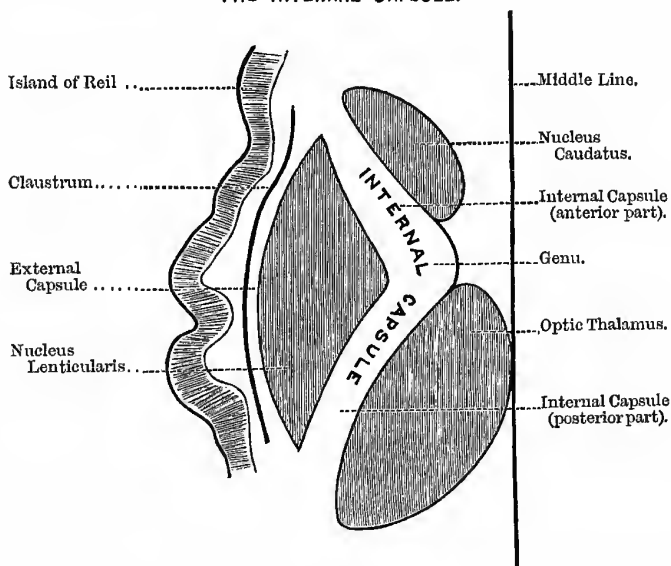
The **anterior Cerebral** supplies—of the *interior*, the frontal lobe and most of the caudate nucleus ; of the *convolutions*, the first and second and the upper part of the ascending frontal. The **middle Cerebral** supplies—of the *interior*, the lenticular nucleus and the rest of the caudate, optic thalamus, internal capsule, and island of REIL ; of the *convolutions*, the third frontal, the lower part of the ascending frontal, the ascending parietal, the superior parietal, the supra-marginal and angular gyri, and the first temporo-sphenoidal

convolution. It will be seen, therefore, that this vessel supplies the most important parts, both inside and on the surface of the brain, including the motor areas, and other parts concerned in apoplexy. The **posterior cerebral** supplies the parts not included in the above list.

Emboli usually pass to the left side of the brain, except in those cases where the clot comes from a right carotid aneurism,

Fig. 144.

THE INTERNAL CAPSULE.



This has been explained by the fact that the left common and internal carotids are almost in a direct line with the first part of the arch of the aorta, and are thus in the direct main stream, and hence the embolus is washed into this vessel rather than the other large branches of the arch (Fig. 143). The arteries of the brain readily burst from disease, because they have no sheath, and the outer coat is thin; in other arteries (except the first part of the aorta), the sheath and outer coat adhere and resist rupture,

The brain is **protected** from the results of external violence in many ways—(1) The density and mobility of the scalp; (2) the arch-like arrangement of the bones, their numerous segments, with the interposed sutural ligaments, and the elasticity of the bones themselves; (3) the mobility of the head upon the spine; and (4) the water pillow on which the brain rests.

The **Internal Capsule** (Fig. 144) is a narrow band of white matter close to the base of the brain, immediately above the crura. It is formed by the fibres of the corona radiata, coming from or going to the grey matter of the cortex; the fibres are collected into a compact band which has a very intimate relation with the basal ganglia. It consists of a posterior part, an anterior part, and a genu. The **posterior part** lies between the optic thalamus and the lenticular nucleus; its posterior third is sensory, its anterior two thirds motor and trophic. The **anterior part** lies between the nucleus lenticularis and the nucleus caudatus; its function is probably concerned with the psychological functions of the brain. The **genu** connects the two parts of the capsule.

THE CEREBRO-SPINAL FLUID.

Its Uses.—It is—(1) Protective, protecting the brain and cord from the effects of violence. (2) It obviates the ill effects of changes in the cerebral circulation, the fluid being displaced when the blood-vessels are over-filled, and returning again when the circulation has resumed its proper equilibrium. In this way the tension is kept equal throughout, for whenever the tension is unduly increased or diminished the effect is the same—viz., convulsions. This is well seen in cases of spina bifida, for when the tumour is pressed upon convulsive phenomena are produced, and in cases where the fluid is drained off either accidentally, by the bursting of the sac, or intentionally, the child dies in convulsions. (3) It has probably a nutritive function. It is found within and around all parts of the cerebro-spinal system, and can readily pass in every direction; thus it fills the subarachnoid space of both brain and cord, and from thence it can pass into the central cavity of the cord and into all the ventricles of the brain, except the fifth. The point of communication is the *foramen of Magendie*, an opening in the pia mater that closes in the roof of the fourth ventricle; the fluid

thus gains the fourth ventricle, and from thence it passes (a) into the central canal of the spinal cord through an opening at the point of the calamus scriptorius, (b) along the aqueduct of SYLVIVS (*iter a tertio ad quartum ventriculum*, or simply the "*iter*"), into the third ventricle, and from thence to the lateral ventricles by means of the *foramen of Munro*. The central canal of the cord, and all the ventricles, except the fifth, are the permanent remains of the ectodermal canal, around which the spinal cord is developed.

Hydrocephalus.—One form of hydrocephalus is believed to be due to the closure of the *foramen of Magendie*, leading to an excessive accumulation of fluid in the ventricles (HILTON) and their consequent expansion. In tapping the ventricles for this condition (*paracentesis capitis*), the needle is entered either through the coronal suture, or some part of the anterior fontanelle, far enough from the middle line to avoid the superior longitudinal sinus.

THE SUTURES.

The **Lambda**, or point of junction of the lambdoid and sagittal sutures, is between two and three inches above the external occipital protuberance; the **Bregma**, is the point of junction of the coronal and sagittal sutures. In infants, these points indicate the positions of the anterior and posterior fontanelles. The anterior is the larger, and is diamond-shaped, having four sides; it should be closed by the second or third year, but remains open much longer in rickets. The posterior is small and triangular, and usually closes soon after birth. The **Sagittal Suture** is found in the middle line stretching between the lambda and the bregma. The position of the bregma is shown by a line drawn vertically upwards from the external auditory meatus to the vertex, when the head is in the ordinary position. The **Lambdoid Suture** is indicated by the upper two thirds of a line drawn from the lambda to the apex of the mastoid process. The **Coronal Suture** is indicated by a line drawn from the bregma to the point where the zygoma joins the malar bone. The **Pterion** is the point where the frontal, parietal, squamous portion of the temporal bone, and the great wing of the sphenoid meet; it is situated an inch and a quarter behind the external angular process of the frontal bone, and the same distance above the zygoma. The **Glabella** is the depression at

the root of the nose, between the nasal eminences. The **Inion** corresponds to the external occipital protuberance.

The sutures are first obliterated at the part in which the ossification of the skull was last completed—*i.e.*, in the neighbourhood of the fontanelles and the sagittal suture, and last in the squamous; the obliteration begins on the *inner* surface of the bones, between forty and fifty years of age; this union between the bones of the skull is known as *synostosis*. A knowledge of this will be of some use in judging the age of a skeleton.

FRACTURES OF THE SKULL.

Fractures of the skull may be divided into those of the vault and those of the base. **Fractures of the Vault** are usually caused by direct violence. They may be divided into—

- | | |
|--------------------|-----------------------|
| 1. Fissured..... | } Simple or compound. |
| 2. Depressed | |
| 3. Punctured | Always compound. |

The inner table is usually more splintered than the external; many reasons are advanced to explain this—(1) The inner table is thin and brittle (*lamina vitrea*); (2) the force is more diffused by the time it reaches the inner table; (3) the bone bends as a whole, and this tends to make the force more diffuse; and (4) there is nothing firm beneath the inner table, and hence the greater splintering, as in driving a nail through a board when there is nothing solid below to oppose the blow. The outer table would be affected in a similar manner were it so placed in regard to the force, as the table furthest from the violence splinters most. In examining the state of the bone, in open wounds of the head, always use a **finger** as the probe. A fissured fracture must be distinguished from sutures or abnormal fissures, as the “parietal fissure,” and from the edge of the torn pericranium. A **fissured fracture** appears as a bleeding, more or less straight, red line, which grates under the finger-nail. A **suture** is not a red, bleeding line, and is not straight, but very zig-zag and serrated. The **edge of the pericranium** is smooth, does not grate under the finger-nail, and shows a slight yielding to pressure. A blunt instrument causes a “gutter” fracture; a round one, like a hammer, a “saucer” or “pond” fracture.

In the young, the condition known as **Craniotabes** must not be mistaken for a depressed fracture; it is caused by hereditary syphilis or rickets, and usually affects the occipital and parietal bones. The bones are thinned in patches, so that they readily yield under the finger.

A **Contusion** of the bones of the head may produce a variety of lesions—(1) It may cause concussion; (2) internal hæmorrhage, active or passive; (3) suppuration between the bone and the dura mater; and (4) cario-necrosis of the injured bone, with its risks, chronic hypertrophy, otitis, causing thickening of the bone and nodulation on its internal surface, giving rise to epileptic or even maniacal attacks.

Occasionally the superior longitudinal sinus may be wounded by pieces of depressed bone being driven into it, and when the bone is removed it is apt to be followed by profuse venous hæmorrhage. To treat this condition a compress of boracic lint should be applied, and held in position by a bandage, for forty-eight hours or so; this will usually permanently arrest the bleeding.

An occasional result of simple fracture of the vault is a traumatic **Cephalhydrocele**. This is a tumour formed by an accumulation of cerebro-spinal fluid beneath the scalp. The fluid in this case is believed by CLEMENT LUCAS to come from the lateral ventricles, owing to laceration of the brain substance, rather than the sub-arachnoid space.

Fractures of the Base.—These are more serious, because they are nearer the vital ganglia and are nearly always compound, and hence the great risk of septic meningitis; for example, the fracture is compound when it passes through the membrana tympani or mucous membrane of the pharynx, the sphenoidal sinuses, and the cribriform plate of the ethmoid, into the nose. They are usually caused by *indirect* violence, as—(1) A blow by a large, soft, heavy body, or a fall on the top of the head, and then a fracture is apt to extend from the part struck through the petrous portion of the temporal bone. (2) Sometimes by a fall on the feet or buttocks by the impact of the spine against the condyles of the occipital bone. (3) By direct violence, as a knife or umbrella driven into the orbit or nose, or a pistol-shot in

the mouth ; in the latter case, the ball will also probably fracture the vault from within outwards. (4) Genuine *contre coup*, where the skull is struck, say on the vertex or sides, fracturing the base, and yet there is no fissure radiating from the point struck. A blow about the root of the nose may fracture the cribriform plate of the ethmoid or the orbital plate of the frontal, and a fall on the chin may force the condyle of the jaw through the middle fossa of the skull (CHASSAIGNAC), or fracture the petrous portion of the temporal (HUTCHINSON). The general signs of fracture of the base are—(1) Long-continued hæmorrhage, (2) escape of the cranial contents, and (3) injury to the cranial nerves. In cases where a severe blow is struck on the head without causing depression of the bone, the effects of *contre coup* are well shown. This is due to the propulsion of the brain against the bone at the opposite point, and contusion of the brain substance is *greater* at this point than just beneath the fracture, though it is contused at both places. Hence, in these cases, the paralysis is always greatest *on the side of the injury*—i.e., the side opposite to the contusion caused by *contre coup* (HUTCHINSON).

In the Anterior Fossa there is extravasation of blood into the orbit, and *under* the conjunctiva and skin of the lid, or possibly bleeding from the nose, *sometimes* followed by the escape of cerebro-spinal fluid ; the blood may come from the meningeal vessels or from the mucous membrane of the nose. In this case the **Structures severed** are — (1) The arachnoid, (2) the dura mater, (3) the cribriform plate, and (4) the mucous membrane of the nose. Should the patient be lying on his back, the blood from the nose may trickle back into the pharynx and be swallowed and afterwards vomited, giving rise to a suspicion of internal injury. When the blood passes under the conjunctiva, it shows that the periosteum lining the roof of the orbital cavity is torn ; as, were it not so, then the blood would only pass into the skin of the lid. In a case of this kind, therefore, the following **parts are ruptured** — (1) The arachnoid, (2) the dura mater, (3) the bone, (4) the periosteum of the orbit. The first and second pairs of cranial nerves may also be damaged ; a common condition is effusion of blood into the sheath of the optic nerve, causing blindness, which gradually passes off as the blood is absorbed. When the

hæmorrhage is beneath the conjunctiva it is of a fan-shaped form, increasing in extent as we pass backwards, and the blood retains its scarlet colour, as the oxygen readily reaches it through that membrane; in these respects it differs from a black eye, for in this condition there is bruising of the superficial textures, and the hæmorrhage is chiefly *in* the skin; whereas, in fracture of the skull, the effusion is into the loose *subcutaneous* cellular tissue, and the escaped blood is seen through the undamaged skin.

In the **Middle Fossa**, the most characteristic sign is bleeding from the ear, followed by the discharge of a watery fluid, as the fracture is usually through the petrous portion of the temporal bone, involving the internal auditory meatus; further, the tympanic membrane is ruptured, as well as the sheath of arachnoid surrounding the facial and auditory nerves in the internal auditory meatus. The **Tissues involved** are—(1) The petrous part of the temporal bone, the fracture involving the internal auditory meatus with the internal and middle ear; (2) the arachnoid; (3) the mucous membrane of the tympanum; and (4) the membrana tympani. If the tympanic membrane is not torn, the blood will pass down the Eustachian tube into the pharynx and probably be swallowed; there will also be more or less deafness. So also in cases of fracture through the basi-sphenoid, the blood is swallowed; take care therefore lest *vomiting* of this swallowed blood mislead the diagnosis. The fluid has the **characters of cerebro-spinal fluid**—very watery and limpid, and therefore of low specific gravity, containing much chloride of sodium, a trace of albumen, the faintest trace of sugar, and is not coagulated by heat or nitric acid. Other possible sources of this fluid have been suggested—a secretion from the mucous membrane of the tympanic cavity, serum from a blood clot, but if so it ought to contain much albumen, the liquor Cotunnii (*perilymph*), or the liquor Scarpæ (*endolymph*). In fracture of this fossa the facial nerve is often implicated, causing facial palsy; other nerves in this region may also suffer—as the auditory, when there will be deafness on that side to the tuning fork applied to the bones of the head.

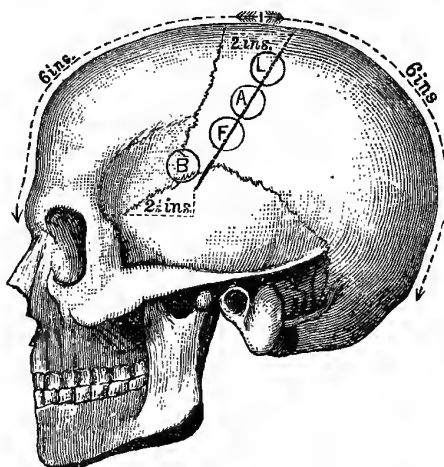
In fracture of the **Posterior Fossa** the signs are very obscure. There may be deep-seated extravasation of blood, producing a yellowish discoloration of the skin some days after the accident.

There will also probably be some tenderness, puffiness, or extravasation about the mastoid process.

Motor Areas.—The motor areas are situated immediately in front of and behind the Fissure of Rolando. This fissure separates the frontal from the parietal lobe (Fig. 145), and runs up not quite parallel with the coronal suture, being from one and a half to two inches behind it at the vertex, but only a little more than an inch at its lower end. According to THANE, the upper

Fig. 145.

FISSURE OF ROLANDO AND MOTOR AREAS.



B. Broca's Convolutions.
F. Face Centre.

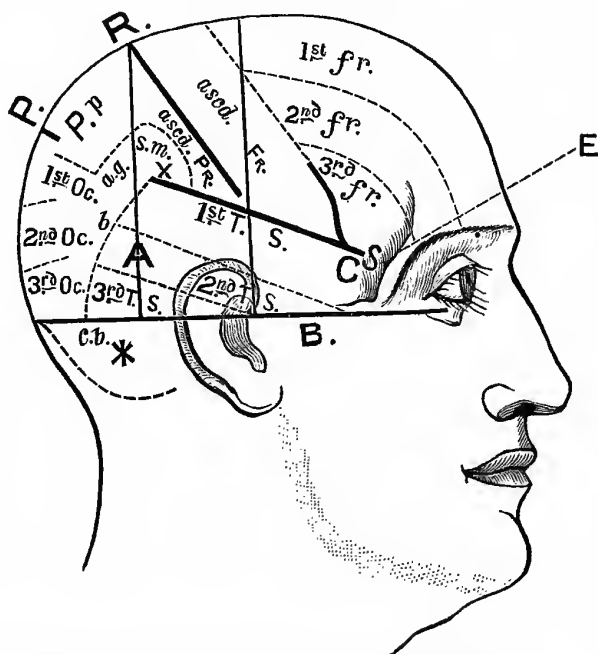
A. Arm Centre.
L. Leg Centre.

end of the fissure of Rolando is placed half an inch behind a point midway between the root of the nose and the external occipital protuberance; its lower end, for all practical purposes, is situated about two and a quarter inches behind the external angular process of the frontal bone. The fissure passes downwards and forwards for about three inches and three-quarters, and, according to Professor HARE, at an angle of sixty-seven degrees to the sagittal suture. On the *left* side, at the lower and anterior part is BROCA'S

convolution (centre for speech), and which may be indicated on the surface by a point two inches behind, and about one inch above the level of the external angular process; 'close to this are found

Fig. 146.

DR REID'S METHOD.



A. Position of the Pus in a case of Mr Barker's.

B. Reid's "Base Line."

C. Position of the Pus in a case of Mr Caird's.

E. External Angular Process.

P. Parieto-occipital Fissure.

R. Fissure of Rolando.

S. Sylvian Fissure.

X. The most prominent part of the Parietal Eminence.

* Point to Trephine for a Cerebellar Abscess.

b. Posterior Boundary of the Temporo-sphenoidal Lobe.

the centres for the tongue and lips. Higher up is the face centre, then the centres for the upper limb, and last and highest of all are found the centres for the lower limb. So therefore, not only are

the centres for the two sides of the body reversed, those for the left half of the body being on the right side of the brain, but they are turned upside down as well. In cases demanding the trephine it is, of course, to be done on the side opposite to that on which the greatest paralysis exists.

Dr Reid's Method for finding the Fissure of Rolando (Fig. 146).—First draw a "base line" from the lower border of the orbit, through the external auditory meatus, to the occiput. Next draw a line from the depression in front of the ear, or the tubercle of the zygoma, to the top of the head, and at right angles to the "base line," and another similar line through the posterior border of the mastoid process; this second line roughly indicates the posterior part of the first temporo-sphenoidal convolution, the others pass still further back. A line is now drawn from the upper end of the posterior line downwards and forwards to the point where the anterior line cuts the Sylvian fissure. As nearly as I can make out, the posterior of the two vertical lines—corresponding to the "posterior border of the mastoid process"—is about an inch and a quarter behind the external auditory meatus.

Lucas-Championnière's Plan.—Find the bregma by carrying a line from one external auditory meatus to the other straight across the vertex: the *upper end* of the fissure of Rolando is 55 mm. behind this; its *lower end* is 7 cm. behind the external angular process, and 3 cm. above it.

NOTE.—25 mm. = one inch, and 5 cm. = two inches, or 50 mm.

The Fissure of Sylvius.—As far as surface-marking is concerned this fissure begins at the *pterion*—a point about an inch and a quarter behind the external angular process, and the same distance above the zygoma—runs obliquely backwards and upwards through the parietal bone to a little beyond, and three-quarters of an inch below, the parietal eminence, ending in the immediate neighbourhood of the supra-marginal and angular gyri. This is the so-called horizontal limb of the fissure, and it separates the frontal and parietal lobes from the temporo-sphenoidal. The ascending limb of the same fissure begins two inches behind the external angular process, runs upwards obliquely towards the vertex, separating the superior, middle, and the inferior frontal convolutions from the

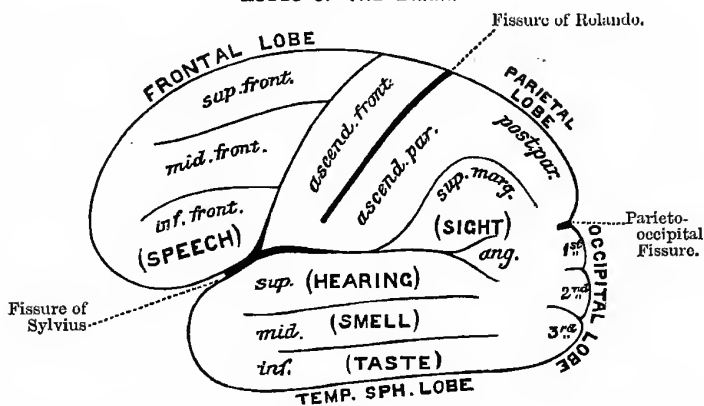
ascending frontal; this limb is almost parallel with the fissure of Rolando, and is usually known as the *pre-central sulcus*. The *intra-parietal fissure* is situated between the ascending parietal convolution and the angular gyrus.

The **Parieto-Occipital Fissure** is from a half to three-quarters of an inch in front of the lambda; it partly separates the parietal from the occipital lobe.

The **Lobes of the Brain**.—The **frontal lobe** is placed in front of the fissure of ROLANDO, and below is bounded by the anterior end of the fissure of SYLVIVS; the **parietal lobe** is bounded in front by the fissure of ROLANDO, behind by the parieto-occipital fissure,

Fig. 147.

LOBES OF THE BRAIN.



and below by the fissure of SYLVIVS. Behind this point is placed the **occipital lobe**, while below the fissure of SYLVIVS lies the **temporo-sphenoidal lobe**; and deep in the fissure of SYLVIVS, hidden by the operculum, is the **island of Reil**. That part of the brain in *front* of the motor areas is believed to be the psychological region, and is therefore beyond the reach of experimental research. The part *behind* the motor areas is, in a general way, the sensory region. The **sight centre** is situated in the *angular gyrus* (FERRIER), or the contiguous occipital lobe (MUNK); the **auditory centre** is in the superior temporo-sphenoidal convolution;

smell in the middle temporo-sphenoidal, and **taste** in the inferior temporo-sphenoidal (Fig. 147). The centres for the **trunk muscles** are placed on the mesial surface of the marginal gyrus, the anterior part being for the neck muscles, the middle for the shoulders, and the posterior part for the muscles below this. The centre for **touch** is said to be placed in the posterior part of the mesial surface of the gyrus fornicatus.

The anterior convolutions of the brain are the most tolerant of severe mechanical injury; they seem to be able to bear the greatest amount of injury without being followed by any bad result. Teaspoonfuls of brain matter have been squeezed out in fractures of this region, pieces of iron driven in for inches, or even driven right through from side to side, and yet the patient recover without a single bad symptom, and with absolutely no change in his mental faculties.

Extravasation of Blood within the Cranium may take place—(1) Within the brain itself, from the bursting of a vessel, or from laceration of the brain substance; (2) in the meshes of the pia mater on the surface of the brain; (3) in the subarachnoid space, where it spreads widely over the surface usually, but it may also remain circumscribed. In the above situations the blood is derived from the vessels of the pia mater or of the brain itself. (4) Between the skull and the dura mater, from wound of a meningeal artery—usually the middle; and sometimes from a sinus—usually the lateral. When the middle meningeal is the source of the bleeding, the clot extends deeply down to the base of the skull, as the blow that ruptured the artery possibly also separated the dura mater from the bone. In this way the effused blood may press on the cavernous sinus, leading to fulness of the vessels of the eye, protrusion of one eyeball, wide dilatation of the pupil, and probably paralysis of some of the ocular nerves; this occurs on the *same side* as the extravasation, and there may also be hēmiplēgia of the *opposite side*, but the widely dilated and insensible pupil is on the same side as the injury (HUTCHINSON).

MALFORMATIONS OF THE BRAIN.

In examining any swelling on the head to ascertain whether it communicates with the cavity of the cranium, find out the

following points:—(1) Is it *fixed* to the bone? (2) Is there an opening in the bone? (3) Is it reducible, wholly or in part? (4) Does it pulsate? (5) Are there any cerebral complications on gentle pressure, or otherwise, such as convulsions or paralysis? (6) Does its tension and size increase when the child cries, or during strong expiratory efforts.

The most important malformations of the brain visible externally are—

1. **Meningocele**, where the protrusion consists of a part of the membranes filled with cerebro-spinal fluid. It is, as a rule, of small size, globular, pedunculated or sessile, fluctuating, and translucent; its tension is increased by strong expiration, and it may be entirely reduced. It is often associated with hydrocephalus.

2. **Encephalocele**, where the protrusion consists of brain as well as membranes. It does not fluctuate, and is opaque, but pulsates along with the rest of the brain, and may be partly reducible.

3. **Hydrencephalocele**, where the protruded brain is distended by an accumulation of fluid within the ventricles; it is very often large, fluctuates, and may sometimes pulsate.

These malformations are believed to be due to intra-uterine hydrocephalus, and not merely to want of development of the bones of the skull. The tumours are soft, rounded, bluish in colour, and covered by thin skin, increase in size when the child cries, and have been mistaken for *nævi*. Several interesting cases are recorded by Mr HUTCHINSON, in his "Illustrations of Clinical Surgery." They are usually found in the middle line, and most frequently at the back of the head, through an opening in the occipital bone, at the junction of the four centres from which the supra-occipital portion is developed; the lower extremities are often ill-developed, and talipes calcaneus is sometimes present. It is also seen at the root of the nose, between the two halves of the frontal bone, from defective ossification of the frontal, nasal, and ethmoid bones: at the anterior and posterior fontanelles, and occasionally at the sides of the skull. When at the anterior part of the skull, they always communicate with the lateral ventricles; those at the sides with the third or lateral, and those in the occipital region with the fourth. In the occipital region—the usual situation—the cavity in the tumour is but a part of the

fourth ventricular, and is lined by a thin membrane covered by nucleated epithelium, partly ciliated—the ventricular ependyma. The cerebellum in such cases is either rudimentary or absent; when any part is present it is the *flocculus* or *subpeduncular lobe*, also called the *pneumogastric lobule*, from being situated behind the pneumogastric nerve. It is also sometimes found at the inner angle of the eye, a little to one or other side, and not exactly central; in this position it is very much more likely to be mistaken for a nævus. It has also been seen in the nose and mistaken for polypus. It may even project through the basi-sphenoid into the pharynx.

The diagnosis depends upon the following points:—(1) That they are congenital and at the seat of some membranous part of the foetal skull; (2) that they fluctuate, as they are liquid in nature; (3) that they increase in volume when the child cries; (4) that they are partly or wholly reducible; and (5) that they partake of the movements of the brain, pulsate, etc.

Such swellings must be distinguished from—

1. **Wens**, which are usually multiple and are fixed to the skin, but may be freely moved over the deeper structures, are not reducible, may not fluctuate, and the bone is unaltered below.

2. **Dermoid Cysts**, which differ from wens, in that they are under the occipito-frontalis, and fixed to the deeper structures (*pericranium*), and there is usually a depression in the bone around its base; the skin can be freely moved over the dermoid cyst. It would be impossible to distinguish between a dermoid cyst and a meningocele, the pedicle of which had become occluded, without using a hypodermic syringe.

3. A **Fatty Tumour** lies in the subcutaneous tissue, is freely movable over the deeper structures, and is not fixed to the skin, except by fragile tags of fibrous tissue; there is also the possible lobulation, and the way in which the rounded edge slips from under the finger, which is quite characteristic.

4. A **Subcutaneous Nævus** is reducible on gentle pressure, without cerebral symptoms, and when reduced the bone can be felt entire beneath it. In cases where it is situated in the tissues over a fontanelle, it is much more difficult to be quite sure of one's diagnosis. In cases of grave doubt one must use a hypodermic syringe, when, if

Meningocele.....	= Clear cerebro-spinal fluid.
Nævus	= Pure blood.
Dermoid Cyst	= Nothing, as the contents are too thick to pass through the needle.

I have said nothing about the histories of the different cases, as the student should always try to arrive at a definite diagnosis from physical examination alone. A meningocele, of course, is always congenital; and a nævus, if not congenital, usually begins about a couple of weeks after birth. Whenever, therefore, there is a *single* tumour on any part of the head, but especially in the middle line, exercise great caution in diagnosis and treatment.

Dermoids of the Scalp.—Dermoids of the scalp are often attached to the dura mater. Mr SUTTON explains this by stating that early in embryonic life the dura mater and the skin are in contact, and that the skull-bones are developed between these two layers at a later period, and should be looked upon, therefore, as secondary cranial elements. The usual situations for cranial dermoids are the anterior fontanelle, the root of the nose, and the external occipital protuberance, and they are apt to be confounded with sebaceous cysts, or with meningoceles. When over the anterior fontanelle, the tumour is exactly like a meningocele, rising and falling with regular pulsation, and apparently filling out when the child cries or coughs.

The Head in Rickets.—In this condition—(1) The anterior fontanelle remains open for a long time—to the third or fourth year; (2) the bones are thickened, especially near the sutures; (3) the antero-posterior diameter is long; (4) the forehead is high, square, and projecting; (5) the bones of the face are ill-developed, hence the face is often small, while the head is large; and (6) the teeth are developed late, and are apt to fall out.

In **Congenital Syphilis**, periosteal deposits of new bone are often found upon the four processes that bound the anterior fontanelle. Such deposits are known as **Parrot's nodes**, or **Osteophytes**, and they give to the anterior part of the skull a peculiar natiform appearance. The new bone is at first very spongy and vascular, but by-and-by becomes more compact. These osteophytes usually develop between the sixth and twelfth months. Sometimes also we find atrophic patches—**Craniotabes**.


TREPHINING.

This operation should not be performed over the course of the sinuses, nor in situations likely to wound the middle meningeal artery. A line drawn over the head, from the root of the nose to the occipital protuberance, indicates the course of the *superior longitudinal sinus*; and the posterior two thirds of another line, drawn from the same protuberance to the external auditory meatus, indicates the course of the horizontal portion of the *lateral sinus*; and about the middle of this line the pulsations of the occipital artery may be felt (HOLDEN).

The position of the middle meningeal artery must also be avoided, unless trephining in this situation be indicated for special reasons (see vol. i., page 103).

Fig. 148.

HEY'S SAW.



Properly speaking, "trephining" should only be applied to cases where a complete circle of bone is removed from the skull by the trephine, though it is usual to speak of elevating depressed fragments, removing small angles of bone with HEY'S saw (Fig. 148), etc., as "trephining." "Trepanning" is an operation seldom, if ever, performed now. In this the bone was removed by a trephine head, worked in the same way as a carpenter's boring brace.

Instruments required.—Scalpel, trephines, dissecting forceps, catch forceps, a brush to clear away the sawdust, director, fine hypodermic syringe or GRAEF'S cataract knife, a quill, HEY'S saw, elevator, "lenticular," raspatory, sponges, ordinary and silver drainage tubes, etc.

Cautions.—The chief points to be attended to are—(1) To avoid the course of sinuses and arteries, and also sutures, because veins very often pass through at or near sutures. (2) To work the trephine very cautiously, as one can have no idea of the thickness of the skull—it may be very thin or very thick, or one side thick, the other thin; the rule Mr CHIENE gives is, to trephine just as if the skull in question were the thinnest skull ever seen, and thinner in one half of the circle than the other. (3) The pericranium must be preserved. The old way was to make a crucial incision through everything right down to the bone at once, and then turn back the flaps. At the present time a V- or horse-shoe-shaped incision is usually employed; the flap must be made in such a way that the blood-vessels are cut where they are smallest—*i.e.*, the convexity of the horse-shoe must be towards the saggital suture, so that the trunks of the arteries are in the base of the flap. (4) The circle of bone must be sawn completely through before it is removed, or a sharp splinter is left on the inner edge, which is difficult to remove, and which if not removed will set up inflammation of the membranes. The centre pin of the trephine is made to project, and fixed by the screw at one side for that purpose; it is then applied to the denuded bone, into which the centre pin is at once pressed, so that it may fix the trephine head till it has made a groove for itself. It is rotated alternately from right to left, until the groove is sufficiently deep to hold the crown, when the centre pin must be withdrawn. The groove is to be cleared out from time to time by a small brush, and measured by a quill or probe to see if it is of the same depth all the way round. When the diploë is reached the sawdust will be tinged with blood, and then the operator must be specially cautious. With the view of avoiding wound of the dura mater, some operators recommend a conical-crowned trephine.

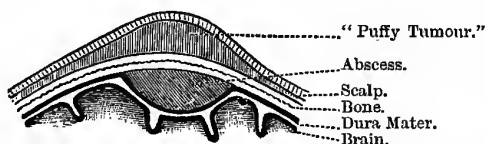
When to Trephine.—No exact rules can be laid down for all cases; each case must be judged on its own merits. The following rules (after SPENCE) may be taken as fairly typical and trustworthy:—(1) *At once*, in all cases of distinct punctured fracture. In these cases the fracture is, of course, always compound, and we know that the inner table is much broken up, probably into a number of loose, sharp-cornered fragments, which are *sure* to

set up mischief if left, which will necessitate their removal at a later period under less favourable conditions. Very often, also, the dura mater is wounded by the instrument causing the fracture, or else a sharp specule of bone is driven into it. The trephining in this case is *not* to relieve compression. (2) *At once*, in cases of compound comminuted depressed fracture, in the *adult*—not in cases of mere fissure with wounded scalp. In the *child*, wait for symptoms. (3) In simple depressed fracture, try other means first, and only trephine when the symptoms of compression are urgent and persistent. By following this plan we avoid unnecessarily transforming the simple into a compound fracture. (4) In compression due to extra-meningeal hæmorrhage, when its position can be diagnosed—by the existence of a fissured fracture over the course of the middle meningeal, for example. (5) In compression

Fig. 149.

POTT'S PUFFY TUMOUR.

(After SPENCE.)



due to suppuration, if the seat can be diagnosed, as from the previous existence of suppuration of the middle ear, or from the presence of POTT's "puffy tumour," or unhealthy state of a scalp wound, the edges of which become everted and retracted, leaving the bone discoloured at the bottom of the wound, and the discharge becomes thin and gleetly. POTT's tumour is merely a boggy infiltration or flattened swelling under or in the scalp tissues, but there is no well-marked "tumour;" if present, it will be of assistance in cases where the scalp is not wounded (Fig. 149). It indicates suppuration between the bone and the dura mater. (6) In cases of epilepsy or local paralysis, due to some local injury, such as a contusion; in these cases the existence of an old scar may guide. In trephining in cases of epilepsy of non-traumatic origin, it probably matters but little what part of the vault of the skull be removed, as any opening thus made will act as a safety valve,

or fontanelle, in times of extra pressure in the contents of the cranium. In connection with this, it is interesting to observe that for some time after birth the anterior fontanelle actually *increases* in size; this is no doubt due to the very rapid growth of the brain during this period of life, and probably acts as a safety valve, preventing convulsions. (7) In tumours of the brain, if their seat can be diagnosed.

Compression differs from **Concussion**, in that there must always be a palpable lesion in the former; whereas, in concussion there is no palpable lesion—the changes being probably circulatory. The symptoms come on at once, and are much more evanescent than in compression. If compression is produced **at once**, it is due to depressed bone; if it comes on **in a few hours**, it is due to hæmorrhage; if later—**ten to twelve days**—it is due to the effects and products of inflammation. Hæmorrhage may either be—(a) *active*, coming from the arteries; or (b) *passive*, from venous sinuses; in the latter case, it is very much slower and more insidious in its onset than when it comes from an artery.

Tumours of the Brain.—The usual signs of brain tumour are—(1) Fixed, persistent, and often intense pain (*cephalgia*), especially when near the surface of the brain; (2) sometimes severe giddiness; (3) irritation of motor or sensory functions, or of the special senses; (4) optic neuritis (“*choked disc*”); (5) vomiting is a common symptom; and (6) alteration in the size of the pupils. The evil results arise—(a) From displacement of parts, (b) from interference with the functions of the neighbouring parts of the brain, (c) from irritation of parts, followed by inflammation and degeneration, as a direct result; or (d) from interference with the cranial contents, generally from the increased intra-cranial pressure. Should the tumour be seated in or near the **medulla**, we may expect polyuria and diabetes mellitus, or interference with the heart and respiration; if it is in the **cerebellum**, affections of co-ordination and equilibrium, with a staggering, drunken-like gait. When a tumour, *e.g.*, a glioma, affects the **cortical centres**, epileptiform seizures are common, and the fit begins by *spasm* of the part in connection with the centre implicated. These spasms, or occasionally paresis or paralysis of certain parts, indicate the part of the cortex affected and the point at which the trephine

should be applied, *e.g.*, a tumour about the centre of the right fissure of Rolando will probably cause spasm, paresis, or paralysis, of the left upper extremity; when the posterior part of the lower half of the **pons** is affected, we meet with *alternate hemiplegia* or *crossed paralysis*—*i.e.*, the facial is paralysed on the same side as the brain lesion, while the body is paralysed on the opposite side; in lesions of the upper lateral half of the pons, the facial is on the same side as the body paralysis, and both are on the side opposite to the brain lesion. When the **crura cerebri** are affected, we find simultaneous paralysis of half of the face and body, on the side opposite to the brain lesion, but paralysis of the third nerve (*motor oculi*) on the same side as the brain lesion.

THE THYROID GLAND.

In man, this is a *ductless* gland, situated at the upper part of the trachea, and consists of two lateral lobes and the connecting isthmus; the isthmus joins the lower third of the lateral lobes, and usually covers the second, third, and fourth rings of the trachea. Each lobe extends from the fifth or sixth ring of the trachea to the side of the thyroid cartilage; the right lobe is a little longer and wider than the left. There is sometimes a conical third lobe, called the *pyramid*, arising from the left side of the isthmus, or from the left lobe, and ascends as high as the hyoid bone. The whole gland is rather larger in females than in males, and is slightly increased during menstruation; the right lobe is slightly larger than the left. Some muscular bands are said, by SÖMMERRING, to pass from the body of the hyoid bone to the upper part of the isthmus, forming a muscle called the *levator glandulæ thyroideæ*.

In all the vertebrata the thyroid body arises, as one or more diverticula, from the ventral wall of the pharynx, or floor of the mouth; in a few of the lowest forms it retains its connection with the pharynx, but in the higher forms this communication becomes shut off, and the duct rendered obsolete. In man and other higher mammals this communication is represented in the embryo, and the passage—first detected by HIS—is known as the thyreo-hyoid, or the thyreo-lingual duct. On the appearance of the hyoid bone, the duct becomes divided; the segment in relation with the tongue is the lingual duct, whilst that which retains its connection

with the thyroid is the thyroid duct, more commonly known as the "processus pyramidalis," and as it is often surrounded by muscular tissue, is frequently described in anatomical text-books as the "levator glandulæ thyroideæ." The lingual duct is sometimes present in the adult, and extends from the foramen cæcum on the dorsum linguæ to the hollow of the hyoid bone. Should both ends become closed, it will give rise to a lingual dermoid; it may also give rise to tumours structurally resembling the thyroid gland—thyroid dermoids, or the congenital adenomata (BLAND SUTTON).

Relations.—**Anteriorly**—The integumentary structures and deep fascia, and the sterno-hyoid, sterno-thyroid, and omo-hyoid muscles. **Laterally**—The sheath of the carotid vessels. **Posteriorly**—The trachea and larynx and the lower part of the pharynx, and on the left side the œsophagus also.

Structure.—It consists of a capsule of connective tissue, from which, as usual, septa pass off into the interior of the organ, dividing it up into lobes and lobules; numerous blood-vessels and lymphatics ramify in the septa. Each lobule consists of a number of closed vesicles closely surrounded by a kind of vascular connective capsule, derived from the septa; each vesicle is lined by a single layer of epithelial cells, and contains a viscid, homogenous, semi-fluid, slightly yellowish, or bloody material, in which are found red blood corpuscles in all stages of disorganisation and discoloration.

Vessels.—The thyroid gland is a very vascular structure. Its **Arteries** are the superior and inferior thyroids, and sometimes the *thyroideu media* or *ima*, which arises from the innominate, or the arch of the aorta, and passes up in front of the trachea. The arteries are very large, and anastomose with great frequency. The **Veins** form a plexus round the gland and on the front of the trachea, from which plexus the superior, middle, and inferior thyroid veins arise; the superior and middle end in the internal jugular, the inferior in the innominate vein. The superior crosses in front of the upper part of the common and the lower part of the external carotid, the middle in front of the lower part of the common carotid, and the inferior in front of the trachea; they must, therefore, be carefully looked for and secured, in ligature of these arteries, and in the low operation of tracheotomy. The **Nerves** are derived from the pneumogastric, and from the middle

and inferior cervical ganglia of the sympathetic. The various forms of enlargements to which this gland is subject, commonly go by the name of—

Bronchocele or Goitre.—**Varieties**—All forms begin as a simple hypertrophy of the gland substance, but during its progress one or other constituent increases out of proportion to the others. (1) *Simple Bronchocele*, where all the parts of the gland remain equally affected; (2) *Cystic Bronchocele*, where the vesicles are principally affected; (3) *Fibrous Bronchocele*, where the interlobular fibrous tissue undergoes great increase; (4) *Pulsating Bronchocele*, where the arteries are very much enlarged and pulsate; this variety, when associated with protrusion of the eyeballs (*proptosis oculi*), is known as *Exophthalmic Goitre* (GRAVES'S or BASEDOW'S disease). The above forms are associated with the usual signs of anæmia, as pallor, palpitation, bruits of debility, both cardiac and vascular, dyspepsia, and menstrual troubles. There are, however, other two forms of enlargement—(a) From malignant disease or *Malignant Bronchocele*, which always follows one or other of the chronic forms of bronchocele already mentioned; carcinoma occurs more frequently than sarcoma. (b) There is an *Acute Bronchocele* which may cause death from asphyxia in a few days or weeks; it is usually found in adolescents. In this country goitre is most common in Derbyshire, and has, therefore, been called the "*Derbyshire neck*." When goitre is associated with idiocy it constitutes the condition known as "*Cretinism*."

Diagnosis.—The cystic and pulsating varieties must be diagnosed from carotid aneurism or other swellings of the neck; the position, shape, and attachments will help, but the most characteristic diagnostic point is to ask the patient to swallow when the thyroid body will move with the larynx and trachea during that act. In pulsating bronchocele too, the isthmus is always affected more or less, and the swelling is, further, more fixed towards the trachea or middle line, whereas a carotid aneurism is most firmly fixed under the sterno-mastoid. For the different varieties, diagnose on general principles: the fibrous form is most likely to give rise to pressure effects—*e.g.*, on the trachea and both superior laryngeal nerves; if the bronchocele be one-sided, it is practically always the cystic variety; the vascular form affects both sides more or less.

Treatment.—BLAUD'S pills for the anæmia; change to higher, drier, and more airy dwellings; iodine or the iodides, both internally, and externally, in the form of ointments, well rubbed in, in front of a good fire, or in the sun's rays. For the **Simple** form, try medical treatment first; only excise the gland if there be great dyspncea and dysphagia. For the **Cystic**—tap and draw off the fluid, and inject iodine; the fluid is usually like coffee-grounds. The **Fibrous** treat as the simple variety. For the **Vascular** forms, try medical treatment first; and if this fail, then use electrolysis (DUNCAN). Ergot and ligature of the thyroid arteries have also been tried for this form.

Excision of the Thyroid (WATSON).—Make a free mesial incision down to and through the deep fascia of the neck. It will be safer to divide the deep fascia on a flat director. Do *not* divide the areolar tissue surrounding the gland, which is a prolongation of the cellular tissue sheaths of the arteries supplying it, and if this be torn through it will be impossible to secure the vessels, as they are so brittle; the capsule of the gland itself must also be left undisturbed, otherwise, if it be opened, there will be excessive hæmorrhage. After the deep fascia of the neck is divided the muscles are drawn aside and the gland exposed well all round. The vessels must now be secured. The four arteries enter at the four corners, but the veins leave on every side, except the upper edge; all vessels must be secured within their sheaths with double ligatures, passed by means of an aneurism needle. Pass all round the gland, taking up the tissue in bundles, and tying it *en masse*; after this divide the tissue between the two ligatures, open the areolar tissue surrounding the capsule of the gland, carefully snip through all other attachments with blunt-pointed scissors, securing any vessel as you proceed, and remove the gland entire in its capsule, taking special care lest there be adhesions to the internal jugular vein. Other methods are—Excision of one-half of the gland, and excision of the isthmus, with the hope that the gland will then atrophy. LISTER also scoops out a part of the gland by means of a large, sharp spoon, through an incision near the edge of the sterno-mastoid; the gland is opened by PAQUELIN'S cautery, and the spoon introduced. The bleeding is restrained by pressure.

When **Acute Bronchocele** gives rise to serious symptoms, three courses are open to the Surgeon—(1) To perform the low operation of tracheotomy; (2) division of the sterno-hyoid, sterno-thyroid, and omo-hyoid muscles, as they bind the gland down and press it against the trachea (BONNET); (3) division of the isthmus for the same purpose, to remove the pressure from the windpipe (GIBB).

Clinical Relationships.—The relation of the thyroid gland to—(1) Cretinism, (2) Myxœdema, (3) Acromegaly, and (4) to certain bone diseases, is well worthy of the student's attention.

1. **Cretinism** has been observed as a sequel to excision of the gland.

2. **Myxœdema** (ORD) has also been frequently observed, by KOCHER and others, as a sequel to the same operation. In this disease the connective tissue, especially of the hands, feet, and face, become swollen, waxy-like, and rounded in outline; it seems that the constituent gelatine and chondrine revert to the embryonic type, and become transformed into mucin or mucous tissue. There is a gradually increasing debility, harsh dry skin, large baggy swellings in the supra-clavicular regions; the intellect becomes dulled, the circulation sluggish, thought and speech, and all the mental faculties become slow; the eyelids become thick, heavy, swollen, and transparent; the hands spade-like, and the expression of the countenance idiotic; and the patient may even become insane. To avoid this unfortunate result, it has been advised that the isthmus alone be removed, and in many cases its removal has been followed by atrophy of the lateral lobes. The œdema in this affection differs from ordinary dropsy, in the fact that it is not necessarily found in the most dependent parts, and that the swollen parts do not pit on pressure. It is most frequently found in women of middle age; the usual change in the thyroid consists in the substitution of delicate fibrous tissue for the proper glandular substance. The Myxœdema Committee believe that it is the same disease as that named *Sporadic Cretinism* affecting children, and probably identical with *Cachexia Strumipriva* of KOCHER, and also closely allied to the "cretinoid condition" of GULL. It is quite probable that the gland has a *trophic* function; in its clinical relationships it seems to resemble the supra-renal capsules.

3. **Acromegaly** (*acromégalie*) seems to have some obscure relation to affections of this gland. At first sight this affection seems to resemble myxœdema, but is widely different. The lower jaw becomes very much enlarged, so that the face becomes egg-shaped, with the large end downwards; the cartilages and bones of the nose, the cartilages of the eyelids and ears, are much enlarged, the lower lip thick and everted, but the *long bones* are rarely affected. The disease has received its name from the characteristic and gigantic enlargement of the head, hands, and feet, but there is no swelling or œdema of the soft parts. In women, menstruation usually ceases early in the course of the disease. The cause of the enlargement is found in *an overgrowth of the bones themselves*, and thus differs from myxœdema, where the soft parts alone are affected; the lower jaw and cheek bones are specially affected. In acromegaly we may, however, find other curious changes besides alterations in the thyroid—viz., enlargement of the hypophysis cerebri (*pituitary body*), and persistence and hyperplasia of the thymus. The enlargement of the pituitary body may cause pressure upon, or even destruction of the optic commissure. It will also be remembered that this little body has a very curious developmental history, and that it is constant and uniform through all the vertebrata; it is formed by two outgrowths, one from the brain, the other from the epiblast of the back and upper part of the future mouth.

4. It has been noticed that in many cases of **Malignant Disease of the Thyroid**, secondary growths are specially apt to occur in the bones, these growths having the same general style of structure as the thyroid gland itself; indeed, it would seem that a simple enlargement of the thyroid, when associated with other growths of a malignant nature, in the bones and viscera, is able to stamp them with its own peculiarity of structure (HUTCHINSON).

THE PAROTID GLAND.

This gland fills up the hollow between the mastoid process and the sterno-mastoid muscle behind, and the ascending ramus of the lower jaw in front. **Boundaries.**—**Above**, it extends as high as the zygomatic process; **below**, it is bounded by a line passing from the angle of the lower jaw to the anterior border of the sterno-mastoid

muscle; **behind**, by the external auditory meatus, pinna, mastoid process, and sterno-mastoid muscle; **anteriorly**, it stretches over the masseter muscle, and from this part the duct emerges. The **deep surface** of the gland extends to the styloid process, passes beneath the mastoid process and sterno-mastoid muscle; it also fills up the hollow behind and below the articulation of the lower jaw, and further, passes to the great vessels in this region. The gland is invested by a dense fibrous sheath, derived from the deep cervical fascia; it is very dense on the outer and lower aspects of the gland, but on the upper and deep aspects it is very thin, and between the styloid process and the external pterygoid muscle it is absent altogether. Abscesses therefore tend to pass upwards towards the temporal or zygomatic fossæ, or inwards towards the pharynx, rarely passing outwards or downwards. Pus may also make its way from the pharynx outwards to the parotid region, or down from the temporal fossa. The **deep surface** of the gland has a very close relation to the cartilaginous part of the external auditory meatus, the ramus of the lower jaw, and the temporo-maxillary articulation, as well as the great vessels and nerves of the neck—the internal carotid artery, the internal jugular vein, the vagus, the glosso-pharyngeal, the spinal accessory, and the hypoglossal nerves. It has a close relation also to the foramen ovale and the exit of the third division of the fifth nerve, so that pus has been known to pass from the parotid region into the skull along this nerve (VIRCHOW).

Tumours and Abscesses of this gland give rise to much pain because of the dense unyielding fibrous capsule of the gland, and, therefore, should be relieved early by incision (in the case of abscess), or excision (in the case of tumours). The relation of the gland to various important vessels and nerves must be kept in mind:—(1) The external carotid enters the deep surface of the gland, and gives off in it the following branches:—(a) Occipital, (b) posterior auricular, (c) temporal, and (d) internal maxillary. (2) Passing from the gland is the external jugular vein, formed in the gland by the union of—(a) The temporal, (b) internal maxillary, (c) posterior auricular, and (d) transverse facial veins. (3) The auriculo-temporal nerve enters the gland at its lower and posterior part, and the facial nerve passes through the gland and

leaves it by its upper, anterior, and lower borders. The order from the surface is—nerves, veins, arteries. Paralysis of the facial nerve is a not uncommon result of tumours in this region; it is specially common in *malignant* tumours, but not in innocent; some even use this as a diagnostic difference between simple and malignant tumours. The difference is probably due to the rate of growth in the two cases. But, further, the deep surface of the gland is in relation with the internal carotid artery, and internal jugular vein. Parotitis and abscess have frequently been found after injuries of the abdomen and pelvis; the cause is not known, though some have suggested that it is probably pyæmic in nature. In operations about the gland for the excision of tumours or the opening of an abscess, the knife should not be entered behind a line drawn from the condyle to the angle of the jaw, lest the external carotid artery should be injured; and, to avoid wounding the trunk of the facial nerve or the chief branches of the “*pes anserinus*,” the incisions should be made as far as possible parallel with the main trunks—*i.e.*, the knife must be held horizontally, and the gland at the same time be drawn well forwards. The facial is the motor nerve of the muscles of expression, and its division gives rise to paralysis of these muscles; hence the importance of preserving it from injury. Abscesses, however, in this region are best opened in the way introduced by the late Mr HILTON—an incision is made through the skin and deep fascia only, near the angle of the jaw, and then a director is pushed on into the cavity of the abscess; that the director has reached the abscess is indicated by the fact that the point is free, or else by the escape of pus along the groove. Then a pair of dressing forceps are passed along the director, closed, and when they have entered the cavity the director is taken out and the blades of the forceps are then opened, and the instrument withdrawn. As elsewhere, the opening must be dependent for the purposes of drainage. In connection with abscesses in this region, it should be noted that there are a few lymphatic glands deeply placed in the substance of the parotid, and which receive lymphatics from the nasal, temporal, and orbital fossæ, and from the mucous membrane of the pharynx and mouth. Irritation in these parts, therefore, may readily be the starting point of a parotid abscess.

DERMOID GROWTHS.

Definition.—Dermoids* are cysts or tumours, furnished with skin or mucous membrane (which may or may not be accompanied with the appendages peculiar to these structures), occurring in situations where skin and mucous membrane are not normally found (J. BLAND SUTTON). The simple cystic forms contain a porridge-like material composed of sebum, cholesterine, and shed hairs, and are lined with skin, *e.g.*, at the outer angle of the eyebrow. Complex forms may contain, in addition to hair and skin, muscular fibres, teeth, nails, and masses resembling mammae. Dermoids are apt to arise in situations where, during embryonic life, coalescence takes place between two surfaces covered by epiblast—as in the middle line, where the two halves of the body join. Such a line may be indicated by starting at the root of the nose and drawing a line to the external occipital protuberance, then along the mid line of the back to the coccyx, then through the perineum, scrotum, and penis, upwards through the umbilicus, thorax, and neck to the symphysis menti; also along the median raphé of the palate. They also occur in the lines of the various secondary fissures of the face and neck (see vol. ii., page 44); in such cases the dermoids will not be situated in the middle line. They may also be produced on any other part of the body by implantation of epithelium under the skin, as in punctured wounds—*e.g.*, on the limbs, fingers, iris, etc.—“implantation dermoids.”

Another group of dermoids has its origin in connection with obliterated embryonic canals and ducts—usually in, or in connection with, some part of the primitive alimentary canal, and are most commonly found near the coccyx, the tongue, and the neck. They may be found in the pharynx, hanging from the soft palate or roof of pharynx, and also in the rectum. Of such a nature, in all probability, are the congenital sacro-coccygeal tumours. “It is an interesting fact that the six obsolete canals existing in the embryo of a mammal—viz., the infundibulum (of the brain), the neuro-enteric passage; the post-anal gut, the cranio-pharyngeal canal, the thyreo-lingual duct (duct of the thyroid body), and the

* For a full account of Dermoids, see an exceedingly able and interesting series of lectures by J. Bland Sutton, F.R.C.S.

duct of the yolk sac, should all have direct relation with the alimentary canal, and each be directly associated with dermoids often of considerable complexity, and with a peculiar form of tumour identical in structure with the thyroid body" (SUTTON). For this reason such tumours are sometimes known as "congenital adenomata," or "thyroid dermoids"—*e.g.*, congenital sacro-coccygeal tumours.

EXCISION OF THE TONGUE.

This operation may be performed in several ways—

- (1) From the inside of the mouth, without any external incisions.
- (2) By incisions below the jaw (submental, or REGNOLI'S method).
- (3) By section of the lower lip and jaw (SÉDILLOT'S method).

Instruments required.—Scalpel, a broad-pointed pair of dissecting forceps, an extensive stock of WELLS'S or PÉAN'S forceps, a gag, a bone drill, copper retractors, blunt hooks for ligature of the lingual; tooth forceps for incisor teeth, in cases where the jaw is to be divided; a narrow-bladed, movable-backed saw; stout silk thread to pass through tip of tongue; copper or silver wire to suture the jaw, "key" to tighten the same; wire-cutting pliers, scissors of various kinds (one pair curved and blunt-pointed); ligatures of catgut and silk; solution of chloride of zinc, collodion to close incision after ligature of lingual; small sponges on sticks, special sponge holders, or on PÉAN'S forceps; TRENDELENBURG'S trachea "tampon," or some other means to prevent blood passing down to the lungs; instruments for tracheotomy; HIGGINSON'S syringe, lint, bandages, needles, chloroform; two strips of bandage to fasten round and separate the divided jaw. HAHN'S trachea tube may be used instead of TRENDELENBURG'S. It resembles an ordinary tracheotomy tube, but round the outer tube is a sheath of compressed sponge. When it is introduced the natural moisture in the trachea causes the sponge to swell, which thus completely blocks up that tube. The sponge requires ten or fifteen minutes to swell sufficiently. It is better, at the same time, to plug the pharynx with a sponge, lest blood should soak past the tube. The inner part of HAHN'S tube is prolonged and bent downwards, in order that the chloroformist may be out of the operator's way.

1. From the inside of the Mouth.—The patient is gagged and the tongue is secured with a piece of whip cord, and drawn well forwards and upwards. Then, by means of a strong curved pair of scissors, cut through—(a) the frænum linguæ; (b) insertions of genio-hyoids; (c) insertions of genio-hyoglossi muscles, and cut well back so as to set free the base of the tongue, dividing (d) the palato-glossus; then cut (e) the reflexion of the mucous membrane on the floor of the mouth from the lower jaw. Free the base of the tongue with the fingers and draw it well forwards, and apply the wire *écraseur* and gradually remove the organ. If the anterior pillar of the fauces be in the way it may be cut across. If one half of the tongue is to be removed then two *écraseurs* must be used; or, better, after the base of the tongue is freed, then by means of a sharp-pointed bistoury transfix the tongue at the posterior part, from below upwards; and then cut accurately along the middle line to the tip, and apply the *écraseur* at the base of the half to be removed.

Whitehead, of Manchester, removes the tongue through the mouth with the scissors alone. The patient is gagged as before, and the gag committed to the care of an assistant. Then a double ligature is passed through the tongue one inch from its tip, and given in charge to a second assistant who has to make steady traction upwards and outwards during the whole of the operation. Another assistant must be prepared to keep the mouth and throat free from blood by means of sponges.

Instruments required.—Sponges and holders, scissors, WELLS'S forceps, a handled needle threaded with stout silk, and carbolised silk ligatures. The operator then divides all the attachments of the tongue to the jaw and pillars of the fauces with a pair of ordinary straight scissors. The muscles forming the base of the tongue are next to be cut across by a series of short snips, with blunt-pointed scissors, as far back as the safety of the epiglottis will permit. Bleeding vessels are seized and twisted or tied as soon as exposed, and lastly, a loop of silk is passed through the glosso-epiglottidean folds of mucous membrane as a means of drawing forward the floor of the mouth in the event of secondary hæmorrhage: this ligature may be removed on the second day. By the combination of short snips with the scissors, the tongue being pulled forward all the

time, the small vessels can be seen and secured at once, and the large ranine exposed and secured before it is divided; further, by this method the ranine artery is only divided at the end of the operation. Where the whole tongue is to be removed, it is better to split it, pass two ligatures through the tip, and pull forward and excise one half at a time.

The Structures divided are—(1) The mucous membrane; (2) genio-hyoids; (3) genio-hyoglossi muscles; (4) part of the submaxillary gland with vessels and duct, though the gland may be pushed aside; (5) the palato-glossus muscle; (6) hyoglossus; (7) styloglossus; (8) intrinsic muscles of the tongue; (9) glosso-epiglottidean folds of mucous membrane; (10) lingual vessels; (11) lingual and chorda tympani nerves; (12) hypoglossal nerve, and, perhaps, part of the glosso-pharyngeal. One-half of the tongue may be removed in the same way, after having first split it in the middle line with a bistoury. Mr WHITEHEAD, however, does not split the tongue nor does he perform a preliminary laryngotomy. The advantages of a preliminary laryngotomy are two-fold—(1) It effectually prevents blood entering the trachea, and (2) the patient may be allowed to breath through the opening for some days till the wound has begun to granulate or is well on the way towards healing. In this way the usual cause of death—septic pneumonia—is to a great extent prevented. The causes of septic pneumonia are two-fold—blood-entering the air vesicles, and the inhalation of septic organisms from the floor of the mouth; but with a preliminary laryngotomy both these may to a great extent be prevented.

The patient must be fed for a time by nutrient enemata, and the mouth washed out very frequently by a warm solution of boro-glyceride or boracic acid, and the floor of the mouth covered with a layer of impalpable boracic powder—a method introduced by Mr DUNCAN,—the patient in the meantime breathing through the tracheotomy tube. By this means the wound is kept aseptic, and the risk of inhaling septic organisms is lessened, and the great cause of death avoided—septic pneumonia. Later, he may be fed through a tube. In operations on the tongue the only serious immediate danger is hæmorrhage from the divided linguals. The vessel may be compressed from the mouth by passing the forefinger over the dorsum of the tongue till it touches the epiglottis; it is

then turned towards the side on which the artery is to be compressed and hooked forcibly up against the jaw. The lingual artery may also be ligatured at the beginning of the operation. The incision thus made may be utilised to remove suspicious sub-maxillary glands.

RÉSUMÉ of WHITEHEAD'S operation (slightly modified) :—

1. Perform a preliminary laryngotomy if thought necessary.
2. Introduce the gag at side of mouth opposite disease.
3. Transfix the diseased half with the stout silk ligature; loop and knot the ligature, and pull the tongue well forwards. It is probably better also to pass a ligature through the other half of the tongue as well.
4. Split the tongue with a sharp-pointed bistoury along the raphé to a point well behind the disease.
5. Pull the diseased half well forwards and divide the mucous membrane close to the jaw, to be well away from the disease.
6. Next divide the anterior pillar of the fauces, and free the half of the tongue all round.
7. Divide the muscles fixing the tongue to the floor of the mouth.
8. Divide it transversely behind the disease with short snips, or by combined snipping and tearing, till the lingual artery is exposed.
- 9 Secure the artery with a pair of WELLS'S forceps, remove the tongue, and then tie the artery; or the artery may be tied before the tongue is removed.

2. By incisions below the jaw.—REGNOLI'S incisions were the following:—An incision of semi-lunar shape made along the line of the lower jaw, if possible confined within the space between the two facial arteries; another, a perpendicular incision, carried from the centre of the semi-lunar one, under the chin down as far as the hyoid bone, and then the flaps dissected back. Care must be taken not to injure the facial arteries. Then (*a*) the integuments are cut through, and after this the structures forming the floor of the mouth—viz., (*b*) the anterior bellies of the digastric muscles; (*c*) the mylo-hyoids, transversely at their anterior part; (*d*) the

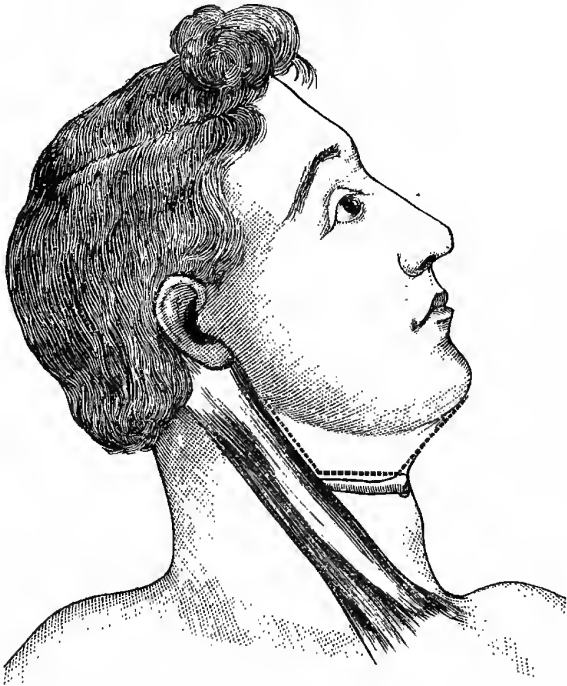
insertions of genio-hyoids and of the genio-hyoglossi; and (e) the mucous membrane of the floor of the mouth. A piece of strong whip cord is then passed through the tip of the tongue, or it is seized with a strong hook-forceps, and drawn through the opening between the lower jaw and the hyoid bone, and removed by the knife, or écraseur, by dividing its attachments—(1) to the epiglottis, viz., the three epiglottidean folds of mucous membrane (a central and two lateral); and (2) to the hyoid bone, viz., the hyoglossus and genio-hyoglossus muscles, and the hyoglossal membrane. The lingual ends of the palato-glossus and stylo-glossus will also be divided. The lingual arteries may now be secured, or they may be exposed and tied before removing the tongue; they will be found to pass forwards on the outer side of the genio-hyoglossi muscles between them and the hyoglossi. The wound is then stitched up and drained from the lower end of the vertical cut. The great objection to this operation is, that all the muscles that elevate the hyoid bone and larynx are divided, and it consequently interferes with the movements of deglutition and respiration to a certain extent.

Kocher's Method (Fig. 150).—By this method not only the tongue, but the infra-maxillary glands are also removed. He performs a preliminary tracheotomy, and introduces a TRENDELENBURG'S canula, or a HAHN'S tube, and the facial and lingual arteries are ligatured at an early stage of the operation. The incision he uses is the following:—It begins a little below the lobule of the ear, and is carried down along the anterior edge of the sternomastoid to the level of the great cornu of the hyoid bone. From this point the incision is carried forwards nearly to the body of the hyoid bone, and then upwards along the line of the anterior belly of the digastric to the jaw. The lingual artery and the facial vessels are secured and divided, and the flap is then turned up over the face, and by a careful dissection the submaxillary lymphatic glands and tongue are removed. Not only may the submaxillary glands be removed, but the glands near the angle of the jaw and those about the bifurcation of the common carotid, as well as those on the hyoglossus, may also be taken away by this incision. The **advantages** claimed for this method are that the dangers from hæmorrhage, septic absorption, and pneumonia are done away with.

The patient should be fed by a stomach tube, or per rectum, for the first few days, otherwise particles of food lie about the wound and decompose. The stomach tube should be passed during the operation, and left *in situ*, the end being brought out under the jaw, through the wound at the side of the neck.

Fig. 150.

KOCHER'S EXCISION OF THE TONGUE.



3. By Section of the Lower Lip and Jaw.—This operation was first performed in this country by SYME. By it the disadvantages of RENGOLI'S method are done away with, but there is an additional risk incurred from the section of the lower jaw, and that is the great disadvantage of this operation, as its severity, it is said, is materially increased by division of that bone; and, further, it is

impossible to keep the floor of the mouth aseptic. It is the method to be adopted when very free access is required—*e.g.*, when the disease has extended back to the tonsils. A piece of strong whipcord is passed through the tip of the tongue, so as to enable it to be drawn forwards when necessary, and the two central incisor teeth are extracted. Then an incision is made through the central line of the lower lip, across the chin, and down as far as the hyoid bone; the operator next divides the soft parts in the middle line, detaches the genio-hyoglossi muscles, and saws the lower jaw through at the symphysis. It is recommended to make the section of the bone >-shaped, so that the two halves may lock after the operation; or two holes may be drilled in the bone before the section is made, by which the two parts may be sutured afterwards. The sawn ends of the jaw are next firmly tied with a piece of narrow cotton bandage, and the two halves of the bone forcibly separated by assistants, and the mucous membrane and hyoglossi muscles cut through, first on the one side and then on the other. The tongue is next drawn forwards, and the lingual arteries divided and secured on both sides, and it is then removed from the hyoid bone by a stroke of the knife, or gradually removed by the wire *écraseur*; all bleeding vessels are now to be tied, as twigs from the ascending pharyngeal, and tonsillar branch of the facial. In this, as in other methods, either or both lingual arteries may be tied before beginning the operation, or else a preliminary laryngotomy may be performed. Not only does this latter plan obviate the dangers arising from the passage of blood down the respiratory passages, but is believed also to be a safeguard against septic pneumonia, as the patient breathes through the tube, and does not, therefore, inhale septic organisms from the wound in the mouth or jaw, or from the stump of the tongue; the method of continuous irrigation with some warm antiseptic solution, however, should greatly lessen the risk of inhaling septic organisms.

RÉSUMÉ of the operations for excision:—

1. As a rule, use WHITEHEAD'S method.
2. In some cases, where the glands below the jaw are much enlarged, and if the patient presses the operation, use REGNOLI'S method, or the plan adopted by KOCHER;

in many cases neither of these will give free enough access, though the wound can more easily be kept aseptic, and the jaw is not divided.

3. In cases where very free access is required, as when the disease has spread back to the tonsil, use SYME'S method; though perhaps the least safe, it gives the freest possible access. It is also to be used in cases where both sides of the anterior part of the floor of the mouth are involved, with enlarged glands under the jaw. This method will probably always require a preliminary laryngotomy.

Lymphatics of the Tongue.—The lymphatics of the tongue accompany the ranine veins, and pass through some small glands lying on the hyoglossus, and thereafter follow the course of the lingual vein, and enter the deep cervical glands near the bifurcation of the common carotid and the great cornu of the hyoid bone; it is here, therefore, that one must look for secondary glandular enlargement in epithelioma of that organ. The anterior part of the tongue may also affect the submaxillary glands, while the posterior part may affect the glands at the angle of the jaw before entering the deep cervical set.

In Epithelioma of the Tongue, pain in the ear is regarded as a specially grave symptom; it may indicate either that the disease has passed deeply into the floor of the mouth and involved the trunk of the lingual nerve, or that it has passed so far back as to involve the tonsil. In the former case the pain is conducted to the ear and temporal region along the lingual nerve, and from it to the other branches of the third division of the fifth, especially the auriculo-temporal nerve; in the latter the pain passes along the branches of MECKEL'S ganglion to the second division of the fifth, and from that to the temple, along the temporal branch of the orbital nerve. There is, however, still another explanation—viz., that the disease has passed so far back as to involve the *posterior third* of the tongue, which is supplied by the glosso-pharyngeal nerve. This nerve, besides supplying the tongue, is also the source of the chief supply to the tonsil. It is probable, therefore, that the tympanic branch of this nerve (JACOBSON'S nerve), carries the irritation to the tympanic plexus; hence the pain in the ear, and

hence also the gravity of the symptom when present. Another symptom present is profuse salivation, which exhausts the patient; this is reflex, the afferent nerves being the lingual or the glosso-pharyngeal, and the efferent the chorda tympani and JACOBSON'S nerve, or the small superficial petrosal. The growth of the cancer irritates the lingual or the glosso-pharyngeal, and hence the profuse flow of saliva. The cancer thus kills—(1) By the pain, that wears the patient out; and further, he is afraid to eat, and is thus starved; (2) the profuse salivation; and (3) hæmorrhage.

The Arteries of the Tongue are on each side the ranine and the dorsalis linguæ from the lingual, branches from the ascending pharyngeal, and tonsillar branch of the facial, towards the root of the organ.

The Nerves consist of three sets in each half—(1) **Motor**, the *Hypo-glossal*; (2) **Common Sensation**, the *Lingual* for the anterior two thirds, the *Glosso-pharyngeal* for the posterior third, and towards the root, the *lingual filament* of the *Superior Laryngeal*; (3) **Special Sense of Taste**, the *Chorda Tympani*, for the anterior two thirds; and the *Glosso-pharyngeal*, for the posterior third.

THE NOSE.

Boundaries of the Fossæ.—The roof is formed by (*a*) the nasal bones, (*b*) the nasal spine of the frontal, (*c*) the cribriform plate of the ethmoid, and (*d*) the body of the sphenoid. The floor is formed by (*a*) the palate process of the superior maxillary, and (*b*) the palate process of the palate bone. It is concave from before backwards, and the posterior part is on a slightly lower level than the anterior. The **outer wall** is formed by (*a*) the nasal process of the superior maxillary, (*b*) the lachrymal bone, (*c*) the ethmoid, with its two turbinate bones, (*d*) the vertical plate of the palate bone, (*e*) the internal pterygoid plate of the sphenoid, and (*f*) the inferior turbinate bone. This wall presents three passages or meatuses formed between the turbinate bones. The **inner wall** or **septum** is formed by (*a*) the rostrum of the sphenoid, (*b*) the perpendicular plate of the ethmoid, (*c*) the vomer, (*d*) the crest formed by the meeting of the two palate bones, (*e*) the crest formed by the meeting of the two superior maxillæ, (*f*) the nasal spine of the frontal, (*g*) the crest of the nasal bones, and (*h*) the triangular

cartilage. The septum is sometimes perforated, and is very usually deflected to one or other side. The nasal fossæ communicate—in front, with the face, by the two anterior nares; and behind, with the pharynx, by the two posterior nares. Each fossa communicates with **four cavities**—(1) The orbit, by the lachrymal canal; (2) the mouth, by the anterior palatine canal; (3) the cranium, by the olfactory foramina; and (4) the spheno-maxillary fossa, by the spheno-palatine foramen. Each fossa also communicates with **four sinuses**—(1) The frontal above, (2) the sphenoidal behind, (3) the antrum on the outer side, and (4) the ethmoidal on the inner side. Along these various paths simple inflammatory affections, or specific septic inflammations—*e.g.*, erysipelas or diphtheria—of the nose readily spread, as their mucous lining is continuous with that of the nasal cavities.

Openings.—(1) Into the **superior meatus**—(*a*) The sphenopalatine, and (*b*) the posterior ethmoidal cells. The opening of the sphenoidal sinuses is usually behind the superior turbinate bone. (2) Into the **middle meatus**—(*a*) The infundibulum, by which the anterior ethmoidal cells, and through these the frontal sinuses, communicate with this meatus; and (*b*) the antrum—the opening of the antrum is close to that of the frontal sinus. (3) Into the **inferior meatus**—the nasal duct.

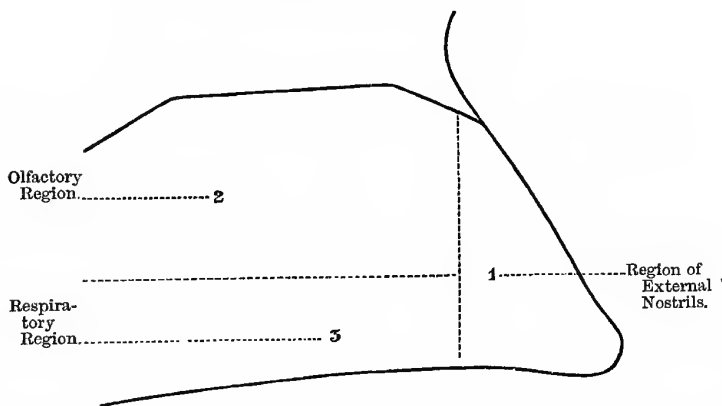
Regions of the Nose (Fig. 151).—(1) **Region of the External Nostrils**, the part that appears on the face. It is roughly triangular in shape, and is lined by squamous, stratified epithelium. (2) **The Olfactory Region**, which includes the roof of the nose, the upper and middle turbinate bones, and the superior and middle meatus, and the upper two thirds of the septum. In this region the olfactory nerve is distributed, terminating in the olfactory cells of MAX SCHULTZE, which are situated between the columnar cells covering the mucous membrane of this part. (3) **The Respiratory Region**—which includes all below the inferior turbinate bone—the inferior meatus, the floor of the nose, and the lower third of the septum. In this region the epithelium is columnar and ciliated. In all parts of the Schneiderian membrane there are numerous glands which secrete partly a mucous and partly a watery secretion; and in many parts it is also extremely vascular, almost forming an erectile tissue, especially over the inferior turbinate

bones. This free vascular supply is very important, as it enables the mucous membrane to play the part of a system of hot-water pipes, and warm the air before it reaches the lungs; hence the Creator intended man to breathe through his nose, not his mouth, as most people seem to think.

The chief Blood-vessels are the spheno-palatine and the descending branches of the internal maxillary artery, the anterior and posterior ethmoidal from the ophthalmic, and the artery to the septum from the superior coronary of the facial. Some of the Veins enter the superior longitudinal sinus through the foramen cæcum.

Fig. 151.

REGIONS OF THE NOSE.



In this way spreading septic inflammation and septic venous thrombosis may readily extend to the cerebral sinuses.

The Nerves are the **Olfactory**, or nerve of the sense of smell; the nerves of **Common Sensation** are the nasal branch of the ophthalmic, twigs from the superior maxillary, the Vidian, nasopalatine, and the anterior palatine.

The Lymphatics of the Nose pass—(1) To the deep parotid glands; (2) to the deep cervical glands, in front of and beneath the sterno-mastoid, and possibly to the submaxillary group; and (3) to a gland lying in front of the rectus capitis anticus major,

and axis, behind the pharynx ; hence, it is possible to have a retro-pharyngeal abscess from disease of the nose (FRÄNKEL). This, of course, would not communicate with the vertebræ, and the patient would therefore be able to move his head freely in all directions.

The **Nasal Bones** are frequently broken by direct violence, and the "bridge" of the nose driven in; if the mucous membrane be torn, there will probably be subcutaneous emphysema. The bones must be moulded into position by a pair of forceps pushed up the nostrils and the fingers without; when once in a position there is no tendency to a redisplacement, as no muscles act upon them. The fracture unites with great rapidity, being usually quite solid in two weeks. A blow at the **root** of the nose, however, is less likely to produce a fracture of the nasal bones, as at that point they are thick and strong; a fracture of the cribriform plate of the ethmoid, or the orbital plate of the frontal, is far more likely to occur, with or without injury to the first and second pairs of cranial nerves (*olfactory* and *optic*). It may also produce a depressed fracture *into the frontal sinus*, but without injuring the inner table, or the contents of the cranial cavity. It should be remembered that a crack into the frontal sinus, or the nose, or the antrum, will produce subcutaneous emphysema.

Epistaxis, or bleeding from the nose, may either be traumatic or idiopathic. *Traumatic*, usually from a direct blow, or from fracture of the base of the skull. *Idiopathic*, as from local congestions of the mucous membrane, disease of the blood-vessels, altered blood states, as purpura hæmorrhagica, hæmophilia, and scurvy; from an impoverished state of the blood in the cachetic and anæmic, also associated with kidney, liver, and heart diseases; and, lastly, from vascular malignant growths. It might also be classified according to the age of the patient. (1) **In the young**—From local congestion, as frequently seen in children, and in young persons about puberty, especially in girls; in the young, also, epistaxis from falls and blows is common. (2) **In middle life**—As an accompaniment of kidney, liver, and heart disease, especially the granular contracted kidney and cirrhosis of the liver; in some of these cases, especially in general plethora, the bleeding instead of doing harm may do good, as it may be the means of preventing a cerebral hæmorrhage. In the anæmic and cachectic, however, it

is a very serious matter. The state of the pulse will be some guide as to what to do; if the pulse be hard and incompressible do not be in too great a hurry to stop it. (3) **In the old**—It may arise from disease of the vessels, or from weak and anæmic states of the system, and also from the various conditions causing epistaxis in middle life as well. In the old and weak it is a very serious matter if profuse, but in the young and plethoric it rarely does much harm.

Treatment.—(1) Inject **ergot** hypodermically, as it acts much more quickly this way. (2) In the interval between its injection and the time it takes effect, use **general means**, as mental and bodily rest with the head elevated; the head must not be held down over a basin. That in itself is quite sufficient in many cases to cause epistaxis, and is a very important agent in keeping up an attack. **Cold** to the back of the head and neck to stimulate the vaso-motor centre—hence the popular, old-fashioned, cold door key; the modern “Chubb” is of little use. A very important point, I believe, is to **keep the mouth open and breathe freely and deeply** for a short time, as this in a very marked manner lessens the congestion of the vessels of the head and neck by the aspiration of the thorax, and if persisted in will even cause fainting from anæmia of the brain; this is the only method I adopt in my own case, and I have always found it speedily effectual. It may also be supplemented by elevation of the arms, as this expands the thorax. (3) By means of a soft camel’s hair brush swab out the interior of the nose freely with a mixture of equal parts of **perchloride of iron and glycerine**, especially in the region of the anterior nares and the inferior turbinated bone—parts, on account of their great natural vascularity, from which the bleeding is most likely to come. In most cases, I believe, this will be quite sufficient without plugging of any kind. (4) **Plug the anterior nares**; for this purpose use a long, narrow strip of lint, and a narrow-bladed dressing forceps, and pack the lint firmly into the anterior nares in all directions, leaving one end of the strip projecting a little way from the nostril. (5) As a last resort **plug the posterior nares** as well. For this purpose we require a plug of folded lint one inch long by half-an-inch wide, or the size of the last phalanx of the thumb, fixed by its centre to the middle of a long piece of strong cord, and a

BELLOCQ's sound or an ordinary gum elastic catheter. Withdraw the stilette of the catheter, and then pass the catheter along the floor of the nose and hook it out through the mouth; tie the string firmly to the end of the catheter and then withdraw it, when the string will be brought out at the anterior nares. The catheter is then cut free and the plug drawn into and firmly impacted in the posterior nares; both ends of the cord are then tied together loosely at the angle of the mouth. If both nares require to be plugged, of course we will require two plugs. The plug is left in for forty-eight hours or so, and when it is to be removed it must be pulled back through the mouth; the **string**, however, should not be taken away till all the risk of recurrence seems past.

Rhinoplasty.—Plastic operations for the complete restoration of lost or for the repair of mutilated noses. The flaps may be taken from—(a) The cheeks, (b) the forehead, or (c) from a distant part, as the inside of the arm.

(1) **From the Cheeks** (SYME)—Either by gliding, or partial rotation leaving the flaps attached above. (2) **From the Forehead** (the *Indian operation*)—Here a properly-shaped flap is *twisted* down from the forehead, being left attached by a narrow pedicle; the incision on the right side is made lower than on the left to give it an easy twist, the flap being then *turned to this side*. The flap is supplied by the frontal artery and the supra-trochlear nerve, and it is important to make the pedicle of sufficient length to allow of its being twisted round without affecting the circulation through it. (3) **From a distant part** (the *Italian* or the *Tagliacotian operation*)—The flap is taken usually from the left upper arm over the biceps muscle; the arm is bandaged up over the forehead, and the flap left attached by its base to the arm for a few days till it has become organically connected with the nose.

Other methods might be used as—(a) **Superimposed, or double flaps**, one flap being *turned down* from the forehead with its epithelial surface next the nasal fossæ, and then two quadrilateral door-like flaps slid over it from the cheeks. (b) Transplantation of a piece of skin from one part of the body to the other, the transplanted part being completely separated at the time of the operation; in this case, however, the flap runs a great risk of dying before it becomes adherent to the nose.

Inflammation or abscess in the **Frontal Sinuses** causes much suffering, from the unyielding walls of this cavity; it forms one variety of "headache," as seen in an ordinary cold. Discharges, as pus or fluid, from the frontal sinuses are not influenced by position as are the discharges from the antrum. Occasionally the frontal sinuses are the seat of large mucous polypi—*mucocoele* of the frontal sinus. The polypi may give rise to considerable prominence of the bone in this situation, and may also bulge into the orbits, displacing the eyeballs, and causing double vision. In such a case, the sinus should be trephined, and the polypi removed. Mucous polypi from the nose may also make their way into the frontal sinuses.

In examining the nose, for growths or obstructions of any kind, always pass a probe to see whether the growth is movable; by this means one may distinguish hypertrophy of the mucous membrane of the inferior turbinate bone from polypi—the hypertrophy is not movable, while polypi are. It is necessary to use a speculum and reflected light to examine the nasal cavities, the head being thrown backwards and the tip of the nose elevated. One must not mistake lateral deviation of the septum for a tumour; its true nature will be recognised by observing that there is a hollow in one fossa corresponding to the projection in the other. But if this is not the case, then it is a tumour of the septum.

Polypi may be—(1) **Mucous**.—These usually grow from the mucous membrane of the outer wall, especially over the inferior and middle turbinate bones: are yellowish grey in colour: are usually found in middle-aged persons, and are multiple: give rise to fits of sneezing and a nasal tone of voice and snoring at night, and are worse in damp weather; they do not, as a rule, cause deformity, nor do they give rise to hæmorrhage. Occasionally, however, when numerous, they may cause marked deformity. They may make their way into the frontal sinus or orbit, and displace the eyeball considerably, giving rise to double vision. Under such circumstances, it will be necessary to open the orbital cavity at the inner side and remove the polypi. **Structure**.—Mucous polypi are covered by a layer of beautifully ciliated, columnar epithelium. Below this there is a web of mucous connective tissue, and in the meshes of this web there is a layer of branched mucous glands,

often of considerable thickness. For this reason many prefer to call them *adenomatous polypi*, instead of mucous. The polypi also contain blood-vessels and lymphatics. The mucous tissue may become more highly developed, being transformed either into fat or fibrous tissue, or partly both. (2) **Fibrous**.—These usually grow from the *periosteum* of the naso-pharynx, basi-sphenoid, or nasal roof, and are probably sarcomatous in nature; they occur earlier in life, are *deep red* in colour, single, with a broad base: they cause deformity, widely separating the eyes, and giving rise to “frog-face:” and, lastly, are frequently attended with severe epistaxis. (3) **Malignant**, usually begin from the antrum (see “Diseases of the Antrum”).

The chief **clinical features** of the case, besides the deformity produced, are obstruction of one or both of the fossæ and bleeding. Polypi are also apt to press upon and obstruct the nasal duct, giving rise to one form of “watery eye.” Bulging of the cheeks, widening of the eyes, broadening of the nose, are usually characteristic of malignant polypi. These signs are also more or less present in fibrous, and sometimes, though rarely, in the mucous forms — which, through repeated attempts at removal, tend to become fibrous in structure. It should be remembered that, by snuffing up powdered tannin or rectified spirit, mucous polypi may be made to disappear.

Annandale’s Operation for Naso-Pharyngeal Tumours.—Professor ANNANDALE uses this operation for the removal of large naso-pharyngeal tumours. The **steps of the operation** are the following:—(1) Freely expose the anterior nares by the separation of the upper lip from its attachments and by division of the nasal septum, as in ROUGE’S operation. (2) Next, saw through the hard palate, and if necessary divide the soft palate as well. (3) Forcibly separate the two superior maxillæ. (4) Remove the growth by finger, forceps, etc. (5) Then plug antiseptically, and bring the hard and soft palates together again.

The **advantages** of this operation are—(1) It produces no deformity; (2) it forms the preliminary stage of a further operation, should it be deemed necessary to remove the whole or part of the upper jaw; and (3) the section being central, there is less bleeding.

Malignant tumours of the antrum and upper jaw gradually creep through the various foramina and fissures of the base of the skull, and encroach upon the nasal cavity, mouth, and orbit. Polypi must be diagnosed from—(1) Thickened mucous membrane over the inferior spongy bone; this is red, and cannot be moved with a probe. (2) Abscess of the septum. (3) Deviation of the septum to one or other side; in this case there will be a hollow on the opposite side. (4) A meningocele, protruding through the roof of the nose.

Ozæna is a term applied to cases where there is a purulent discharge from the nose, frontal, ethmoidal, or sphenoidal sinuses, and which has a specially offensive and penetrating odour. It is said to arise from chronic atrophic rhinitis, with purulent secretion; this dries and forms crusts with a very offensive odour. It is usually bilateral; and if unilateral, is regarded as characteristic of empyema of the antrum. The crusts must be got rid of by sniffing up into the nostril, or spraying it with solutions of the alkaline carbonates or bicarbonates; and after this, local tonic, antiseptic, and soothing applications used. *Ozæna* may also be due to a foreign body introduced from without; in this case it will be unilateral, and the patient will smell the disagreeable odour with the sound nostril. It may also be due to injury, syphilis, and struma, or to the so-called "atrophic catarrh." Syphilitic *ozæna* is the only form that causes *rapid* destruction of the bones of the nose, although strumous inflammation may also cause destruction of the bones, but much more rarely.

In cases of obstinate *ozæna*, due to necrosis, in which the sequestra cannot be removed through the nose, **Rouge's operation** may be adopted. In this operation the upper lip is everted, a transverse incision is made between the second bicuspid teeth of each side, and the soft tissues connecting the upper lip with the jaw divided; the cartilages are next separated, and the septum of the nose divided, with strong scissors, sufficiently to allow the upper lip and nose to be pulled upwards far enough to expose the nasal cavity. After this operation no scar is visible, as the skin is not divided.

Perforation of the Septum of the nose may occur under four conditions—(1) In the scrofulous; (2) in syphilis, hereditary or

acquired; (3) it may also exist as a congenital malformation; and (4) is often found in those exposed to the vapour of chromic acid, in the manufacture of bichromate of potash—the “**bichromate disease.**” In ordinary cases it begins as a simple pimple or pustule, which is picked and irritated so that an ulcer is formed that gradually eats through the septum.

Tumours and Swellings of the Septum.—(1) *Hæmatomata* are occasionally found, after an injury; (2) abscesses also occur, though rarely; (3) *gummata* are sometimes found beneath the perichondrium; (4) an *osteoma* may be met with; (5) *adenomata* are sometimes seen; and (6) also a curious tumour, composed of cartilage—*ecchondrosis* of the septal cartilage. The cartilages and septum are also affected in *Acromegaly* and *Leontiasis ossea*.

A **Dermoid Cyst** is sometimes met with at the side of the nose, in the position of the naso-maxillary fissure of the embryo. Chronic nasal catarrh, with hypertrophy of the mucous membrane, and polypi, are said to give rise to many reflex nervous phenomena—as asthma, spasmodic fits of sneezing and coughing, megrim, supra-orbital neuralgia, vaso-motor disturbances causing redness of the tip of the nose and cheeks, herpes labialis, vertigo, and epilepsy. On the anterior end of the inferior turbinate bone, there is a layer of erectile tissue, and it has been supposed that turgescence of this tissue is sufficient to account for many of the above phenomena. If this be so, then the cure is to be found in painting the part with a solution of cocaine, or else destroying the hypertrophied, congested, and sensitive mucous membrane with the galvano-cautery. Cases have also been observed in which intra-nasal operations, undertaken for the relief of nasal obstruction, have led, very unexpectedly, to the diminution, or even disappearance, of the symptoms of **GRAVES'S** disease.

THE ANTRUM.

The antrum of **HIGHMORE**, or the maxillary sinus, is a large triangular-shaped cavity, hollowed out in the body of the superior maxilla. Its **apex** is directed outwards, and its **base** is formed by the outer wall of the nose. Its **roof** is very thin, and is formed by the orbital plate of the maxilla; its **floor** is formed by the alveolar process, its anterior wall by the facial, and its posterior

by the zygomatic surface. Its aperture is near the upper level of the cavity, and communicates with the middle meatus of the nose, the position of the opening being about the centre of the middle meatus, and one inch above the floor of the nasal cavity; the opening here is sufficiently large to admit the end of a small probe, and in some cases is much larger. Projections into the floor are made by the fangs of the first and second molar teeth usually, but others may also project into it, from the canine to the wisdom, inclusive. The fangs of the first molar may lie free in the cavity, being simply covered by the mucous membrane. A growth in the cavity may, therefore, readily encroach upon the orbit above, displacing the eyeball and giving rise to double vision unilateral optic neuritis, and severe neuralgia, from pressure on the infra-orbital nerve; the nose, on the inner side, closing up that cavity and also obstructing the nasal duct of the same side, causing "stilloidum lachrymarum;" in front, causing a projection on the cheek; behind, into the zygomatic fossa; and downwards, into the floor of the mouth. The antrum should always be first examined in any supposed tumour of the upper jaw.

Diseases of this Cavity.—1. **Tumours**—(a) *Malignant* often begin in the antrum, such as sarcomata, and a very rapidly-growing form of epithelioma—the "boring epithelioma;" the Surgeon must be on his guard, as a sarcoma of the upper jaw may at first cause symptoms resembling toothache, the patient thinks, or neuralgia. Epithelioma may also simulate caries or necrosis. (b) *Simple*, such as enchondroma, fibroma, osteoma, etc.

2. **Suppuration and Abscess**—This may arise from—(a) Inflammation spreading from the nose and blocking up the opening of the antrum, leading to tension and abscess; (b) from disease of the teeth, as suppuration of the fangs of the bicuspids or first molars; (c) in weak debilitated strumous children, after fevers, etc., and in such cases there is often disease of the bone as well; and (d) it may arise from injury. If the opening is not blocked up, then the pus may overflow into the nostril, especially when the patient lays the sound side of the head flat on a pillow; but if the opening be blocked up, it will most probably point at the upper part, under the orbit, or through the thin canine fossa, lower down.

3. **Dropsy.**—The cavity either becomes slowly filled with a glairy fluid like that found in ranula, or it may be thin and serous. It is not due to the blocking up of the orifice into the nose, but from a cystic degeneration of the mucous membrane, resembling somewhat the ordinary mucous polypus of the nose, the cavity being filled by several small cysts, or by one large growth. When it was believed to be an accumulation of fluid resulting from a closed orifice, then the operation of “catheterisation” of the antrum was advised; this, as might be expected, from the erroneous pathology, was not followed by any benefit to the patient. A not unfrequent sign of this condition is a constant or intermittent trickling of watery fluid from one nostril, increased when the head lies on the opposite side; on examination it is found that the nasal fossa itself is quite clear.

4. **“Dentigerous” Cysts.**—These arise in connection with a misplaced, a too-deeply placed, or an inverted permanent tooth, usually an upper permanent canine. They may be recognised by the absence of a tooth from its proper place in the jaw, the globular or ovoid outline of the tumour and the gradual, painless growth; the cyst contains a thick, mucilaginous, or serous fluid containing cholesterine plates. In some cases, however, the corresponding milk tooth may not be shed, so that the Surgeon must be on his guard not to be misled by the mere number of teeth. The fang of the tooth is usually in its socket, but the crown lies in a cavity filled with the enamel pulp and covered by a layer of epithelium which secretes the fluid. This arrest of development will, so far, be understood by a reference to the development of the enamel from the enamel organ and dental sac. This organ consists of—(1) A layer of epithelium next the wall of the sac; (2) the enamel pulp, consisting of jelly-like mucous tissue; (3) a layer of undifferentiated cells; and (4) the internal epithelium, which ultimately develops into the enamel prisms. The proper **Treatment** for these cysts is to remove a part of the wall, turn out the contents, and stuff the cavity, in order to make it heal from the bottom upwards.

In **tapping** fluid collections in the antrum—(1) The upper lip may be everted and an opening made through the thin canine fossa just above the second bicuspid tooth. (2) By extracting the first molar, as this tooth is very often carious; but the bicuspids,

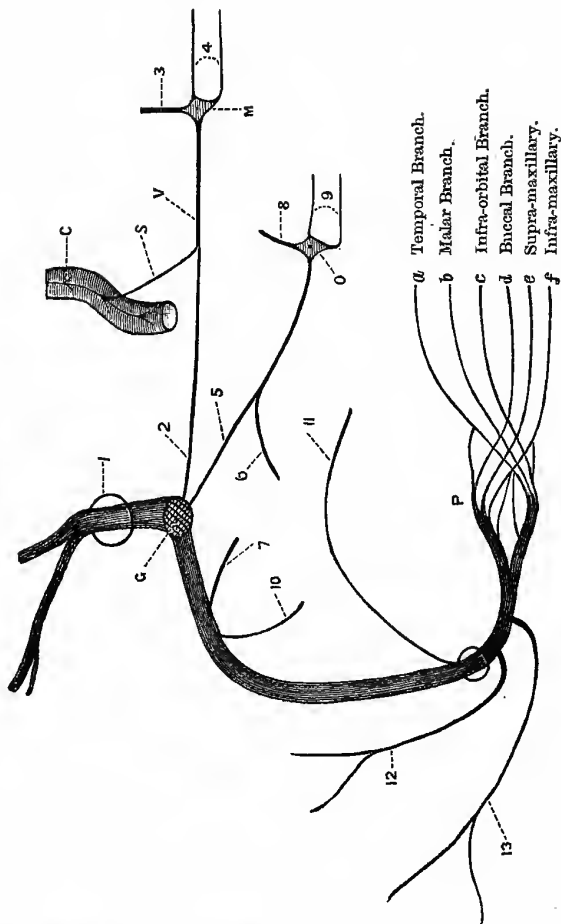
if diseased, may be taken instead. The first molar is a specially perishable tooth, and, therefore, likely to be less missed than the others; but remove any *carious* tooth. Do not try to perforate in the site of an old extracted tooth, as the walls of the socket will have come together, or the cavity be filled up with dense bone. (3) The antrum may be perforated through the outer wall of the inferior meatus of the nose; this was JOHN HUNTER'S plan (1771), and has recently been revived by MICKULIČZ and others.

CRANIAL NERVES.

The Facial Nerve (*portio dura of seventh*).—This is the motor nerve of the face. Its deep origin is from the formatio reticularis on the dorsal aspect of the pons at the upper part of the floor of the fourth ventricle, and from the lenticular nucleus of the *opposite* side; the fibres of the *portio intermedia* can be traced into the glosso-pharyngeal nucleus. It enters the internal auditory meatus to the inner side of and above the auditory (*portio mollis*). At the bottom of the meatus it enters the aqueduct of FALLOPIUS, traverses that canal, and makes its exit at the stylo-mastoid foramen (Fig. 152). In the bone it first passes *outwards* then *backwards*, forming the knee-shaped bend, where there is a gangliform enlargement (*the geniculate ganglion*), and after this it passes straight down to the stylo-mastoid foramen. It then divides in the parotid gland into *temporo-facial* and *cervico-facial* divisions; these, by a series of divisions and anastomoses, form the *pes anserinus*, from which branches pass to supply the muscles of expression.

Branches.—In the **meatus** it communicates with the auditory nerve. In the **aqueduct**—(a) The great superficial petrosal nerve from the ganglion, passing out at the hiatus Fallopii, grooving the anterior surface of the petrous part of the temporal bone, then running underneath the fifth nerve and Gasserian ganglion, it is joined by a twig from the sympathetic (carotid plexus), and after this is known as the Vidian nerve, which partly passes through the foramen lacerum medius into the Vidian canal, and enters MECKEL'S ganglion, of which it forms the motor root, and is distributed to the azygos uvulæ and levator palati muscles. (b) The small superficial petrosal, also from the ganglion. It takes a course similar to the last, but passes out at the foramen ovale and enters

Fig. 152.
THE FACIAL NERVE.



1. Beginning or the Aquaeductus Fallopii.
2. Great Superficial Petrosal.
3. Its Sensory Root, from the second division of the fifth.
4. Its Branches to the Azygos Uvulae and Levator Palati Muscles.
5. Small Superficial Petrosal.
6. Twig from Jacobson's Nerve, joining the small Superficial Petrosal, probably the Secretary Fibres for the Parotid Gland.
7. The External Superficial Petrosal.
8. Motor Root of Otic Ganglion, from the third division of the fifth.
9. Branches from the Otic Ganglion to the Tensor Tympani and the Tensor Palati Muscles.
10. Nerve to the Stapedius.
11. Chorda Tympani.
12. Posterior Auricular.
13. Branch to supply the Stylo-hyoid and the Posterior Belly of the Digastric.
14. Geniculate Ganglion.
15. Internal Carotid Artery, with Carotid Plexus of Sympathetic.
16. Sympathetic Twig to join the great Superficial Petrosal.
17. Vidian Nerve.
18. Meckel's Ganglion.
19. Otic Ganglion.
20. Pes Anserinus.

a Temporal Branch.
b Malar Branch.
c Infra-orbital Branch.
d Buccal Branch.
e Supra-maxillary.
f Infra-maxillary.

the *otic ganglion*, to which it conducts the secretory fibres for the parotid gland. (c) Next in order is the external superficial petrosal, which joins the facial, from the sympathetic plexus on the middle meningeal artery. (d) Next comes the tympanic branch to supply the stapedius muscle and the laxator tympani; and lastly, (e) the chorda tympani, which is given off just before the nerve makes its exit from the stylo-mastoid foramen. This nerve has already been seen in the middle ear, after which it passes through the canal of HUGUIER and joins the lingual branch of the fifth at an acute angle between the two pterygoid muscles, and passes with that nerve to the tongue, forming the nerve of taste to the anterior two thirds; it is also secretory to the sublingual and the submaxillary glands.

After the nerve has left the bone, it gives off—(a) The *posterior auricular* branch, which supplies the skin and posterior belly of the occipito-frontalis muscle; (b) a branch supplying the stylohyoid and posterior belly of the digastric; and (c) branches from the *pes*, six in number, supplying the muscles of expression from the brow to the chin—including the buccinator. These muscles are situated around the cavities of the orbit, nose, and mouth. The six branches are—(1) The *temporal*, to the anterior belly of the occipito frontalis; (2) the *malar*, to the muscles round eye; (3) the *infra-orbital*, to the muscles about the nose; (4) the *buccal*, to the orbicularis oris and buccinator; (5) the *supra-maxillary*, to lower lip and chin; and (6) the *infra-maxillary*, to platysma, etc. The buccinator (“trumpeter’s muscle”) may receive twigs from the buccal branch of the third division of the fifth, although many anatomists regard this as a purely sensory nerve; it is a muscle of mastication as well as of expression; its expressive powers are fully brought out in playing the French horn, and other instruments of a similar nature, and in saying “Poooh!” It will be noticed therefore that the muscle that opens the eye is supplied by the third nerve (*levator palpebræ*), while the muscle that shuts the eye (*orbicularis palpebrarum*) is supplied by the facial. In superficial ulcerations of the cornea, as phlyctenular ophthalmia (strumous) where photophobia is so prominent a symptom, the orbicularis is spasmodically contracted (*blepharospasm*) by the reflex irritation set up by stimulation of the terminal filaments of the first

division of the fifth in the inflamed area, or of the optic nerve, by the light.

Paralysis of this nerve may be caused by parotitis, rapidly growing tumours and abscesses of the parotid, or of the cervical glands, herpes zoster, wounds of the cheek, operative or otherwise, forceps in child birth; it may also be caused quite suddenly by exposure to cold ("BELL'S paralysis") rheumatic inflammation of the nerve or its sheath, disease of the middle ear, and periostitis from various causes. It may be paralysed at its root by a blood clot in the pons; it is also usually affected in hemiplegia. Syphilitic and other tumours may also affect its origin, and it is one of the nerves involved in "Bulbar paralysis." Occasionally it may be the earliest symptom of tubercular meningitis (FAGGEE). It may be paralysed—

1. At or after its Exit from the Stylo-Mastoid Foramen.— This is, properly speaking, "BELL'S paralysis." The signs are— (a) The wrinkles disappear from the brow, giving it a smoother appearance than the other side. (b) The eyelids cannot be closed (*lagophthalmos* or *Hare's eye*). (c) The lower lid falls down, and the punctum is drawn away from the globe; hence, the tears run over the cheek. (d) The nostrils cannot be dilated. (e) The mouth and face are drawn towards the sound side. (f) The buccinator is paralysed, and the food passes between the teeth and the cheek; further, the cheek is flabby and falls in and may be caught by the teeth. (g) The patient cannot whistle or laugh properly, and the angle of the mouth is depressed and drawn to the sound side. (h) The posterior belly of the digastric and stylohyoid muscles are paralysed.

2. It may be paralysed in the Petrous Bone, as in disease of the middle ear, fracture of the base, etc. A case is mentioned by Mr HUTCHINSON, where paralysis of this nerve was caused by a blow from a cricket ball on the chin, probably from fracture of the petrous bone. In this case the signs will vary with the height at which the nerve is affected; they will be given here, from below upwards. In addition to the previous symptoms, we will therefore have—(a) Loss of taste in the anterior two thirds of the tongue, because the chorda tympani is paralysed. The food tastes salt, or a sour or metallic taste may be felt, and the person is

unable to detect sweet or saline tastes. Taste *seems* to be affected when the olfactory nerve is paralysed; this is not because it is actually affected, but because the power of distinguishing *flavours* is lost, so that one is unable to tell an apple from an onion. (b) The sense of hearing will be affected, as the stapedius muscle is paralysed. There is usually increased sensibility for all musical notes or sounds, and the patient can detect sounds of a very low pitch; or may seem subjectively to hear acute sounds (*oxyakoaia*), because the stapedius is paralysed, and hence the tensor tympani keeps the membrane too much on the stretch. (c) The mouth will be dry, because the salivary glands are not secreting (the lower two by the chorda, the parotid through the small superficial petrosal). This is known as "dry mouth," or *xerostomia*. (d) The palate falls down on the paralysed side, because the levator and azygos uvulæ muscles are paralysed (through the great superficial petrosal), and the uvula points towards the healthy side.

3. The Paralysis may be Central, that is, in the brain. In this case, curiously enough, the *upper* part of the face usually escapes—the brow and the muscles collected round the orifice of the orbit. This is probably because of the fasciculus of fibres that arise from the opposite side. Another important difference is, that in central or cerebral lesions the electrical reactions are the same as in health; whereas, when the paralysing lesions are in the *course of the nerve*, we very quickly get the "reaction of degeneration." It is often stated, in cases where this nerve is paralysed, that the tongue is also affected. This I believe to be a time-honoured misunderstanding. It certainly *seems* to go to one side, but this is because the mouth is not in the middle line in facial paralysis, and hence the tongue, even when put out quite straight, is nearer the paralysed than the healthy side.

The Facial Nerve is at fault in cases of "histrionic spasm," or actor's paralysis, which consists of an almost constant twitching of the muscles of the face. To cure this condition the nerve has been **stretched**.

Operation.—Make an incision from the root of the mastoid process downwards and forwards to near the angle of the lower jaw, and expose the anterior border of the process and the anterior edge of the sterno-mastoid, and turn the parotid gland forwards.

Next define the upper border of the posterior belly of the digastric; the nerve runs parallel to this, and will be found emerging from under the mastoid process.

Meckel's, or the Spheno-Palatine Ganglion.—This structure is deeply placed in the spheno-maxillary fossa, close to the spheno-palatine foramen, on a level with the root of the pterygoid processes, and immediately below the superior maxillary nerve.

Roots.—1. The **Sensory**, from the second division of the fifth, as it lies immediately above it, crossing the spheno-maxillary fossa. 2. The **Sympathetic**, from the carotid plexus through the Vidian. 3. The **Motor**, from the facial (*great superficial petrosal*), through the Vidian also. The ganglion may be most readily exposed by removing the upper jaw, and it is probably always exposed in that operation. It will be found in the spheno-maxillary fossa, immediately in front of the Vidian canal, and connected with the Vidian nerve. It may also be reached by **Carnochan's operation**: The anterior wall of the antrum is exposed, and a large, trephine hole made; next expose the infra-orbital nerve by cutting away the lower wall of the infra-orbital canal, and follow it up to the posterior wall of the antrum. Then just under this make a small trephine hole in the posterior wall, isolate the nerve, and follow its descending branches to **MECKEL'S** ganglion. Lastly, divide the main nerve close to the foramen rotundum, and remove it along with the ganglion. After this, of course, the levator palati and the azygos uvulæ of that side are permanently paralysed. Its **Branches** are motor to the levator palati and the azygos uvulæ muscles, and also to the muscle of **MÜLLER**; for the rest, it is sensory to the nose, pharynx, and palate. Cases of intractable epileptiform neuralgia have been greatly benefited, or even cured, by excision of this ganglion.

The Second Division of the Fifth (*superior maxillary nerve*).—It arises from the Gasserian ganglion, leaves the skull by passing through the foramen rotundum into the spheno-maxillary fossa, crosses that fossa and enters the orbit through a fissure of the same name, and then enters a canal on the floor of the orbit, appearing on the face at the infra-orbital foramen, where it divides, beneath the levator labii superioris, into palpebral, nasal, and labial branches. It is purely a sensory nerve. Its **branches in the fossa** are—

(a) orbital or temporo-malar, (b) sphenopalatine to MECKEL'S ganglion, and (c) posterior dental to the teeth of the upper jaw. In the **infra-orbital canal** it gives off the anterior dental branches. In deep-seated affections of the cornea and iris the pain is sometimes reflected along this nerve, affecting the upper jaw through its dental branches, and the temporal region along its orbital branch. A blister in the temporal region sometimes benefits eye affections, probably by acting through this nerve as a counter-irritant. This nerve may be affected with neuralgia from unknown causes, or from diseases of the teeth in the upper jaw; and from malignant tumours of the antrum, or the sphenomaxillary fossa. It appears on the face three times—(1) as the *infra-orbital*; (2) as the *temporal*, in the temporal fossa; and (3) over the malar bone, as the *ramus subcutaneous malaræ*.

The Third Division of the Fifth (*inferior maxillary*).—This is the largest division, and, like the last, it arises from the Gasserian ganglion, leaves the skull through the foramen ovale, and is then joined by the motor root of the fifth, and thereafter divides into a small or *anterior division*, chiefly motor in function, and a large or *posterior division*, chiefly sensory. From the **anterior division** proceed—(a) the masseteric nerve to the masseter muscle, and sometimes a twig to the temporo-maxillary articulation; (b) two deep temporals to the temporal muscle; (c) branches to the two pterygoids; and, lastly (d) the long buccal nerve. The nerve to the internal pterygoid furnishes the motor root to the otic ganglion, and through that to the two tensors—tensor palati and tensor tympani. The *buccal nerve* is sensory to the buccinator muscle and the mucous membrane and skin of the cheek, and *may possibly* contain motor filaments; it also communicates with the facial nerve. This division, it will be noted, supplies the muscles of mastication. From the **posterior division** come—(a) the auriculo-temporal—this nerve also supplies the joint of the lower jaw and the external auditory meatus; (b) the inferior dental; and (c) the gustatory, or lingual, nerve. From the lingual comes the mylo-hyoid nerve, which supplies the mylo-hyoid muscle and the anterior belly of the digastric. When this division of the fifth is paralysed the following muscles are affected—the masseter, the temporal, external and internal pterygoids, the mylo-hyoid, and the anterior belly of

the digastric, and lastly, the tensor tympani and the tensor palati. This third division appears on the face three times—(1) as the *mental* branch, over the chin; (2) as the *auriculo-temporal*; and (3) as the *long buccal*, on the cheek.

The Otic Ganglion (ARNOLD'S).—This ganglion lies immediately below the foramen ovale, on the inner surface of the inferior maxillary nerve, and round the origin of the nerve to the internal pterygoid muscle, and in front of the middle meningeal artery. Its **roots** are—(a) *Motor*, from the internal pterygoid nerve (third division of fifth), which is the guide to the ganglion, and through which it supplies the tensor palati and tensor tympani muscles; (b) *Sensory*, from the auriculo-temporal; (c) *Sympathetic*, from the plexus on the middle meningeal artery; and (d) it also communicates with the facial and glosso-pharyngeal through the small superficial petrosal. Its secretory fibres probably come from the tympanic branch of the glosso-pharyngeal (JACOBSON'S nerve), *viâ* the small superficial petrosal and auriculo-temporal nerves, and the otic ganglion. This nerve **may be affected** with “idiopathic” neuralgia, in disease of the teeth of the lower jaw, in ulcers of the tongue, in epithelioma of the tongue, and in the eruption of the lower wisdom teeth, and in tetanus; in irritable sores about the tongue, and in the eruption of the wisdom teeth, the muscles that close the jaws may be thrown into spasm reflexly, and simulate “lock-jaw.” Spasm of the muscles of the jaw is often an early symptom in true tetanus, and is known as “trismus,” or “locked jaw.” The *mental* branch is often affected in fractures of the lower jaw.

To Expose this Ganglion necessitates the dissection of the Pterygo-Maxillary Region.—(1) Clear out the parotid gland and the structures in it (see vol. ii., p. 95). (2) Remove structures on the masseter—(a) Part of the parotid gland and socia, (b) STENSON'S duct, (c) the transverse facial artery and veins, (d) the facial vein, (e) branches of facial nerve and great auricular, and (f) the risorius muscle and some lymphatic glands. (3) Remove the two layers of temporal fascia above the zygoma, and saw through that bone in front and behind, and throw it down with the masseter muscle. (4) Snip off the coronoid process and throw it up along with the temporal muscle, and then saw through the ascending ramus, first

at the neck of the condyle, and again at the level of the molar teeth. This now exposes the first and second parts of the internal maxillary artery, the two pterygoid muscles, and the chief branches of the third division of the fifth. (5) Now disarticulate the condyle of the jaw and throw it forwards with the external pterygoid muscle, when the foramen ovale, the trunk of the third division of the fifth, and the chorda tympani nerves are all exposed. Lastly, secure the nerve to the internal pterygoid muscle, and trace it up to the ganglion.

The Eighth Pair consists of three divisions, and which all come from nuclei in the lower part of the floor of the fourth ventricle.

1. **The Glosso-Pharyngeal.**—This nerve supplies the posterior third of the tongue with ordinary sensation and with the sense of taste. It also supplies the stylo-pharyngeus muscle, and helps to supply the constrictors of the pharynx; it further supplies the tonsil, and gives off JACOBSON'S nerve to the tympanum. Its relations to diseases of the tongue and tonsil have been already seen.

2. **The Vagus, or Pneumogastric,** is principally distributed to the lungs and respiratory passages, the heart, and the pharynx, œsophagus, and stomach. Its branches are—

- (a) ARNOLD'S nerve, which is the nerve of common sensation to the back of the auricle and external auditory meatus—the “Alderman's nerve.”
- (b) The pharyngeal branch helps to form the pharyngeal plexus and supply the constrictors.
- (c) The superior laryngeal, sensory to the larynx and root of the tongue at the base of the epiglottis, and motor to the crico-thyroid muscle, and probably half the arytenoid; it can also inhibit inspiration and excite expiration, and reflexly cause spasm of the glottis.
- (d) The cervical cardiac branches, sensory nerves of the heart (“depressor nerve”), also vaso-inhibitory to the blood-vessels of the abdomen—this nerve is probably much affected in “shock.”
- (e) The recurrent laryngeal, motor to all the muscles of the larynx not supplied by the superior.
- (f) The inferior cardiac, inhibitory of the heart.

- (g) The pulmonary branches, motor to the bronchial muscles, and excito-motor for respiration.
- (h) Œsophageal branches (*plexus gulæ*).
- (i) The gastric branches—motor, sensory, secretory, and vaso-inhibitory.

In severe head injuries, a not uncommon complication is pncumonia, probably because the vagus is in some way interfered with, and hence also the vomiting, thirst, and sleeplessness. In shock this is the nerve first affected, and then, through this, to the heart and abdominal blood-vessels; the heart quickly recovers, but the paresis of the abdominal and other vessels may last some time, and keep up the condition of collapse. The vagus has extensive communications with the great sympathetic nerve plexuses of the abdomen, and it is in this way that vomiting is caused in strangulated hernia. This nerve is the most remarkable nerve in the whole body. It supplies the liver, spleen, and kidney, probably the ovaries, uterms, and testicles; the right nerve ending, I believe, at the point of the penis, supplying the glans. It is probably in this way that crushes of the kidney and testicle are so often followed by vomiting; the connection of the nerve with the ovaries and uterus may explain to a certain extent the vomiting of pregnancy, the globus hystericus, etc. Certain it is that the vagus is the nerve most intimately connected with emotions, whether of joy or sorrow, and very probably, from its effect on the heart, some have been said to die of a "broken heart," and others from excess of joy, from the too great effect on the inhibitory centre. In concussion of the upper part of the cord, the vagus is often affected, producing a sense of suffocation, irregular action of the heart, and vomiting. Strong counter irritation applied over the course of the vagi, between the mastoid process and the angle of the jaw, has been found of great service in cholera, and has also acted like magic in cases of whooping-cough (INGLOTT).

3. The Spinal Accessory.—This is purely a motor nerve, and supplies the trapezius and sterno-mastoid; it also gives motor fibres to the vagus for the pharynx and larynx. The inhibitory nerve of the heart also comes from this nerve, and enters the vagus through the upper ganglion. This nerve is also affected in certain forms of "Torticollis."

Hypoglossal Nerve (*ninth, Motor Linguae*).—It arises from the fourth ventricle, near the point of the calamus scriptorius, beneath the fasciculus teres. It leaves the skull, often in two bundles, through the anterior condyloid foramen, and then lies at first behind the internal carotid artery and internal jugular vein, next it passes between the artery and the vein, hooks round the occipital, and crosses the external carotid artery, and passes beneath the digastric and mylo-hyoid muscles to the tongue. Its **Branches** are—(a) *Descendens noni*, which forms a loop (*ansa hypoglossi*) with the *communicans noni*, and supplies both bellies of the omo-hyoid, the sterno-hyoid, and the sterno-thyroid muscles; (b) a *special branch* to the thyro-hyoid; (c) *branches* to the genio-hyoid, genio-hyoglossus, the hyoglossus, and the styloglossus; and lastly, it supplies the intrinsic muscles of the tongue.

In **Paralysis** of this nerve the tongue is *pushed* to the paralysed side. In long standing cases the paralysed half of the tongue atrophies; and this will take place, not only when the *root* of the nerve is affected, but also in pressure on its trunk—*e.g.*, in the anterior condyloid foramen.

In the disease known as **Glosso-labio-laryngeal Paralysis** (*Bulbar paralysis*) the deep origins of the hypoglossal, facial, spinal accessory, and the pneumogastric nerves—and probably also the glosso-pharyngeal—are affected; hence the progressive loss of power of the muscles of the tongue, soft palate, pharynx, larynx, and in the orbicularis oris. The disease consists in degeneration and atrophy of the large nerve cells in the anterior horns of the upper part of the cord, and the cells in series with these in the medulla, forming the deep origin of the above-mentioned nerves.

The nerves specially affected in **Hydrophobia** appear to be the deep origins of the hypoglossal, glosso-pharyngeal and vagus, and neighbouring parts of the medulla. In **Tetanus** the spinal cord is specially affected, together with the motor part of the fifth, the facial and spinal accessory. The hypoglossal may also be paralysed by sudden and forcible bending forwards of the head, as in leaping, when the nerve is probably crushed at the anterior condyloid foramen. It may also be affected by fractures through the foramen, or by disease involving it, *e.g.*, caries or necrosis.

LYMPHATICS.

Of the Head.—The student must remember that, in a general way, the course of the lymphatics is very similar to that of the veins, both superficial and deep, and when thinking therefore of the probable source of any given glandular enlargement, he has only to think where the veins near the glands come from, in order to reach the irritating focus; or conversely, when a malignant tumour is discovered in a given situation, he has only to think of the course of the veins, which will, as a rule, lead him to the enlarged glands. I do not think that the spread through the lymphatics is *merely* a mechanical washing along the stream, of “juices” or cells, for there can be little doubt that the spread is sometimes *against* the stream; and this fact seems to lend support to the theory that malignant tumours have a microbic origin, for only *life* can go *against* the stream.

The **Glands** of the head consist of two groups—(a) The occipital at the back of the head, along the attachment of the occipitofrontalis; (b) the auricular, near the upper end of the sternomastoid. They receive the lymphatics from the posterior and middle vertical zones of the head; the vessels follow the course of these occipital and posterior auricular veins. These glands will be enlarged in cases of disease affecting the scalp in these zones—as pediculi, impetigo contagiosum, favus, and eczema.

The Face.—The glands of the face, in front of the ear, are—The parotid, placed on the surface of that gland, and a few deeply in its substance; one or two, just under the zygoma; the buccal, on the buccinator muscle; and the submaxillary, set just below the body of the lower jaw, underneath the cervical fascia. The parotid receive the lymphatics from the anterior vertical zone of the head, the vessels following the course of the temporal veins to the front of the ear, and after passing through the superficial parotid glands, join the submaxillary group. These glands will therefore be enlarged in conditions like those already enumerated, and by boils about the upper eyelid, epitheliomatous sores in this region, septic scalp wounds, and erysipelas. There are also a few glands along the middle line of the neck, from the chin to the sternum, but especially towards the upper part.

The superficial lymphatics of the face accompany the corresponding veins, especially the facial, pass through the glands on the surface of the buccinator (*buccal*), and thence to the large submaxillary group. The submaxillary group receives the lymphatics of the rest of the face directly, including the lips, and are therefore affected in inflammatory and malignant diseases of the lips—as boils, epithelioma, hard chancre, herpes, malignant carbuncle, anthrax, cancerum oris, and actinomycosis.

The deep lymphatics of the face come from the mucous membrane of the nose, mouth, and pharynx and orbital fossa, accompanying the internal maxillary vein, and end in the deep parotid set of glands, and thence to the submaxillary and deep cervical groups. These glands will therefore be affected in malignant disease, simple inflammation, and septic and specific conditions of these parts—as malignant tumours of the nose, jaws, and tonsils, strumous inflammation of the nasal cavities, cancerous ulcers of the inside of the cheek, chronic inflammation of the faucial, pharyngeal, or lingual tonsils, coupled, no doubt, with the entrance of specific organisms, and in caries of the teeth.

The Neck.—The superficial glands are placed along the course of the external jugular vein, between the platysma and the sternomastoid; they are, however, most numerous at the lower part of the posterior triangle, and from thence they are connected with the axillary glands, and also receive communications from the occipital and posterior auricular groups of the head. The *deep* glands form a chain along the inner side of the carotid sheath, between it and the pharynx, œsophagus, and trachea, and extend from the base of the skull to the thorax. Above, they receive the intra-cranial lymphatics, and below, they communicate with the glands in the thorax; the vessels finally converge and empty into the right lymphatic ducts on the right side, and the thoracic duct on the left. It will be noted, therefore, that there are two possible ways in which the glands at the root of the neck may be affected in cancer of the mamma—from the axillary glands, or from those in the posterior mediastinum. The lymphatics from the larynx enter the deep cervical glands, as well as those of the œsophagus and pharynx.

It will be seen, therefore, that the glands of the neck may be enlarged from a variety of causes, of which the following are a few :—

1. Epithelioma and chancre of the lips and tongue,
2. Cancrum oris, charbon, and carbuncle of lips and face.
3. Diseases of the nose, orbit, mouth, and pharynx—
inflammatory and malignant.
4. Diseases of the scalp—as pediculi, eczema, impetigo
contagiosum, epithelioma, etc.
5. Carbuncle in the occipital region.
6. Secondary syphilis.
7. Chronic inflammatory affections of the tonsils.
8. Caries of the teeth.
9. Strumous inflammation.
10. Simple lymphoma, lympho-sarcoma, and lymphadenoma,
and probably leucocythæmia.
11. Otorrhœa.
12. Malignant disease of the larynx, pharynx, and œsophagus.

Wry Neck—Torticollis, or Caput Obstipum.—**Causes**—(1) It may be congenital, or it may follow measles or scarlatina. In the congenital form, the face on the same side develops less rapidly than on the other side, the eye becomes oblique, and the cervical spine curved. (2) Long-continued irritation, as from inflamed cervical glands under the sterno-mastoid; in this case the position is taken up no doubt to lessen direct pressure on the glands, but also from reflex contraction due to the irritation of the branches of the cervical plexus. (3) Disease of the cervical vertebræ (*caries*) and their ligaments. (4) Traction from the cicatrix of a burn. (5) Clonic or tonic contraction of the sterno-mastoid and trapezius of the same side, from irritation of the spinal accessory, or it may even be due to contraction of the platysma. (6) Paralysis of the opposite sterno-mastoid. In wry neck there is a threefold displacement of the head—(1) It is drawn downwards towards the sternum; (2) it is rotated from the affected side, so that the chin points over the opposite shoulder; and (3) it is inclined laterally to the affected side. As a cure for some forms of wry neck, it has been proposed to stretch the spinal accessory nerve; but this operation is hardly ever followed by any permanent

benefit, and if it is to be interfered with at all, it is better to cut it right through, or even to remove an inch or so out of the trunk of the nerve. Division of the sterno-mastoid is also practised for the relief of this deformity.

To Stretch the Spinal Accessory Nerve.—This nerve leaves the cranium, in the same sheath of dura mater as the vagus, by the jugular foramen, and after having passed through, is found lying, with the other divisions of the eighth pair, between the internal jugular vein and the internal carotid artery. It then passes downwards and backwards either in front of or behind the internal jugular vein, and appears below the posterior belly of the digastric, and close to, but below, the transverse process of the atlas, and enters the deep surface of the sterno-mastoid. The great **land-mark** for this operation is the prominent transverse process of the first cervical vertebra. In this region it may be exposed, and stretched or cut, by an incision along the upper part of the anterior border of the sterno-mastoid, commencing an inch below the mastoid process, and carried downwards for two or three inches. By dividing the superficial structures, and defining the anterior edge of the sterno-mastoid, and then defining the transverse process of the first cervical vertebra, the nerve will be found emerging from below the posterior belly of the digastric, curving round the process above indicated, from before backwards and downwards, and entering the deep surface of the former muscle. The incision must not be carried too far up, lest the external jugular vein (which lies midway between the angle of the jaw and the mastoid process) or the parotid gland be injured. The nerve is also crossed by the occipital artery, probably also by the sterno-mastoid artery.

Division of the Sterno-Mastoid.—The nervous supply of this muscle is in great part the spinal accessory nerve, but it also receives branches from the *second* cervical nerve through the cervical plexus; the second cervical communicates with the spinal accessory, and also with the superficial cervical and great auricular branches of the third cervical nerve. Any irritation therefore in the region of distribution of these nerves, as inflamed glands, will readily throw the sterno-mastoid into contraction reflexly; the same thing will also occur in disease of the upper three cervical

vertebræ. The part which most frequently requires division is the sternal head, but both heads may be divided. In doing so it is well to bear in mind the proximity of important structures, *e.g.*, the internal jugular vein, and several veins passing to join it, lie behind the muscle, opposite the interval between its two heads, and if care be not taken the operation may be followed by a fatal result; further, the external jugular vein is often close to its *outer* border, and the anterior jugular at its *inner*. The incision should be made from behind forwards, close to the sternum, and along the clavicle, and if this be done, there is little risk of doing any damage; the tension of the muscle tends to make it project forwards, and away from the carotid sheath. The following method is that recommended by ERICHSSEN:—For the *sternal* head make a puncture on the inner side of the tendon with a sharp scalpel, and then push a narrow director behind the muscle, and after that pass an ordinary tenotome between the director and the tendon flatwise, turn it and then cut forwards. In dividing the *clavicular* insertion make a puncture with a scalpel upon and down to the clavicle in the space between the two heads of the muscle, and then push a blunt-pointed, narrow-bladed tenotome between that bone and the insertion of the muscle, and cut forwards, or a director may be used as in the last case. In children the muscle may also be divided about its centre by passing a tenotome behind the muscle, from without inwards, putting it on the stretch and then cutting forwards.

The Deep Fascia of the Neck.—This is attached behind to the spinous processes of the cervical vertebræ. It splits to enclose the trapezius muscle, and then the two layers join to form the roof of the posterior triangle of the neck; it again splits to enclose the sterno-mastoid and the depressor muscles of the hyoid bone, and then unites across the middle line with the fascia of the opposite side. This layer is attached—**above**, to the base of the lower jaw, the zygoma, mastoid process, the superior curved line and the protuberance of the occipital bone; **below**, to the upper and posterior part of the manubrium sterni, clavicle, acromion process, and spine of scapula. If pus forms beneath this layer, it will in all probability find its way into the anterior mediastinum, or else bag over the sternum.

From the deep surface of this layer, as it ensheaths the sternomastoid, a strong process passes inwards across the neck, and forms the carotid sheath, and then passes in front of the pre-vertebral muscles, but behind the pharynx and œsophagus, to unite with the layer of the opposite side. This part is attached **above** to various points at the base of the skull, and specially to the angle of the lower jaw and the styloid process, and the part intervening between these two points is known as the *stylo-maxillary ligament*, which separates the parotid from the submaxillary gland. As this layer passes down, it divides into two parts. One is placed beneath the depressors of the hyoid bone, invests the thyroid body and at the sides is attached to the first rib and binds down the central tendon of the omó-hyoid muscle to that bone, while the central part passes down in front of the trachea and large vessels and becomes continuous with the fibrous pericardium. The other layer passes into the thorax in front of the pre-vertebral muscles but behind the œsophagus. If pus form in *front* of the former it will most likely find its way into the axilla at the side, or anterior mediastinum in front; if *behind* it, it will gravitate towards the apex of the pleura and lung at the sides, or middle mediastinum in front; if it form *beneath* the latter division, it will tend to pass into the posterior mediastinum.

CHAPTER XXXI.

THE UPPER EXTREMITY.

THE more important points about the surface Anatomy have already been indicated when speaking about fractures and dislocations. I would only point out the groove on each side of the biceps in the upper arm: the outer one corresponds pretty closely to the course of the cephalic vein, and the inner to the brachial artery and the basilic vein. On the outer side the groove is continued upwards between the pectoralis major and the deltoid; in this part of the groove we find (1) the cephalic vein, (2) the humeral branch of the thoracic axis, and (3) at its upper end one or two lymphatic glands which communicate both *over* and *under* the clavicle with glands in the base of the posterior triangle.

THE AXILLA.

In describing this space, note—(a) **Position.**—It is a space between the upper part of the arm and the upper part of the side of the chest. (b) **Shape.**—In shape it resembles a four-sided pyramid, but the sides are not equal—the inner side is much larger than the outer, and the posterior wall extends further down than the anterior. (c) **Boundaries.**—The *base* is formed by the integuments and the strong axillary fascia: the *apex* is directed upwards towards the root of the neck, and corresponds to an interval between the first rib, clavicle, and upper border of the scapula, and is triangular in shape. The *anterior* wall is formed by the pectoralis major and minor: *behind* are the subscapularis, latissimus dorsi and teres major: to the *inner* side, the upper five or six ribs with their intercostal muscles, and the upper part of serratus magnus: the *outer* wall is formed by the coraco-

brachialis, short head of biceps, and head and neck of humerus.

(*d*) The Contents:—

1. The axillary artery and its branches.
2. The axillary vein and its tributaries.
3. The brachial plexus of nerves and its infra-clavicular branches.
4. Lymphatic glands, fat, and areolar tissue.
5. Lateral cutaneous branches of the upper three or four intercostal nerves.
6. Nerve of BELL.

1. Glands of the Axilla.—The lymphatic glands of the axilla are arranged in three sets—(1) One group lies along the sub-scapular artery in the posterior fold of the axilla. (2) Another group accompanies the long thoracic artery in the anterior fold of the axilla. One or more of the glands of this set will often be found, and should always be looked for, between the two pectorals. (3) A third set is placed along the axillary artery, extending up into the neck beneath the clavicle to join the cervical glands. The posterior group receives lymphatics from the side of the chest and back; the anterior group, from the front of the chest and mamma; while those placed along the axillary vessels receive the lymphatics from the fore-arm and hand, and upper limb generally. A knowledge of these facts is of practical value, because disease in the parts from which the lymphatic vessels come will point to the group of glands likely to be affected; thus, in disease of the mamma (*e.g.*, cancer) the anterior group will be enlarged, and in a poisoned wound of the hand the group along the axillary artery will be affected, and so on. The rest of the lymphatic glands of the upper extremity are few and small, but there are usually one or two a little above the internal condyle, near the basilic vein, which are enlarged in syphilis and septic wounds of the fingers and hand. A few glands are also placed immediately beneath the clavicle, forming a connecting link between the cervical and the axillary glands. Mr BELL used to teach us that, clinically, the glands about the axilla should be classified into those (*a*) above the deep fascia, and (*b*) those below it. In the former case the patient, when the glands are

inflamed, can readily abduct his arm, but in the latter he is unable either to abduct it actively or allow it to be abducted by the Surgeon.

According to Dr CREIGHTON there is a special series of sweat glands, more or less developed below the skin of the axilla, which corresponds to a conglobate form of gland found in one of the lowest mammalians; the glands have a basement membrane of non-striped muscular tissue, upon which the cells are seated. They lie between the skin and the axillary fascia, sometimes extending to the lateral and anterior part of the chest wall; they may be regarded as belated survivals, and are subject to all the risks, as regards malignant disease, of such survivals or rudiments. Somewhat similar glands are also found in the areola round the nipple. Malignant disease may arise in these glands and have no connection, in the first instance, either with the breast or the axillary lymphatic glands; it is possible that the cases known as "alveolar sarcoma, or "duct cancer of the breast," may be malignant disease of these glands. So also the eczema of the nipple that often precedes malignant disease of the breast. When such growths ulcerate they resemble rodent ulcer (Sir SPENCER WELLS).

2. Abscess in the Axilla.—If pus forms in the axilla, it will be unable to make its way to the surface through the base of the space on account of the strong axillary fascia which is found in this region; it cannot pass back because of the serratus magnus and the fascia covering it, nor forwards because of the strong clavipectoral fascia and pectoral muscles, nor inwards because of the chest wall; it will therefore rather burrow up towards its apex, as there is least resistance in this direction, and point in the neck, or may sometimes open into the pleura and apex of lung or pass into the mediastina. The necessity, therefore, of making an early and free incision for its evacuation is evident. Abscess *between* the pectoral muscles is shut out from the axilla by the costo-coracoid membrane and fascia enclosing the lesser pectoral, and will, therefore, tend to point at the anterior edge of the axilla, where it should be opened by "HILTON'S method."

3. The Relation of the Contents of the Axilla to its Walls.—In the **outer wall** are the large axillary vessels and nerves; in the **anterior wall** there is a large vessel—the long thoracic artery;

in the **posterior wall** there is also a large vessel—the subscapular artery; and in the **inner wall** we find the nerve of BELL and the superior thoracic artery, but the artery is small and placed high up. In making incisions, therefore, into the axilla, as for the evacuation of pus, the operator must cut *towards the inner wall* in order to avoid the important structures in relation to the other walls of the space, or else use HILTON'S method.

4. **Pressure on the Nerves and Vessels of the Axilla.**—Pressure on the brachial plexus, as from a tumour in the axilla, or in sub-glenoid dislocation of the humerus, will cause a severe numb pain to be felt in the hand and arm. The pressure on the artery may arrest the radial pulse, and pressure on the main vein will cause œdema of the hand and arm. When the group of glands along the axillary vessels are enlarged, as in poisoned wounds of the hand, or in cancerous tumours of the breast, the vein suffers most, as the glands are nearer it and its walls are thin; œdema of the hand and arm, therefore, in cancerous tumours of the breast is a grave symptom, as it shows that the disease has passed through the anterior set of glands and involved the deeper set along the main vessels, passing up towards the supra-clavicular glands. As cancer always grows *towards* the best blood supply, in the case of the breast, it stretches along the lymphatics and vessels in the anterior fold of the axilla forming a *tail-like* growth. The pressure of a crutch, the pressure of an axillary pad in fracture of the clavicle, and the pressure caused by the arm hanging over the back of a chair (as in drunk persons), may also partially paralyse one or more branches of the axillary plexus.

THE BRACHIAL PLEXUS.

The Brachial Plexus is formed by the anterior primary divisions of the fifth, sixth, seventh, and eighth cervical nerves, and half of the first dorsal; it also receives a branch from the fourth cervical nerve. They lie in grooves on the upper surface of the transverse processes of the cervical vertebræ, and appear in the neck between the scalenus anticus and the scalenus medius muscles; here they lie in the posterior triangle of the neck (clavicular part), and they then pass between the clavicle and the first rib into the axilla as far as the coracoid process, or the

insertion of the pectoralis minor, where it forms its three cords. The three cords are formed thus:—The fifth and sixth unite to form a single trunk; the seventh passes down alone; the eighth cervical and the first dorsal unite to form another trunk. The three cords formed in this manner then divide each into an anterior and posterior branch; the anterior branches of the upper and middle join to form the *outer* cord; the anterior branch of the lower forms the *inner* cord, while the posterior branches all unite to form the *posterior* cord. Its branches are divided into (a) supra-clavicular, and (b) infra-clavicular.

The **Supra-Clavicular** branches are:—(1) Communicating to the phrenic (from the fifth); it joins the phrenic on the scalenus anticus. (2) Nerve to rhomboids (from fifth). (3) Nerve of BELL, by two heads (from the fifth and sixth). (4) The supra-scapular, from the posterior part of the cord formed by the fifth and sixth. (5) Nerve to the subclavius, from the anterior part of the cord formed by the fifth and sixth, and which passes down, in front of the third part of the subclavian, to the muscle.

The **Infra-Clavicular** branches are:—

From the *outer* cord—

- (1) External anterior thoracic.
- (2) Outer head of median.
- (3) Musculo-cutaneous (*perforans Casserii*).

From the *inner* cord—

- (1) Internal anterior thoracic.
- (2) Inner head of median
- (3) Ulnar.
- (4) Internal cutaneous.
- (5) Lesser internal cutaneous (nerve of WRISBERG).

The nerve of WRISBERG is joined by the intercosto-humeral nerve—which is the undivided lateral cutaneous branch of the second intercostal, usually; occasionally, however, there is sometimes an intercosto-humeral nerve from the third intercostal.

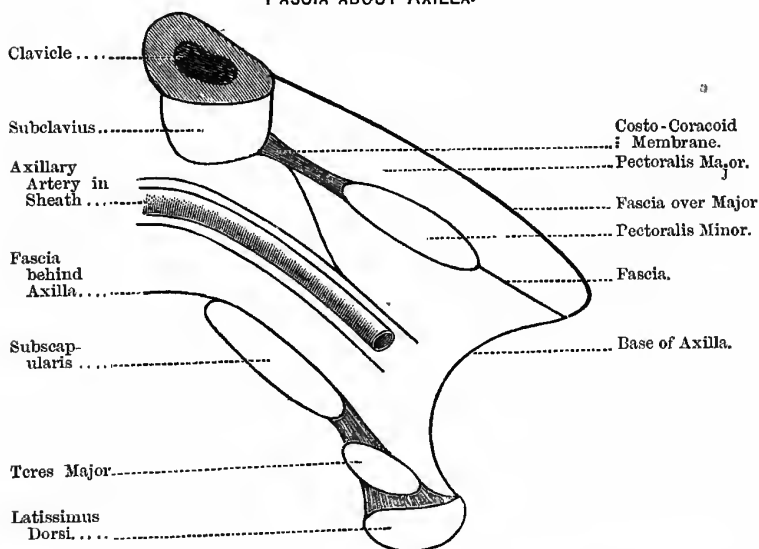
From the *posterior* cord—

- (1) Musculo-spiral.
- (2) Circumflex.
- (3) The three subscapular nerves.

The Costo-Coracoid Membrane.—This is a process of the deep cervical fascia situated under the clavicular head of the great pectoral; externally it is attached to the coracoid process of the scapula, internally to the first rib, and between these two points to the under surface of the clavicle, in a double fold, one in front and one behind, forming the sheath of the subclavius muscle. Immediately below the subclavius it thins considerably, forming a

Fig. 153.

FASCIA ABOUT AXILLA.



crescentic margin, which is sometimes called the “costo-coracoid ligament.” The fascia is continuous—above, with the deep cervical fascia; on the under surface, with the sheath of the axillary vessels; and below, it joins the sheath of the pectoralis minor (Fig. 153). It encloses the subclavius muscle, and the following structures pierce it:—(1) The cephalic vein; (2) the external anterior thoracic nerve; (3) the thoracic axis, or the acromio-thoracic artery; (4) the superior thoracic artery (if present); and (5) corresponding veins.

The Axillary Fascia.—This is a dense sheet of fascia forming the floor or base of the axilla. It becomes continuous on the *inner* side with the fascia over the serratus magnus; at the *outer* side it is continuous with the deep fascia of the arm, and receives fibres from the tendons of the latissimus dorsi and teres major; it also becomes continuous with the deep fascia ensheathing the muscles forming the anterior and posterior walls of the axilla. In this way a strong fascial chamber is formed, open only at the upper part of the root of the neck. In operations in the axilla care must be taken to prevent the entrance of air into the large axillary vein. This is apt to take place—first, because of its position so close to the chest, and therefore subject to the aspirating power of that cavity during inspiration; and, secondly, because it is surrounded and held open by the dense fascia of this region.

THE BEND OF THE ELBOW.

The Triangle in Front of the Elbow Joint (*antecubital fossa*).—This space is bounded—on the *outer side*, by the supinator longus; on the *inner side*, by the pronator radii teres; the *base* is an imaginary line drawn across the arm at the level of the condyles; the *apex* is the meeting of the supinator longus and the pronator radii teres. The *roof* is formed by the skin, the superficial and deep fascia, cutaneous nerves, median cephalic and median basilic veins; the *floor* is formed by the supinator brevis and the tendon of insertion of the brachialis anticus.

The **Contents**, from within outwards, are:—(1) The median nerve. (2) The brachial artery, with its venæ comites; the artery in this space divides into its radial and ulnar branches. (3) The tendon of the biceps. (4) By pulling the supinator longus outwards a little, the musculo-spiral nerve will be seen dividing into radial and posterior interosseous, and also the anastomoses between the radial recurrent and superior profunda; and by displacing the pronator radii teres a little inwards, the anastomoses between the anterior ulnar recurrent, inferior profunda, and anastomotica.

The **bursa over the olecranon process** is very apt to be injured by falls or blows, in workmen especially, and very frequently the little sac is opened; in this way septic matter gets in through the small opening, gives rise to a septic spreading inflammation and

pus formation, but the pus and other matters cannot escape, as the opening is too small, and it also tends to become sealed up. In this way an appearance, very like that of erysipelas, is produced, the entire region about the elbow being of a bright red colour and very tender to pressure; the edge of the redness is rarely, however, so sharply defined as in erysipelas.

The **Treatment** is to lay the bursa completely open and apply an antiseptic fomentation and keep the arm at rest.

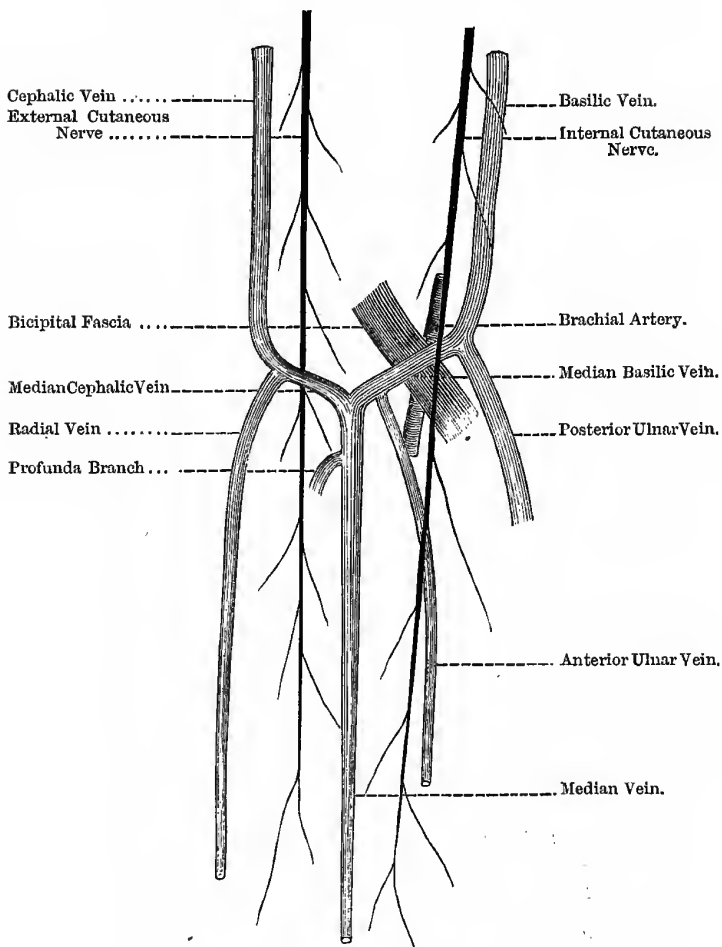
Veins at the Bend of the Elbow (Fig. 154).—Passing up the centre of the fore-arm is the median vein, which, when it reaches the hollow in front of the elbow joint, divides into the median basilic and the median cephalic veins. The median cephalic is joined by the radial vein, then passes up the arm as the cephalic vein, and empties itself into the axillary vein. The median basilic is joined by the anterior and posterior ulnar veins, then passes upwards as the basilic vein, and about the middle of the arm pierces the deep fascia, and is joined by the venæ comites of the brachial artery, and is then known as the axillary vein. The posterior ulnar begins at the inner border of the hand and vein of the little finger—“*vena salvutella*.” At the bend of the elbow the median basilic vein overlies the brachial artery, but is separated from it by the semi-lunar or bicipital fascia, and the internal cutaneous nerve passes over or under it, while the external cutaneous passes under the median cephalic.

Venesection at the Bend of the Elbow.—Either of these (median cephalic or median basilic) may be opened. The median basilic is the larger, and more easily compressed and fixed, because it has the firm bicipital fascia behind it, and it is also more superficial than the median cephalic; its great disadvantage is that it lies just over the brachial artery, so that if the operation be performed carelessly, or if the patient start during the entering of the lancet, it may pass through the vein and fascia into the artery beyond. The median cephalic is not quite so large, although it is large enough to afford a good stream of blood, but it is separated by a considerable interval from the brachial artery.

Instruments required.—A yard of broad tape, a lancet, a cylindrical piece of wood for the patient to grasp in his hand, a vessel to catch the blood, and dressings.

Fig. 154.

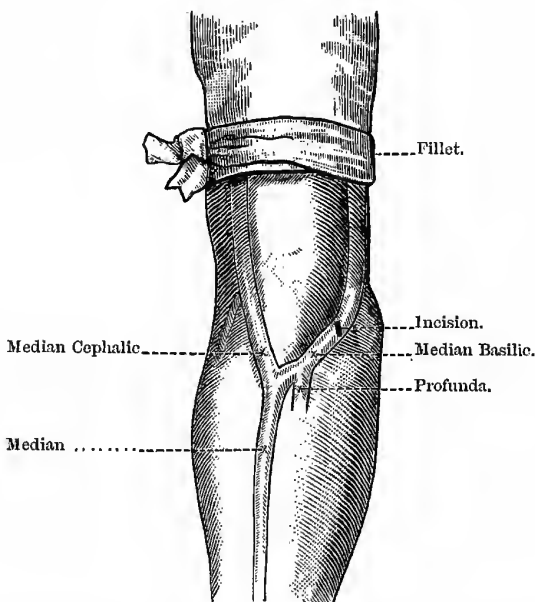
VEINS AT THE BEND OF THE ELBOW—RIGHT SIDE.



Operation.—Whichever vein be chosen, the steps of the operation are practically the same—(1) A bandage is tied round the arm above the point where the vein is to be opened, to make it “rise,” but must not be drawn too tightly lest the flow through the brachial artery also be checked (Fig. 155). (2) The thumb of the Surgeon’s left hand is then drawn upwards over the course of the vein for a little way, and firmly pressed upon it, just below the point

Fig. 155.

VENESECTION.



where it is to be opened, in order to steady it, and also to fill the vein tightly between the bandage and the thumb. (3) The point of the lancet is then pushed into the vein and made to cut an *oblique* opening—because if longitudinal the flow is too meagre, and if transverse the vein might be completely divided—taking care that the opening in the skin is larger than that in the vein, lest blood escape into the cellular tissue and give rise to

“thrombus.” If the flow be sluggish, the patient should move his fingers while he grasps something firm in his hand, so as to compress the deep veins and cause the blood to flow into the superficial set through the profunda communication. When enough blood has been extracted, place the thumb over the wound, and remove the bandage or “fillet,” bend the arm and apply a compress of lint, and fix it by a figure-of-eight bandage and sling the arm.

If the artery be punctured during the operation, this injury will be manifested by (1) the blood being redder than it should be, (2) that it escapes in jerks, and (3) pressure on the vein below the opening does not stop the bleeding. The results of such an accident are various: it may lead to—(1) A *False Aneurism*, that is, the blood poured from the artery may be enclosed in a sac, not formed by the coats of the vessels as in true aneurisms, but by the surrounding tissues. (2) It may lead to an *Aneurismal Varix*, that is, when the wounded artery and vein adhere at the wounded point, and jets of blood are driven into the vein from the artery, dilating it, and causing incompetency of its valves, and leading to a varicose state of the veins in the neighbourhood. (3) It may lead to a *Varicose Aneurism*, that is, an aneurism the sac of which communicates with both artery and vein, and blood from the artery is projected into the vein through the sac of the aneurism. Other risks of this operation are (4) septic lymphangitis from the use of a dirty lancet; (5) sometimes a very painful neuralgic condition results, probably from the cutaneous nerve of the corresponding side being involved; and, (6) less frequently, “bent arm” results, probably from some injury to the cutaneous filaments of the musculo-cutaneous, setting up irritation and causing reflex contraction of the biceps and brachialis anticus (HILTON).

The **Lowest Lymphatic Gland** of the upper extremity is placed a little above the internal condyle, towards the anterior aspect of the arm. It very frequently inflames and suppurates as a result of poisoned wounds of the inner part of the hand and the inner fingers, as it arrests the poison (*ptomäine*) before it reaches the axillary glands. It is also very constantly enlarged during the
 — stage of acquired syphilis, and forms a readily accessible

Synovial Membranes of the Wrist.—These are *five* in number—(1) The membrana sacciformis, which lines the lower end of the ulna, the sigmoid cavity of the radius, and the upper surface of the triangular fibro-cartilage. (2) The second lines the wrist joint proper—*i.e.*, the end of the radius and the triangular fibro-cartilage above, and the scaphoid, semi-lunar, and cuneiform bones below. (3) The third is the most extensive; it covers the contiguous surfaces of the two rows of carpal bones, and, passing between the bones of the second row, lines the carpal ends of the four inner metacarpal bones. (4) The fourth lies between the trapezium and metacarpal bone of the thumb. (5) The fifth is between the pisiform and the cuneiform bones. We see, therefore, that one synovial membrane (the third) does for all the carpal bones except the pisiform, and also for all the metacarpal bones except the first (that of the thumb).

The Musculo-Spiral Nerve.—This nerve arises from the posterior cord of the brachial plexus, lying at first behind the third part of the axillary and upper part of the brachial artery, passing in front of the tendons of the latissimus dorsi and teres major; it then winds round the humerus in the musculo-spiral groove with the superior profunda artery, passing from the inner to the outer side of the bone, between the internal and external heads of the triceps. It pierces the external inter-muscular septum, and descends between the brachialis anticus and the supinator longus to the front of the external condyle, where it divides into posterior interosseous and radial nerves. The **Muscles** supplied by this nerve are—(1) The triceps—the twig to the inner head is a long, slender filament, which lies close to the ulnar nerve as far as the lower third of the arm; (2) the anconeus—a long, slender filament which tunnels the substance of the triceps to reach the anconeus; (3) a branch to the brachialis anticus; (4) the supinator longus; and (5) the extensor carpi radialis longior. **To Expose this Nerve**, for the purposes of stretching, the edge of the supinator longus is used as the **guide**, and the nerve reached as it lies between that muscle and the brachialis anticus. We simply cut through the skin, superficial fascia, and fatty tissue; define the edge of the supinator longus, cut through the deep fascia, and find the nerve lying on the brachialis anticus.

The Median Nerve.—This nerve arises by two roots, one from the outer and the other from the inner cord of the brachial plexus, which join either in front or to the outer side of the axillary artery. It then lies to the outer side of the third part of the axillary and the upper part of the brachial; it then crosses the brachial very obliquely, and lies on its inner side, at the bend of the elbow, beneath the bicipital fascia. It enters the fore-arm by passing between the two heads of the pronator radii teres, lies on the flexor profundus, covered by the flexor sublimis, to within two inches of the wrist joint, where it becomes more superficial, lying between the tendons of the flexor sublimis and the flexor carpi radialis, beneath, or rather to the *ulnar* side of, the tendon of the palmaris longus. This nerve supplies *directly* four muscles in the fore-arm—the pronator radii teres, the flexor carpi radialis, the palmaris longus, and the flexor sublimis digitorum: by its *anterior interosseus branch* it supplies the flexor longus pollicis, the pronator quadratus, and part of the flexor profundus. In the *hand* it supplies the abductor pollicis, the opponens pollicis, half of the flexor brevis pollicis, and the two outer lumbricales—the first and second. **To Expose this Nerve**, for the purposes of stretching, make a short median incision just to the ulnar side of the palmaris longus, the tendon of this muscle being used as the **guide** to the nerve. The only structures divided are the skin and superficial and deep fascia.

Results of Paralysis.—(1) Loss of the power of flexion in the second phalanges of all the fingers, and in the third phalanges of the index and middle fingers; (2) the thumb is extended and adducted, and can neither be flexed nor opposed; and (3) pronation is lost entirely. On account, however, of the activity of the *ulnar nerve*, we find—(1) The power of partial flexion of the ring and little fingers at the third phalanges, through the ulnar half of the flexor profundus; (2) the power of flexing of the first phalanges, and extending the other two through the interossei; and (3) the power of flexing the wrist at the ulnar side by the flexor carpi ulnaris, best seen when the hand is adducted.

The Ulnar Nerve.—It arises from the inner cord of the brachial plexus, and lies to the inner side of the axillary and brachial

arteries; about the middle of the arm it leaves the brachial artery, and runs obliquely across the internal head of the triceps, pierces the internal intermuscular septum, and descends to the groove between the internal condyle of the humerus and the olecranon process of the ulna, accompanied by the inferior profunda artery. It enters the fore-arm by passing between the two heads of the flexor carpi ulnaris, passes straight down, lying upon the flexor profundus digitorum, and covered by the flexor carpi ulnaris; for the lower two thirds of its course it lies to the inner side of the ulnar artery, and between the tendons of the flexor sublimis and the flexor carpi ulnaris, and at the wrist crosses the annular ligament, and enters the palm. The **guide** for this nerve is the pisiform bone and the tendon of the flexor carpi ulnaris; it lies immediately to the outer or radial side of these structures. This nerve supplies the elbow and wrist joints, and the following muscles—in the *fore-arm*, the flexor carpi ulnaris and the inner half of the flexor profundus; in the *hand*, the palmaris brevis, all the intrinsic muscles of the little finger, all the dorsal and palmar interossei, the third and fourth lumbricales muscles, the adductor pollicis, and the inner head of the flexor brevis pollicis.

Results of Paralysis.—(1) Impaired flexion of the ring and little fingers; (2) impaired ulnar flexion of the wrist; (3) the action of the interossei and of the two inner lumbricales lost; and (4) the thumb cannot be adducted, and the action of the flexor brevis is impaired.

The Sheaths of the Flexor Tendons.—When erysipelatous inflammation attacks the sheaths of the flexor tendons in the fingers (whitlow), or more frequently in the case of septic wounds, there is great pain, owing to the resistant nature of the structures attacked, and consequent tension, and it is at the same time fraught with danger to the utility of the finger or hand. Pus forms very rapidly, and finds its way up the synovial sheaths of the flexor tendons to the hand and common synovial sheath under the anterior annular ligament; and, if the disease be not checked by timely interference, the sheaths and tendons are rapidly destroyed, the joints of the fingers injured, and the phalanges may even necrose or the finger become gangrenous, and the erysipelatous inflammation extend up the fore-arm. Suppuration occurring in

the sheaths of the tendons of the little finger, or thumb, is far more likely to involve the common sheath under the anterior annular ligament than when it occurs in any of the other fingers; this is because the synovial sheaths of the flexor tendons of the thumb and the little finger communicate directly with the common sheath, while those of the three other fingers do not; but in no case, however, is the distance between the common sheath and the synovial sheaths of the flexor tendons great—usually about a quarter of an inch. To check the spread of the inflammation and relieve the tension, it is advisable either to foment the finger with warm water, or make an early and free longitudinal incision into the finger, and if the pus has formed *within* the sheaths, make an incision down to the bone at once, or, in the case of septic wounds, immerse the whole hand in a warm boracic acid bath. If pus form or accumulate in the common synovial membrane under the anterior annular ligament, the appearance presented is peculiar—there is a swelling in the palm and another in the lower part of the fore-arm, with a constriction between, caused by the annular ligament. In opening a palmar abscess, always cut *on* a metacarpal bone parallel with its long axis, and towards its head, to avoid the digital nerves and vessels. Also avoid going too near the root of the thumb lest the superficial palmar arch be injured.

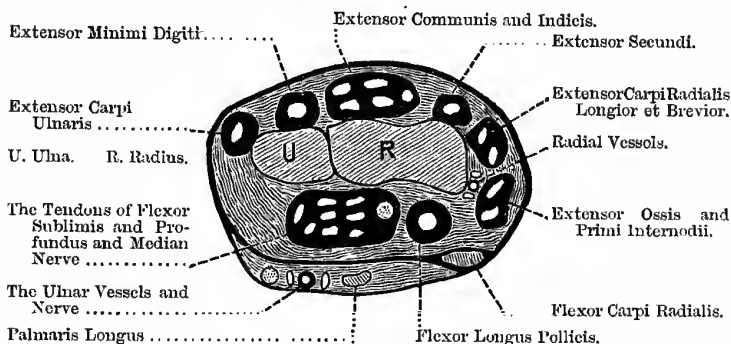
The Anterior Annular Ligament.—Passing **beneath** this structure, and enveloped by a common synovial sheath, we find—(1) The tendons of the flexor sublimis; (2) the tendons of the flexor profundus; (3) the tendon of the flexor longus pollicis; and (4) the median nerve. The tendon of the pollicis, however, has usually a synovial sheath to itself. Passing **over** the ligament, we find—(1) The tendon of the palmaris longus, (2) ulnar vessels, (3) ulnar nerve, and (4) cutaneous twigs of the ulnar and median nerves to the palm. Passing **through its substance** is the tendon of the flexor carpi radialis (Fig. 156).

The Posterior Annular Ligament has six compartments, corresponding with grooves on the bones. The first, on the outer side of the styloid process of the radius, transmits the tendons of the extensor ossis metacarpi pollicis and extensor primi internodii pollicis; the second transmits the tendons of the extensores carpi

radialis longior et brevior; the third is oblique, and transmits the tendon of the extensor secundi internodii pollicis; the fourth, the tendons of the extensor communis digitorum and the extensor indicis; the fifth is placed between the bones, and transmits the tendon of the extensor minimi digiti; and the sixth, on the back of the styloid process of the ulna, transmits the tendon of the extensor carpi ulnaris (Fig. 156).

Fig. 156.

SECTION OF THE WRIST.



Whitlow is usually defined as an erysipelatous inflammation of the finger; it is no doubt usually septic in its character. The **Varieties** usually enumerated are:—

1. Mere inflammation of the cutaneous structures about the root of nail, with usually a drop of pus beneath the cutis.
2. In the fibrous tissue of the pulp, which is apt to spread to the periosteum and cause necrosis of the terminal phalanx, from interference with the blood supply, and the absence of the tendon sheath.
3. *In* the sheath of the tendon or "true thecal abscess." Mr DUNCAN, however, teaches that this variety is, in all probability, non-existent as a *primary* affection, though it may spread from the soft tissues or from the bone, and involve the sheath secondarily.

A slight variation of this classification would probably be more correct, thus:—

1. The superficial form, between the two layers of skin or round the root of the nail.
2. In the cellular tissue, from a poisoned wound, and in some cases idiopathically.
3. Under the periosteum, usually only of the terminal phalanx, and leading to necrosis of part of phalanx.
 - (a) As a primary "acute necrosis."
 - (b) Secondary to the cellular tissue whitlow.
4. In the sheath of the tendon—
 - (a) As a result of tension and burrowing, because not opened sufficiently early.
 - (b) Caused by the Surgeon opening the sheath of the tendon when incising a cellular tissue whitlow. This infects the synovial sheath with septic material, and the usual results are—spread of the inflammation, sloughing of the tendons, and a useless finger. It is unnecessary, and even harmful in such cases, to "cut down to the bone."

In opening a Whitlow, two things must be attended to—(1) To have something firm (wood or stone) behind the patient's hand; in this way the hand cannot descend from the knife, it can only be drawn back. (2) Cut with the edge of the knife directed towards the tip of the finger, so that, as the hand can only be pulled back and not depressed, the incision will be enlarged in the proper direction, and no injury done to patient or Surgeon. As in all probability, whitlow *never begins* in the sheath of the tendon, it is unnecessary to open into the sheath—in fact, such an incision will do more harm than good; in cases where it is involved secondarily, it must be opened, but such a case will probably come to amputation. Whitlow is most often seen in the terminal phalanges, or else in the first phalanges, close to the palm. The *œdema on the back of the finger or hand* must not mislead the student as to the true seat of the suppuration; the tissues on the palm are too dense to become œdematous.

The term **Paronychia** (*παρὰ*, beside, and *ὄνυξ*, the nail), is properly applied to inflammation or suppuration round the root of the nail; it is sometimes used as if it were synonymous with "whitlow," but it had better be restricted to the above meaning.

GANGLION.

The synovial sheaths of the tendons round the wrist are frequently the seat of **Ganglia**. Chronic ganglia are usually divided into two kinds—simple and compound. **Simple Ganglion** is supposed to have four possible modes of origin—(1) as a cystic enlargement of a cell in one of the fringes of the sheath; (2) a partial hernia of the sheath that has become cut off from the main tube; (3) from the dilatation of sub-synovial follicles; and (4) it may possibly originate as a hernia from the synovial membrane of some of the joints in the neighbourhood. The simple form is the ganglion proper. It is most common on the *extensor* tendons of the fingers, thumb, or wrist—especially towards the radial side of the hand, but it is also found on the corresponding part of the foot; it usually contains a clear, jelly-like substance, resembling in consistence and appearance the eye of a cod-fish, or semi-solid glycerine. It should be ruptured subcutaneously by squeezing it with both thumbs against the bone beneath, or by giving it a heavy blow with a book of some size; after this, apply pressure with pad and bandage. Blisters and iodine are sometimes used. Should these plans fail, then puncture it subcutaneously with a clean tenotomy knife, and squeeze out the thick, jelly-like fluid, and afterwards apply firm pressure.

Compound Ganglion is the dilatation of a tendon sheath itself, or of several tendon sheaths; it is not, properly speaking, a ganglion at all, being more of the nature of chronic synovitis, or hydrops of the sheath. It is usually found in the *flexor* sheaths, under the annular ligament and the lower part of the fore-arm. There are two *varieties*—(a) consisting of simple serous fluid alone, and (b) that with melon seed bodies as well; the latter form may be made to crackle and gurgle as the "seeds" are squeezed from one part of the sheath to the other, or through the narrow part of the hour-glass-shaped sheath below the anterior annular ligament. For the first variety, simple puncture or tapping, with pressure

and rest upon a splint afterwards, may be enough. If not, and should it pass under the annular ligament, make a small incision above, and another below, the annular ligament, and drain with an ordinary tube, catgut, or horse-hair for a few days, with strict antiseptic precautions. Should it be septic or suppurating in the first instance, or unfortunately become so during treatment, then we may use SYME'S plan of completely dividing the anterior annular ligament; but first patiently try the effect of a continuous warm boracic lotion bath. For the form with melon seed bodies, a puncture must always be made in the first instance, to let them out, then treat with pressure, and rest on a splint; otherwise, the treatment is the same as in the serous variety. Be very careful and particular about antiseptic precautions in these operations, as an error in this respect may cost the patient his hand or even his life. In cases where the large sheath under the anterior annular ligament is very full or much enlarged, fluctuation can readily be felt between the hollow in the palm, and the lower part of the fore-arm, above the annular ligament. In order to make an opening into this collection for the purposes of drainage, make an incision a little to the ulnar side of the palmaris longus, just sufficiently far to avoid the median nerve, squeeze out the melon seed bodies, and then insert a catgut or horse-hair drain. In order to make drainage free, it may be necessary to divide the anterior annular ligament subcutaneously with a probe-pointed bistoury. In cases where the sheath does not project much, press a thumb on the hollow between the thenar and hypo-thenar eminences, when a prolongation of the sheath will be made to project above the ligament, to the ulnar side of the palmaris longus, at the exact place where the upper opening should be made.

"Dupuytren's Contraction."—This is a chronic, inflammatory thickening and contraction of the palmar fascia, especially of its digital prolongations; the contracted bands begin at the line of transverse flexion of the palm, and the flexion is most marked opposite the second phalanx. The disease begins as a hard knot in the palm, about the level of the transverse line of flexion, and opposite the root of the ring finger; this finger is then gradually bent into the palm; the little finger is next affected, and it is often more bent than the ring finger; the other fingers are not much

affected, and the thumb never, as it has no prolongation from the palmar fascia. The fascia contracts very dense adhesions to the skin, and perhaps a little to the tendon sheath. The *tendons* are not affected, because the carpo-metacarpal joints are most contracted; if it were the tendons, it would be the other two. The condition is often symmetrical, and occasionally the feet are affected as well. **Cause.**—It is most frequently found in the well-to-do, and, therefore, cannot be due to any special position of the hand at work, as with round-headed tools, etc. It is probably associated with some special constitutional diathesis, as the gouty and the rheumatic, since the small joints are often enlarged in this affection, just as they are in chronic rheumatic arthritis. Alcohol has probably a good deal to answer for as a cause.

Treatment.—When the disease is beginning, as the hard palmar knot, try what an anti-gouty regimen will effect—Carlsbad waters, and cut off starch, sugar, and alcohol. **Operative.**—(1) *Multiple Subcutaneous Division, the Contracted Bands*—Introduce the knife at all points where the skin is not densely attached to the fascia, and divide the bands, and try to straighten the finger; do this in many places, till the finger can be brought straight; when straight enough, keep the hand in a straight splint for four weeks, then leave off the splint during the day, and finally leave it off altogether. (2) *BUSCH'S Operation*—Make a V-shaped incision, with its base opposite the root of the finger; dissect up the flap and straighten the finger, so that the V now becomes a Y; finish by suturing the flap to the limbs of the Y. This is exactly JONES'S operation for ectropion. (3) Dissect up flaps of skin from the palm, and cut out the contracted fascia altogether.

A curious accident occasionally happens from a blow, or by giving a forcible flick with the finger—viz., rupture of that part of the common extensor tendon attached to the last phalanx of one of the fingers. The ruptured tendon is apt to adhere to the second phalanx, leaving the terminal phalanx entirely useless.

Cutaneous Nerves of the Fingers.—In **Front** (Fig. 157), the median nerve supplies the thumb, index and middle fingers, and the radial half of the ring finger; the ulnar supplying the ulnar side of the ring, and the whole of the little finger. **Behind** (Fig. 158), the radial nerve supplies the fingers supplied by the

Fig. 157.
PALMAR CUTANEOUS NERVES.

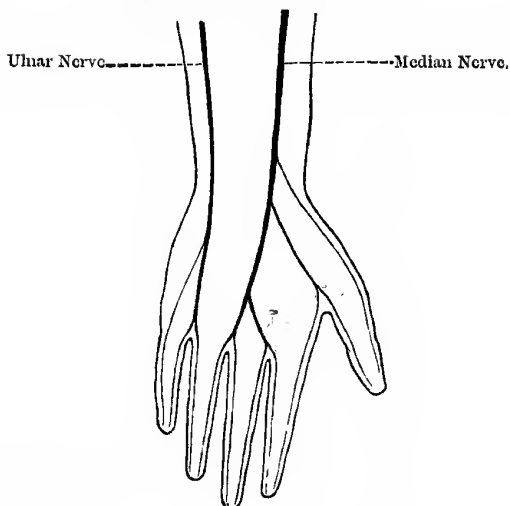
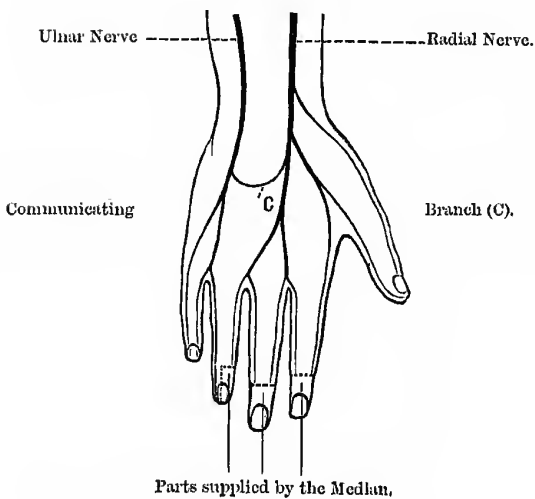


Fig. 158.
DORSAL CUTANEOUS NERVES.



median in front, *except* the unguis phalanges of the index and middle fingers, and the radial half of the unguis phalanx of the ring finger, which are supplied by the median; the ulnar supplies the remaining one and a half, just as on the anterior aspect.

The **Middle Line of the Hand** is a line drawn through the centre of the middle finger, and when we speak of abduction or adduction of the fingers or thumb it is in reference to *this line*, and not to the middle line of the body; the same remark applies to the foot. Remember also, that the palmar interossei draw the fingers to this line, or adduct; and that the dorsal draw them away from this line, or abduct. The interossei also aid the lumbricales in flexing the first phalanges and extending the other two.

The **Palmar Furrow** of the hand, formed by the flexion of the fingers at the carpo-metacarpal articulation, very nearly indicates the position (1) of the carpo-metacarpal articulations, (2) the bifurcation of the digital arteries, and (3) the upper end of the synovial sheaths of the fingers; it also indicates the point beyond which the anterior splint in COLLES'S fracture should *not* come.

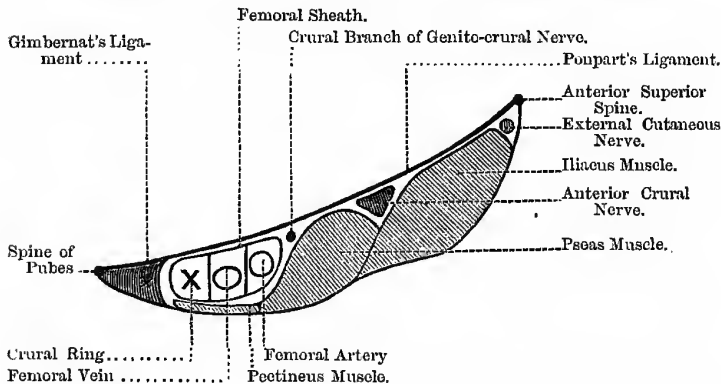
CHAPTER XXXII.

THE LOWER EXTREMITY.

Poupart's Ligament.—This is a strong fibrous band, stretching between the anterior superior iliac spine and the spine of the pubes; it is part of the insertion of the external oblique muscle of the abdomen, and separates the thigh from the belly, and the external abdominal ring from the saphenous opening, and is

Fig. 159.

STRUCTURES BETWEEN POUPART'S LIGAMENT AND THE BONE.



an important diagnostic landmark between inguinal and femoral hernia. It is often known as the *Crural Arch*. Filling up the gap between this ligament and the bone, we find the following Structures (Fig. 159):—(1) External cutaneous nerve; (2) iliacus muscle; (3) the psoas muscle; (4) the anterior crural nerve, lying in the groove between these two muscles, and separated from the

femoral sheath by a small part of the psoas—at this part of its course the nerve is not round, but may be triangular or quadrilateral in shape; (5) the crural branch of the genito-crural nerve lying on the femoral sheath; (6) the femoral sheath with its component parts, compartments, and contents—the artery most external, the vein in the middle, and the beginning of the crural canal most internal (see “Femoral Hernia”); (7) below the sheath, the origin of the pectineus; (8) GIMBERNAT’S ligament—a continuation of POUPART’S—along the pectineal line, and part therefore of the insertion of the external oblique; and (9) the accessory obturator nerve, in cases where this nerve exists, lying beneath the pectineus muscle.

Superficial Glands of the Groin.—These glands are arranged in two rows—one disposed irregularly along Poupart’s ligament, the other disposed vertically along the inner side of the thigh, or grouped irregularly around the saphenous opening. The first of these receives the lymphatic vessels from the integument of the penis, scrotum, or vulva, parietes of the lower half of the abdomen, the perineal and gluteal regions; the vertical group receives the lymphatic vessels from the lower extremity. These glands frequently become enlarged in diseases implicating the parts from which their lymphatics spring (bubo). Thus, in malignant disease, when it involves the integument, syphilitic or other venereal affections of the genital organs, abscess of the perinæum, cancer of the scrotum, etc., the glands along Poupart’s ligament will be implicated, while the vertical set will be enlarged in affections of the lower limb and foot, *e.g.*, melanotic sarcoma about the toes.

SCARPA’S TRIANGLE.

This is a triangular space situated at the upper third of the anterior surface of the thigh; from base to apex it is about a hand’s-breadth in extent—about four inches. **Boundaries.**—On the **outer side**, the inner border of the sartorius; on the **inner side**, the inner prominent half of the adductor longus; its **base** is formed by POUPART’S ligament, and its **apex** is formed by the crossing of the sartorius over the adductor longus. Its **roof** is formed by the skin, superficial and deep fascia, and the cribriform fascia.

The **Cribriform Fascia** closes up the saphenous "opening," and is pierced by a large number of lymphatic vessels (hence its cribriform appearance); it is also pierced by the long saphenous vein. This is the longest vein in the body; it passes through the cribriform fascia, at the lower end of the saphenous opening, just above the inferior cornu. Just before it passes through, it is joined, usually as a common trunk, by the veins corresponding to the three superficial branches of the femoral artery. At this point the vein is frequently the subject of the diseased condition known as **Varix**; some believe that this is due to the vein being semi-strangulated by turning too sharply over the dense fascia forming the inferior cornu of the saphenous opening, and to relieve the condition and cure the disease, suggest that the fascia should be divided. The **floor** of the triangle is formed by (beginning at the outer side) the iliacus, psoas, pectineus, sometimes part of adductor brevis, and adductor longus muscles. **Contents.**—(1) The femoral sheath; (2) the femoral artery, giving off the cutaneous branches and the profunda; (3) the femoral vein with its tributaries, the long saphena and profunda veins; (4) the anterior crural nerve and its branches; (5) the external cutaneous nerve; (6) the crural branch of genito-crural and ilio-inguinal nerves; (7) the superficial division of the obturator nerve; and (8) fat, with deep lymphatic glands and vessels.

Fluctuating Swellings in this region of the groin are numerous, as—(1) Localised chronic abscess; (2) it may come from a perinephritic abscess; (3) on the right side, from a pericæcal abscess; (4) iliac abscess under the fascia, from disease of the bones, or above it; (5) pelvic abscess, in hip disease or from cellulitis; (6) glandular abscesses; (7) from an empyema; (8) serous or hydatid cysts; (9) a hernia with fluid in the sac; and (10) cysts or bursal collections in connection with the hip joint, *e.g.*, in **CHARCOT'S** disease, and sometimes in chronic rheumatic arthritis.

Structures beneath the Gluteus Maximus Muscle.—(1) Part of gluteus medius; (2) superficial branch of the gluteal artery and superior gluteal nerve; (3) piriformis muscle; (4) lower border of gluteus minimus; (5) sciatic vessels; (6) great and small sciatic nerves; (7) pudic vessels and nerve; (8) nerve to the obturator internus, which also supplies the gemellus superior; (9) nerve to

the quadratus femoris, which also supplies the gemellus inferior; (10) the gemellus superior muscle; (11) tendon of the obturator internus; (12) gemellus inferior; (13) tendon of the obturator externus; (14) quadratus femoris; (15) termination of the internal circumflex artery; (16) part of adductor magnus; (17) the first perforating artery; (18) great trochanter, with part origin of the vastus externus; (19) the tuber ischii with the origin of the hamstrings—biceps, semi-membranosus, and semi-tendinosus; (20) great sacro-sciatic ligament, pierced by the coccygeal branch of the sciatic artery; (21) three bursæ—(a) one over the trochanter major, (b) one over the vastus externus, and (c) another over the tuberosity of the ischium. When this last one is enlarged, as by excessive pressure, it gives rise to the condition known as “weaver’s, or lighterman’s bottom,” corresponding to the “miner’s elbow,” and the “housemaid’s knee” of other situations. The bursa over the trochanter major may be enlarged in the case of soldiers on the march, convicts and others who are condemned to the use of the “plank bed;” it might be called the “coercion bursa.” The lower edge of this large muscle forms the “fold of the buttock,” but the “fold” and the lower edge of the muscle do not correspond in direction, the “fold” being nearly transverse, while the lower edge of the muscle passes upwards and inwards towards the coccyx.

The Great Sciatic Nerve.—This nerve is the continuation of the lower part of the sacral plexus, and leaves the pelvis by the great sacro-sciatic foramen, below the pyriformis muscle, and a little external to the sciatic artery. The nerve will, therefore, be found beneath a point a little external to the point that indicates the situation of the sciatic artery on the surface of the body (see vol. i., page 141). Its course is indicated by a line drawn from the point where it emerges from the pelvis to the middle of the upper part of the popliteal space. The nerve, however, is not straight, but is curved with the convexity outwards, and at its upper part is found almost midway between the great trochanter and the tuber ischii, but a little nearer the ischium. The nerve is covered by the gluteus maximus and the long head of the biceps, and slightly by the pyriformis, and it lies upon all the muscles found beneath the gluteus maximus, below the pyriformis—viz., tendon

of the obturator internus and the two gemelli, obturator externus, quadratus femoris, and adductor magnus. The nerve may bifurcate into its two divisions at any point between the sacral plexus and the usual point of bifurcation; a not uncommon arrangement is to find it leaving the pelvis in two divisions, one of which pierces the pyriformis, and the other in the usual position. This fact must be borne in mind in the operation of "stretching" this nerve. It is important to remember its course in connection with the operation of **acupuncture** for sciatica; further, it is important to bear in mind, in the operation of **stretching** this nerve, that it can be exposed without cutting through any muscular structure, at the lower border of the gluteus maximus (indicated by the fold of the nates), in the interval between that muscle and the long head of the biceps.

To Stretch the Great Sciatic.—The instruments required are—A knife to shave the parts, carbolic oil, a scalpel, dissecting forceps, retractors, sponges, needles and horse-hair sutures, collodion, pads of cotton wool and bandages, chloroform, etc. The Surgeon should, if he has a choice, stand at the *opposite side* from the nerve about to be stretched.

1. At the **Fold of the Buttock.**—The part must first be rendered thoroughly aseptic. It is then shaved, if necessary, and an incision made, about two inches in length, in the line of the nerve; this incision divides the skin, superficial fascia, fatty tissue, and deep fascia. The finger is then introduced to hook out the nerve, which is found in the angle formed by the gluteus maximus on the inner side, and the hamstrings, as they arise from the ischial tuberosity, on the outer side; the finger first touches the vastus externus, and when drawn across this muscle towards the operator, the first thing caught is the great sciatic nerve (CHIENE). The nerve is then to be stretched as much as the Surgeon deems necessary, being first pulled well out, and then up the limb and down the limb, in a number of short jerks rather than a long, steady pull. Some Surgeons lift the limb from the table by the nerve. Dr SYMINGTON advises care, lest the sacral plexus be torn away from the cord. A caution is usually given not to stretch the tendon of the semi-membranosus by mistake; but by the above plan this is not likely to happen, for it would be impossible to hook that tendon *out* at

the wound so near its origin, and especially when the patient's knee joint is extended. The wound is then to be washed out by some antiseptic, three sutures inserted, and the whole sealed up by flexible collodion and cotton wool. In cases of high division of this nerve, the finger may not recognise the nerve trunk, from its divided and flattened form; in these circumstances enlarge the wound and *look* for the nerve. Stretching the *right* sciatic is more successful than the left, it is said, because the sigmoid flexure is on the left side, and is a great cause of sciatica, as the full gut presses upon the nerve; it will be, therefore, very much worse in constipation. Occasionally the first perforating artery may be injured, a troublesome circumstance, as it bleeds much, and is difficult to secure, as it retracts beneath its fibrous arch.

2. It may also be stretched at the **Middle of the Thigh**, by an incision two or three inches long, dividing the same structures as in the last case. Here the nerve lies between the biceps on the outer side, and the semi-tendinosus on the inner side. The wound may be dressed as in the last case, or it may be drained, dressed antiseptically, and confined in a splint for a week or ten days.

3. The "**Dry**" Plan (TROMBETTA and BILLROTH).—The patient is laid on his back, the knee joint is flexed, and the ankle joint extended, and then the thigh is forcibly flexed on the abdomen until the knee joint almost touches the chin; the thigh is then held firmly in this position while the knee joint is fully extended and the ankle joint as fully flexed.

Before any operation for supposed sciatica, the Surgeon must make sure that the pain is not due to malignant disease of the bones or pelvic viscera, involving the sacral plexus, or to irritation caused by disease of the sacro-iliac synchondrosis, engorged rectum, varicose condition of the pelvic veins, aneurism of the internal iliac, or its branches, or to sciatic hernia. The spine should also be examined for caries; the diseases most apt to involve the plexus are sarcoma of the sacrum or os innominatum, and malignant disease of the rectum, and sarcoma of the soft parts in the pelvis.

The **Great Sciatic Nerve** supplies the hip joint, entering posteriorly, and the flexors of the leg, viz., the biceps, semi-tendinosus, and semi-membranosus, as well as a branch to the adductor magnus; about the lower third of the thigh it divides into the external and

internal popliteal nerves, which supply the whole of the muscles below the knee. In **paralysis** of this nerve, therefore, the patient would be unable to flex the knee, and there would also be some weakness of the adductor magnus; it is evident, however, that the trunk of this nerve could not be paralysed without also paralysing the internal and external popliteal nerves, with their branches.

The Anterior Crural Nerve.—This is the largest branch of the lumbar plexus, and arises from the third and fourth lumbar nerves, with a fasciculus from the second. While yet **inside the Abdomen** it supplies the *iliacus* muscle, and gives a twig to the femoral artery. **In the Leg**, it supplies—(1) The *sartorius*, usually from the middle or internal cutaneous branches; (2) the *pectineus*—this muscle usually receives two branches, which reach it by passing behind the femoral vessels; (3) the *rectus femoris*; (4) the two *vasti*—the nerves to the vasti also supply the knee joint; and (5) the *crureus*. When this nerve is **paralysed** the patient will be unable to flex the hip properly, as the *iliacus* is paralysed, though the *psoas* is not; he will be unable to extend the knee joint; the *sartorius* will be paralysed, and the *pectineus* partially.

The Obturator Nerve.—This nerve is a branch of the lumbar plexus, and arises from the third and fourth lumbar nerves. It supplies—(1) Two joints, the hip and knee; (2) four muscles completely, the adductors longus and brevis, the gracilis, and the obturator externus; and (3) two muscles partially, the *pectineus* and the adductor magnus. Should this nerve be **paralysed**, the patient would be unable to press the knees together or cross the paralysed leg over the other one. The left obturator lies beneath the sigmoid flexure; consequently, when this part of the gut is distended with feces, or the seat of malignant disease, the nerve may be irritated, causing a “pain in the knee,” just as in hip joint disease. Both nerves lie in front of the sacro-iliac synchondrosis, and are often early affected in disease of that articulation.

HIP JOINT DISEASE.

It is a fact worthy of notice in connection with the conduction of nervous impulses in sensory nerves, that when a stimulus is applied to any part in the course of a sensory nerve—as to the nerve trunk, or to sensory filaments supplying parts nearer the

central nervous system than the final distribution of the nerve,—that the impulses appear to be conveyed to, or to spring from, its terminal filaments (in fact, a sensory nerve *appears* to be able to conduct impulses *both* ways). Thus, if we compress the ulnar nerve at the elbow joint, we feel the painful impression conveyed to the terminal filaments of the nerve supplying the little finger and the ulnar side of the ring finger. We also find an example of the same phenomenon in connection with hip joint disease in its earlier stages; for at first the patient does not feel pain in the hip joint, but on the inner side of the knee or in the knee joint itself. So also in spinal caries, pain is felt at the hip, and this may put the incautious Surgeon off the scent; also in kidney diseases, pain is often felt in the bladder or testicle. Pain at the inner side of the knee is also felt in disease of the sigmoid flexure, from irritation of the **Obturator Nerve**, or in any other condition involving this nerve in any part of its course, as caries of the lower lumbar vertebræ, psoas abscess, sarcoma of the bones or soft parts, and obturator hernia, and, in cases where there is an accessory obturator, femoral hernia as well. This is no doubt due to the fact that the obturator nerve supplies sensory filaments to both the hip and knee joints; and also because there is frequently found on the inner side of the lower third of the thigh, a plexus of nerves known as the “obturator plexus,” which is formed by filaments from the internal cutaneous, long saphenous, and obturator nerves. The pain at this spot is most marked when the disease begins in the *head of the bone*, as the obturator nerve enters the round ligament, and is in this case, therefore, early affected. Besides the obturator nerve, the great sciatic (through its branches) also supplies both the hip and knee joints.

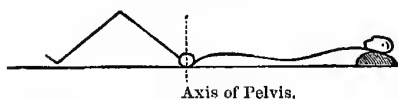
By *Morbus Coxæ* is meant strumous arthritis of the hip joint, whether it begins in the bones or the synovial membrane. When it begins in the soft parts, it is called the *arthritic* form; in the acetabulum, the *acetabular*; and in the head of the femur, the *femoral*. It has been divided for convenience into various stages.

1. The **Inflammatory Stage**, probably accompanied with some synovitis and softening of the structures round the joint, and the limb assumes that position where the cavity can hold most with the least tension. The signs of this stage are—(a) *Flexion*, as in

this position there is greatest general relaxation, and the cavity holds most. (b) *Abduction*, which relaxes the outer limb of the ilio-femoral ligament and upper part of the capsule. (c) *Eversion*, which relaxes the inner head of the same ligament, and the horizontal posterior fibres of the capsule. (d) *Apparent lengthening*, from the tilting down of the pelvis on that side; the anterior superior spine moves downwards, forwards, and inwards. This is because the flexion and the abduction raise the foot off the ground and destroys the parallelism of the two limbs; hence, when the patient walks, to enable the foot to reach the ground and also to restore that parallelism which is necessary for walking, the pelvis tilts.

Fig. 160.

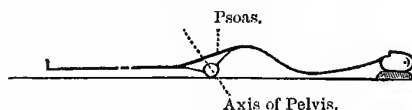
HIP JOINT DISEASE.



Position of Knee, as patient lies with his *Back* flat on the table.

Fig. 161.

HIP JOINT DISEASE.



To show the Lumbar Curve, when the *Knee* lies flat on the table.

To detect the tilting of the pelvis draw one line from the xiphoid cartilage through the umbilicus to the symphysis pubis, and another between the two anterior superior spines. In health these lines should cross each other at *right angles*. (e) *Lordosis*—this is because the hip joint is fixed by muscles in the flexed position, and to overcome this disadvantage the lumbar vertebrae move instead, and are also curved forwards. This is well seen when the patient is laid on a firm table on his back; as he lies in this position his knee is bent upwards (Fig. 160), and on attempting to bring the knee down level with the table the lumbar spine becomes hollow, because the *pelvis moves* with the femur (Fig. 161). Besides these symptoms

there are others, such as the limitation of abduction, wasting of the limb, flattening of the buttock, and obliteration of the gluteal fold; the flattening of the buttock and the obliteration of the gluteal fold are partly due to the flexed position of the limb, as well as to atrophy of the glutei. The fold in the groin will also be partially obliterated, on account of the swelling. The muscles round the joint, especially the adductors, are firmly contracted, to steady the diseased part: the muscles know that the joint is diseased even before the patient is aware of it. In the very early stage of the disease the symptoms are often ill-marked, the child scarcely complains, and probably has only a slight limp when walking.

2. **Second Stage.**—This corresponds to yielding of the capsule, probably abscess formation, but no destruction of the bone. The signs are—(a) *Adduction*—some say, because the posterior part of the capsule gives way; others, that it is because the adductors are reflexly thrown into spasm. (b) *Inversion*—this is not very easily explained; if the head of the bone were dislocated backwards through the softened posterior part of the capsule, one could understand it. It may be that the external rotators are inhibited, and the internal, supplied by the superior gluteal nerve (tensor fasciæ femoris, gluteus minimus, and anterior half of the gluteus medius), reflexly thrown into spasm. (c) *Apparent Shortening*—this is from tilting of the pelvis, so as to bring the diseased limb parallel with its fellow as the patient lies in bed. The anterior superior spine moves upwards, backwards, and outwards. The *flexion* of the first stage is increased, and, if the disease be left untreated, will go on increasing till the knee touches the umbilicus, or even the opposite anterior superior spine. This, of course, cannot be the position in which the joint “holds most,” nor can it be due to reflex contraction of the muscles.

3. **Third Stage**—In this stage the limb is pretty much in the same position as in the second stage, but there is now *real shortening*; this results from the gradual destruction of the head and neck of the femur, or dislocation of the bone backwards, and this may occur even though a light weight is applied to the limb. The top of the great trochanter ascends above NÉLATON'S line; this test is very easily applied in these cases, because the child naturally turns over towards the sound side, so that one can readily draw

a line between the two bony points. The natural cure of this condition is by ankylosis, and care must be taken lest this occur, as it is apt to do, in the flexed and abducted position. Should it occur the effects are minimised by the production of a lumbar curve (lordosis).

Hip joint disease must be **diagnosed** in the early stage from the diseases and injuries that cause abduction and eversion of the thigh (see vol. ii., page 170), and in the later stages from conditions that cause adduction and inversion, as the backward dislocation of the femur at the hip joint, which, indeed, may be but a result of the hip disease. It must also be distinguished from suppuration of the bursa under the gluteus maximus over the great trochanter; in this condition there is great pain, on pressure, over the great trochanter, as the diseased area is between the surface and the bone, but not, as a rule, when pressure is made on the knee or heel, nor by direct pressure on the head of the bone just below **POUPART'S** ligament. In actual hip disease there will be pain, on pressure, *in all the three situations*. Pus, in the *arthritic* and *femoral* forms of hip disease, usually passes behind, as the posterior part of the capsule is thinnest; it then comes forwards beneath the gluteus medius and minimus, tensor fasciæ femoris, and upper part of the sartorius, and forms a collection below the anterior superior spine. It may then pass down, if unchecked, and open behind the ilio-tibial band, a little above the middle of the thigh. In the *acetabular* form of the disease the pus collects between the bone and pelvic fascia and sheath of the obturator internus; the fascia thickens and prevents its passage downwards, hence it makes its way up to the pelvic brim, perforates the attachment of the pelvic fascia to that part, and points above or under **POUPART'S** ligament. It may sometimes pass along the tendon of the obturator internus and point behind, or even pass into the rectum. When a "psaos" abscess forms from hip disease, it is probably due to a communication between the bursa under the psaos tendon and the cavity of the hip joint. While the Surgeon must be on his guard, in cases where the knee joint is complained of, rather than the hip where the actual disease is situated, not to be misled in his diagnosis and treatment, yet he must bear in mind that *both* knee and hip *may* be diseased; the rule is, that if, in examining the

joint the patient complains of, sufficient *objective* signs of disease are not found there to account for the subjective sensations, then *look higher up*; the same remark applies to spinal caries simulating hip joint disease—our motto in both cases being “**Excelsior.**”

Sacro-iliac Synchronosis.—This is the articulation between the cartilage-coated surfaces of the sacrum and ilium. It is an amphiarthroidal joint, and there is sometimes a delicate synovial membrane. The **Ligaments** are—(1) The *anterior sacro-iliac*, which is very thin and passes between the two bones; (2) the *posterior sacro-iliac*, which is a very strong ligament, the fibres being partly oblique and partly horizontal—the oblique part is attached to the posterior superior iliac spine. The joint is supplied by the superior gluteal, from the lumbo-sacral cord, and branches from the sacral nerves. The lumbo-sacral cord and the obturator nerve pass over the front of the joint, and are early affected in disease of the articulation.

Sacro-iliac Disease.—In disease of this joint, unlike hip joint disease, the limb is not flexed (unless the psoas muscle is involved as well); it, very constantly, seems longer than its fellow, due to tilting forwards and rotation downwards of the whole side of the pelvis. There is pain when the iliac crests are grasped and attempts made to force them asunder or together, and also when the pelvis is compressed laterally. There will also probably be pain along the branches of the anterior crural, obturator, and great sciatic nerves; there is further marked pain when direct pressure is made on the joint, just internal to the posterior superior iliac spine. The joint is painful *whether the patient stands or sits*, in this respect differing from hip disease, where the patient can sit with comfort. The fact that the hip can be fully extended, and when flexed there is neither rigidity nor pain in moving the hip joint, provided the sacro-iliac be kept still, will exclude hip joint disease. Pus from this joint comes forward through the anterior sacral ligaments, and very usually presents as an iliac abscess somewhere between the femoral vessels and the the anterior superior iliac spine. It may, however, pass into the sheath of the psoas when the limb will assume a flexed position, or it may pass along the vessels and nerves passing through the great sacro-sciatic foramen and point in the buttock, or through the thyroid foramen,

and behind the "apex beat," and it is easily understood, therefore, how an over-full stomach may interfere with the motions of the heart, and also cause dyspnoea, by forcing up the diaphragm and impeding the respiratory movements. The fundus is absent in newly-born children.

Relations.—In **front**, we find the anterior abdominal wall, the diaphragm, and the under surface of the liver; **behind**, the crura of the diaphragm, the aorta, the pancreas, the splenic artery and vein, the superior mesenteric artery, the third part of the duodenum, the left kidney, the left supra-renal capsule, and the spleen, with the gastro-splenic omentum. Note the relation between the third part of the duodenum and the posterior surface of the stomach. In **Wölfler's operation**, in cases of cancer of the pylorus too bad for excision, a fistulous communication is formed between the two viscera at this point. The operation is termed **Gastro-Enterostomy**. The upper end of the jejunum may also be attached to the stomach in preference to the third part of the duodenum. **Above**, we find the lesser omentum, with its contents, and the cœliac axis; **below**, the great omentum and the transverse colon.

Peritoneal Connections.—(a) The gastro-phrenic ligament, passing from the diaphragm to the angle between the œsophagus and the cardiac end; (b) the gastro-hepatic, or lesser omentum; (c) the gastro-colic or great omentum; and (d) the gastro-splenic omentum.

The Arteries of the stomach are—(1) The gastric or coronary, from the cœliac axis; (2) the pyloric, from the hepatic; (3) the gastro-epiploica dextra, a division of the gastro-duodenalis; (4) the gastric (*vasa brevia*), from the splenic; and (5) the gastro-epiploica sinistra, from the same source. The gastro-duodenal branch of the hepatic divides into the gastro-epiploica dextra and the superior pancreatico-duodenal artery; the latter vessel, as the name implies, supplies both the duodenum and the pancreas. In ulceration of the duodenum, occurring in connection with severe **Burns**, this artery may be perforated by the ulcer, resulting in death from hæmorrhage; the perforation is most common from the tenth to the fourteenth day of the burn, and is usually situated a little way from the pylorus. A **Gastric Ulcer** may perforate one of the vessels of the stomach, and lead to sudden death from hæmorrhagè; it

may also give rise to abscess between the liver and the diaphragm, just as duodenal ulcer sometimes does. An abscess here presses down the liver and pushes up the diaphragm, and the pus may even pass through it into the base of the lung, and be expectorated through the bronchi. The ulcer may also open into the peritoneal cavity, leading to fatal peritonitis.

Gastrotomy.—An opening of a temporary character made into the stomach for the purpose of removing a foreign body.

Gastrostomy.—An opening made into the stomach for the purpose of feeding the patient, and to establish a permanent gastric fistula. Operations of this nature may be rendered necessary in consequence of impermeable stricture of the œsophagus, to prevent the patient dying of starvation. There are four varieties of Stricture described—(1) The nervous or spasmodic—this form is usually intermittent, and if the patient can be induced to forget about it for the time being, the food passes quite easily. (2) Fibrous stricture, the result of swallowing corrosive fluids and boiling water—this form may be dilated by passing bougies. (3) Cancerous—this is the most common form, and is apt to follow the fibrous variety. The bougie seems to pass over a *roughened* surface, and its introduction is followed by the coughing up of blood, or blood and pus; the cervical glands will also probably be enlarged, and other signs of the “cancerous cachexia” present. By these means it may be diagnosed from fibrous stricture, and this will also be assisted by the history of the case. (4) There is also a peculiar form of stricture, met with in drunkards, probably from general cirrhosis of the mucous and submucous coats. Malignant disease is usually of the nature of squamous-celled epithelioma (the so-called “scirrhus”), and is most frequently found opposite the cricoid cartilage (at the beginning of the œsophagus), next at the cardiac orifice, and, lastly, opposite the bifurcation of the trachea. As long as possible the patient may be fed with slops, or through a catheter, or by the use of artificially-digested foods per rectum; and, if these are not sufficient, the stomach may be opened. Another possible condition must always present itself to the student’s mind, in connection with the diagnosis of stricture of the œsophagus—viz., aneurism of the aorta. *This condition must always be excluded before attempting to pass a bougie.* On account of the close relation

that exists between the aorta and the œsophagus, malignant disease of the œsophagus is very apt to ulcerate into the aorta, and suddenly produce fatal hæmorrhage.

The patient is laid on his back, and, according to SÉDILLOT, a **crucial incision**—each limb of which is about one inch and a half in length—should be made on the left side, two finger's-breadth to the inner side of the costal cartilages, and one-third nearer the ensiform cartilage than the umbilicus. This form of incision is rarely used at the present time. The space, in some part of which the opening should be made, is bounded on the left side by the eighth, ninth, and tenth costal cartilages—above and internally by the liver, and below by a line drawn at the level of the tenth costal cartilages. This space is known as the "**triangle of Tillaux.**"

An **oblique incision**, made parallel with, and one or two finger's-breadth from, the costal margin—beginning at the sternal extremity of the seventh intercostal space, and carrying it downwards and outwards from two to four inches,—is a form frequently used (Fig. 176, 1). LABBÉ contents himself with an incision in this position about an inch and a quarter, or an inch and a half in length. HOWSE prefers a **vertical incision**, nearly at the same level, passing through the outer fibres of the rectus muscle, which will, it is hoped, afterwards act as a sphincter to the opening. The opening may also be made through the left *linea semilunaris*, or beyond this, passing through the three flat muscles of the abdomen.

The instruments required are—Scalpel, dissecting forceps, probe-pointed bistoury, directors, plenty of WELLS'S forceps, broad copper retractors, blunt hooks, needles and silk, sponges, scissors, chloroform, a silver tube, etc. By some one of the foregoing incisions the abdominal wall is cut through, and when all the bleeding vessels are secured, the peritoneal cavity is opened and the stomach grasped and drawn out into the opening by ring-forceps, or a stitch. Care must be taken not to mistake the transverse colon for the stomach; but the colon is distinguished by (*a*) its sacculi, (*b*) its longitudinal bands of muscular fibres, and (*c*) by the appendices epiploicæ, and (*d*) its thinner walls. If the colon presents it must be pushed downwards

till the stomach comes into view. Having found the proper viscus, the second step is to secure it to the edges of the opening. This is best done by carbolised silk sutures passed through the serous and muscular coats only; the loosely attached mucous coat can readily be shaken away by grasping the other coats between the finger and thumb. The sutures are passed through the wall of the stomach, then through the divided peritoneum, and, lastly, through the skin and fat; the muscular tissue of the abdominal wall is not included. Some prefer to use a double circle of closely set silk sutures, the outer row passing through the whole thickness of the abdominal wall, in order to secure a wide peritoneal attachment, and then tie the sutures over pieces of india-rubber tubing, or a lead button; the inner circle simply passes through the serous coat of the stomach and the cut edge of the skin wound. All the sutures are passed before any are tied; they are about one-sixth of an inch apart, and should enclose a circular area of the stomach wall about the size of a shilling. Thus secured, the wound is dressed antiseptically in the usual manner, and the patient fed per rectum for a period of from three to five days; by this time the stomach will have adhered to the wound. The third step of the operation is to make a *small* opening in the stomach, which is done by passing a narrow sharp-pointed bistoury through the middle of the adherent area; the opening should only be large enough to admit a No. 10 catheter. Into this opening an india-rubber, or silver, tracheotomy tube can be fitted. The sutures should not be removed for ten days. The great risk of this operation is peritonitis; but by the proper use of antiseptics and the adoption of the method of doing the operation in *two* stages—introduced, we believe, by Mr HOWSE—the risk is reduced to a minimum. Instead of using sutures, in connecting the wall of the stomach with the abdominal wall, Mr HOWSE uses a pair of loose torsion forceps, the blades being shielded with rubber, to grasp the outer coats of the stomach, and then lays the forceps on the surface of the abdomen, beneath antiseptic dressing. In this way the stomach is retained in position till adhesions have formed.

The Structures divided will necessarily vary with the incision used. In this situation, speaking generally, the abdominal wall is composed of the following structures:—(1) Skin and fascia;

(2) the external oblique, (3) the internal oblique, and (4) transversalis muscles; (5) the fascia transversalis; (6) extra-peritoneal fat; (7) the peritoneum; then comes (8) the stomach wall itself. More internally, we simply find the rectus in its sheath, fascia transversalis, extra-peritoneal fat, and peritoneum.

Difficulty in swallowing (*dysphagia*) may arise from other causes than stricture, viz.—(1) Tumours in the pharynx, such as polypi or abscess; (2) œdema about the back of the epiglottis; (3) tumours in the neck outside the œsophagus; (4) aneurism of the innominate artery; (5) aneurism of the aorta; (6) dislocation of the sternal end of the clavicle backwards; (7) impaction of a foreign body in the gullet; (8) intra-thoracic tumours, such as enlarged bronchial glands, cancerous masses, etc. These tumours must be carefully distinguished from aneurisms. In aneurism there is dullness on percussion, dyspnoea, dysphagia, a fixed gnawing pain between the shoulders, shooting pains down the arms or side of head, and distension of the superficial veins of the chest.

This operation may also be performed for stricture at the *cardiac* end of the stomach.

RÉSUMÉ of GASTROSTOMY:—

1. Make an incision, parallel with the costal margin, as already explained, or use the vertical one if preferred.
2. Cut through the various structures forming the abdominal wall till the peritoneum is exposed.
3. Then tie all bleeding points very carefully, and sponge the wound dry.
4. Open the peritoneum, introduce a carefully-cleaned finger, and hook forward the stomach; make sure that it is the stomach by feeling for the pyloric and cardiac ends. The transverse colon may present first, but its walls are much thinner; it must be pushed downwards.
5. Introduce a loop of silk into the stomach wall, by which to keep it in the wound during stitching operations; this loop should go down to, but not through, the mucous membrane, and should be left to act as a guide to the subsequent operation of opening the stomach, after it has adhered to the anterior abdominal wall.

6. Insert the outer row of *longitudinal* sutures by handled needles, enclosing a four-sided or six-sided area of the stomach wall, and approximating it to the abdominal wall; these are introduced at some distance—say an inch—from the edge of the wound and go through the whole thickness of the abdominal wall, but, if possible, not through the mucous coat of the stomach. If necessary, these are tied over lead buttons or india-rubber tubes; all the sutures of this row must be inserted before any are tied. These sutures may first be passed through the abdominal wall, then into the stomach wall, and again passed through the abdominal wall; or sutures may be taken, eighteen inches long, with a needle at each end—the suture then being first passed through the stomach wall, and afterwards each end through the abdominal wall, from within outwards.
7. Insert the inner row of radiating sutures attaching the peritoneal surface of the stomach and the divided edge of the parietal peritoneum to the cut edge of the skin wound; these are fastened as they are inserted, and enclose an area of the stomach wall about the size of a shilling.
8. Dust the wound with powdered boracic acid, and dress.
9. Open the stomach by a very *small* incision in the course of a few hours, or leave it for four or five days, according to the state of the patient, and remove the silk loop (if it has not been already done), inserted in the first instance to hold the viscus *forward*. If left till now, it will form a good guide by which to open into the stomach.

PYLORUS.

1. **Simple or Fibrous Stricture.**—This is usually a result of the chronic gastric ulcer. The ulcer is, as a rule, situated in or near the pylorus or posterior wall, close to the lesser curvature. When the ulcer heals, the cicatricial contraction may cause stricture in two ways—(1) By directly implicating the pylorus, or (2) from

the results of traction as the ulcer heals. In ulcer, the pain is localised, worse on pressure and on taking food, and persists till the stomach is emptied by vomiting.

Operative Treatment (LORETA'S operation).—An incision, three or four inches in length, is made in the median line, between the ensiform cartilage and the umbilicus, as the stomach is usually displaced downwards and to the right. After all the bleeding is stopped, the peritoneum is opened, and the stomach exposed. After this it is to be gently held forwards into the wound by means of forceps, the blades of which are protected by india-rubber. An opening is next to be made into the stomach, midway between the two curvatures, and about two inches or so from the pylorus—if the pylorus is the opening to be dilated. Should the cardiac orifice require to be dilated, the incision must be made nearer that end. Care must be taken not to allow blood, etc., to pass into the peritoneal cavity, by introducing sponges between the stomach and the abdominal wall. In order to avoid bleeding, the incision in the stomach wall should be vertical, as the vessels pass round the stomach transversely, not too near the pylorus, and large enough only to admit the index finger, with which it is at once plugged (TREVES). A couple of fingers are next to be slowly introduced into the stomach and then through the pylorus, first the one and then the other. The opening in the stomach must then be closed by stitching, first the mucous and muscular coats, and after that the peritoneal coat, by means of LEMBERT'S suture. The patient must be fed for a week or ten days by means of nutrient enemata, and kept under the influence of morphine; he may be allowed to suck ice to relieve thirst. After this he may take milk and soda water by the mouth. LORETA has successfully dilated both orifices of the stomach at one sitting. In bad cases the operations recommended for malignant stricture might also be tried (see next page).

2. Malignant Stricture.—This form is also most frequent at the pyloric end of the stomach, or at the pylorus itself. The form of cancer met with most frequently is "scirrhous;" but other forms are found, as columnar-celled epithelioma (*cylindroma*), and colloid cancer. It is to be diagnosed by the presence of a *tumour*, the gradual emaciation, pain, and vomiting, and by the signs of a *dilated stomach*—viz., distended abdomen, percussion showing

the enlarged stomach, with succussion splashing, and the peculiar vomit—the contents being expelled in *large* quantity every *two or three days*, with a barmy or frothy appearance, and yellowish matter floating on the top (= *sarcinæ ventriculi*). The cancerous mass is very apt to form adhesions to neighbouring organs—as the colon, liver, vena portæ, and vena cava. The **operative procedures** adopted for this condition are three in number—(1) Pylorotomy (excision of the pylorus), (2) Gastro-Enterostomy, and (3) Jejunostomy, or Duodenostomy.

(1) **Pylorotomy** (BILLROTH'S operation).—**Preliminary**—All the usual precautions adopted when about to open into the peritoneum elsewhere. The patient must be carefully fed for some time before the operation, and the stomach washed out daily with some weak tepid antiseptic, such as Condy's fluid, to get rid of the *torulæ* and *sarcinæ ventriculi*; it should be also well washed out about two hours before the operation. The patient is then chloroformed and some one of the following incisions adopted, according to the taste of the operator—(a) Parallel with the right costal margin, and two finger's-breadth from it; (b) a vertical incision, a little to the right of the *linea alba*; but the usual one is (c) transverse in direction, across the middle line, four or five inches in length, over the tumour or a little above the umbilicus. The structures composing the abdominal wall are then divided as far as the peritoneum, and all bleeding points carefully secured; after this, open the peritoneum and expose the tumour, and define its extent and adhesions. Divide the adhesions between double ligatures, or two pairs of WELLS'S forceps; make sure of its relations to the portal vein and inferior vena cava. After this, separate the great omentum from the greater curvature of the stomach, securing the *right gastro-epiploic vessels*, and at the same time remove all enlarged glands. In the same way, tear through the attachment of the lesser omentum to the pylorus and duodenum, securing the *pyloric artery* and removing enlarged glands; the hepatic artery, the portal vein, the gastro-duodenal, and the superior pancreatico-duodenal arteries, must be carefully pushed aside, as well as the bile duct. The anterior and posterior walls of the stomach, beyond the disease, are then divided with scissors for two-thirds of their vertical extent, leaving the lower third in the

meantime with the pylorus still attached; this cut surface is then closed by LEMBERG'S suture, with carbolised silk, so that the *peritoneal* surfaces of the two walls are brought into contact. This is necessary, because the stomach opening is much too large to fit the duodenum, or the duodenum might be cut *obliquely*, so as to obtain a larger border to meet the cut surface of the stomach. The remaining third of the circumference of the stomach is then divided, the duodenum cut through beyond the cancerous tumour, and LEMBERG'S sutures introduced, so as to bring the duodenum and stomach into apposition—first at the posterior and then at the anterior surfaces. On the posterior aspect, the edges of the mucous membrane, which are apt to fall away or retract, may be attached to each other by special sutures. The parts are then replaced, the peritoneal cavity carefully cleaned out, making sure that all bleeding points are secured, and the opening in the abdominal wall closed. For the first few days the patient must be fed per rectum, gradually leading up to fluid and then solid food by the mouth.

(2) **Gastro-Enterostomy.**—This operation may be performed in cases of cancer of the pylorus too bad for excision, or the cancerous mass may be excised, the ends of the stomach and the duodenum completely stitched up, and then a food passage made by means of gastro-enterostomy. It consists, as I have already said, in the establishment of a communication between the third part of the duodenum, or the upper part of the jejunum, and the stomach.

(3) **Jejunostomy.**—An operation performed in cases of pyloric cancer, where the adhesions are too extensive to admit of removal, in order to prevent the patient dying of starvation. The incision is the same as in pylorotomy. The jejunum is then attached to the edges of the abdominal incision by a double row of sutures, and the rest of the incision closed; in three or four days an opening is made into the bowel, through which the patient is fed. The operation, therefore, closely resembles the operation of gastrostomy.

A similar operation may also be performed on the duodenum, and is called **Duodenostomy**. The objection is that the duodenum is too deeply placed and too firmly fixed to the posterior abdominal

wall to readily admit of its being brought forwards and stitched to the anterior wall, without undue strain on the various structures.

An **Abscess beneath the Diaphragm** may simulate pneumothorax, especially on the right side. Such abscesses often become partly filled with air, and so may raise the diaphragm and compress the lung, the pleura remaining normal; the liver may also be pushed down. The abscess may result from perforation of the stomach, or perforation of the appendix or other parts of the intestine. The diagnosis between such a subphrenic abscess and a pyo-pneumothorax is difficult: in the subphrenic form, there will be (1) probably some previous signs of abdominal disease; (2) an absence of cough and expectoration, at least during the early days of the condition; (3) the heart is not displaced, nor do the intercostal spaces bulge; (4) the respiratory murmur below the clavicle is normal over the retracted lung, and there is an abrupt transition to an amphoric hum lower down; (5) the displaced liver, its usual position being occupied by a tympanitic percussion note; and (6) metallic tinkling on combined auscultation and percussion, and also on succussion, together with the absence of vocal fremitus.

THE PANCREAS.

The Pancreas.—This is an elongated gland that passes in a slightly oblique manner across the posterior wall of the abdomen at the level of the first lumbar vertebra, or about three inches above the umbilicus. It consists of a head, body, and tail,—the head is chiefly in the right lumbar region, the body in the epigastric, and the tail in the left hypochondrium. Its **length** varies from six to eight inches, and its **weight** from two to three and a half ounces.

Relations.—The **head** is grasped by the horse-shoe-like curve formed by the duodenum; the **tail** is in contact with the lower part of the concave surface of the spleen. In **front**, we find the stomach, the lesser bag of the peritoneum, and the ascending layer of the transverse meso-colon. The **posterior surface** lies upon, from right to left, the bile duct, the inferior vena cava, the vena portæ, right crus of the diaphragm, the aorta, the root of the superior mesenteric artery, left crus of the diaphragm, left kidney, and left

supra-renal capsule; the feeders of the portal vein are also behind it—the splenic vein running along behind the gland, while the inferior and superior mesenterics pass under its lower border to join the splenic. The **upper border** is in relation with the coeliac axis and the splenic artery. At its **lower border** we find the transverse part of the duodenum. The duct of the pancreas is called the *canal of WIRSUNG*; close to the duodenum it comes in contact with the common bile duct, when both bend downwards, and together pierce the lower and back part of the second portion of the duodenum, and open into the gut by a common orifice. They pierce the gut wall very obliquely, and this renders a valve in the interior of the gut unnecessary; in this respect it resembles the openings of the ureters into the bladder. For this reason the secretions can readily pass in, but all regurgitation from the gut is rendered impossible; this contrivance is evidently more effectual and surer than any valve could be, for a valve might become incompetent, but this never does.

Diseases of the Pancreas.—Cancer usually affects the duodenal end or head, and as it increases presses upon the neighbouring structures, but does not, as a rule, give rise to secondary deposits in other organs. The common bile duct is apt to be speedily involved, giving rise to very deep and persistent jaundice, and these facts help to distinguish it from other forms of jaundice. Thus, in cirrhosis of the liver, the jaundice is not usually deep: in gall stones it is usually intermittent: while in catarrh of the ducts it is transitory. Further, the liver is not greatly enlarged, as in cases of cancer; nor is it atrophied, as in cases of cirrhosis. In cancer of the pancreas the liver, in the early stage, is slightly swollen and tender, but later it begins to shrink, and may even be smaller than natural. The gall bladder is always dilated, and this, together with the continued jaundice, show that both the cystic and the hepatic ducts are free, and that it is the common duct that is at fault. When this is the case, the obstruction is most likely due either to cancer of pancreas or impacted gall stones. As the growth proceeds there is pain or “back-ache,” probably a tumour can be felt in the epigastrium, and there is marked and rapid anæmia and emaciation, on account of the great importance of the pancreatic digestion, which can no longer be

carried on. For this reason, too, we frequently find undigested fat in the stools, often visible to the naked eye, or ether may be used to dissolve it out, and when the ether evaporates we can produce a translucent greasy stain on blotting paper. Fatty vomit has also been observed, and very frequently sugar appears in the urine; this latter symptom is very frequent in other pancreatic diseases, *e.g.*, pancreatic calculus. Cancer usually runs its course within six months from the first appearance of the symptoms. Cancer of the pancreas may simulate cancer of the pylorus, as it presses upon that end of the stomach, and gives rise to dilatation of that organ; but in cancer of the intestine the liver is very apt to be the seat of secondary deposits, which cause considerable enlargement and bumpiness on its surface; probably also the glands at the transverse fissure would be enlarged and compress the common hepatic duct, so that the gall bladder would not be enlarged. In cancer of the pancreas the liver is not usually affected, is never bossy on the surface, and before death is often smaller than natural. The cancer may also involve, by direct continuity, the walls of the colon, duodenum, or stomach. One would also expect portal congestion, or even thrombosis, with gradual or sudden onset of ascites, enlargement of the spleen, and blood in the stools, from damming back of the blood in the feeders of the portal vein. The vena cava may also be pressed upon, giving rise to dropsy of the feet and ankles.

The most characteristic signs of the disease are—(1) The deep, persistent jaundice, accompanied with distension of the gall bladder, *without symptoms of gall stones*; (2) the absence of any enlargement of the liver; (3) the presence of sugar in the urine; (4) the marked and rapid anæmia and emaciation, and the rapid course of the disease, death usually occurring within five or six months from the onset of the “back-ache;” and (5) the presence of a tumour, together with the age of the patient.

Cysts of the Pancreas are occasionally found; the swelling is situated in the epigastric region, displaces the stomach upwards, the transverse colon downwards, and presents just above, and to the right side of, the umbilicus. It is covered in front by the great omentum. Some curious symptoms are observed in cases of cysts of the pancreas, probably from pressure on the solar plexus—

(1) There is usually a pin-hole pupil; (2) there may be patches of brownish pigment on the forehead and face; and (3) the patient is always asleep. The Treatment is to cut down and expose the cyst wall, and stitch it to the abdominal wound; after this it is opened and drained. The fluid usually only consists of water, but sometimes it contains the elements of the pancreatic secretion, when it is apt to digest the skin and cause intractable eczema. The fistula usually closes spontaneously.

Some observers have thought that atrophy of the pancreas is the cause of some forms of **Diabetes**. LANCEREAUX describes it as the "lean form;" its progress is very rapid.

The pancreas must be very carefully avoided in excision of the pylorus, so as to avoid the necessity for ligature of any part of that gland, and, further, to lessen the risk of the cicatrix of the stomach being dissolved by the escape of pancreatic juice.

THE INTESTINES.

The Small Intestine begins, in the epigastric region, at the pylorus, and ends in the right iliac fossa by joining the large intestine. It is about twenty feet in length, and as we pass from the pylorus downwards, not only does its calibre diminish slightly, but also the thickness of its walls. It is divided into three parts—(1) The duodenum, which equals in length the breadth of twelve fingers, and extends from the pylorus to the left side of the body of the second lumbar vertebra, or at the point where the small gut is crossed by the superior mesenteric artery. Of the remainder, the upper two-fifths is called (2) the jejunum, and the lower three-fifths (3) the ileum. The coils of the jejunum and the ileum are connected to the posterior abdominal wall by *the mesentery*, which extends in an oblique line from the left side of the body of the second lumbar vertebra into the right iliac fossa. It is a double fold of peritoneum, and between its two layers we find the superior mesenteric vessels, the corresponding plexus of nerves from the sympathetic, and a large number of lymphatic glands, and lacteals from the gut. The coils lie in the umbilical, hypogastric, and slightly in the right and left iliac regions, and a few coils of the ileum may pass downwards into the pelvis, into the recto-vesical pouch in the male, and the pouch of DOUGLAS in the female.

The Duodenum.—This part is wider, more fixed, and its walls are thicker than any other part of the small intestine. It is found in the epigastric, the right hypochondriac, the right lumbar, and the umbilical regions. Except its first part, the whole of the tube is deeply placed.

1. Its **ascending part** begins at the pylorus, in the epigastric region, then passes to the right, ending in the right hypochondrium, at the neck of the gall bladder. It is completely enveloped by peritoneum, like the pyloric end of the stomach, and is freely movable, in order not to interfere with the movements of the stomach. **Relations.**—*Above* and in *front*, the liver and gall bladder; *behind*, the portal vein, the gastro-duodenal artery, and the common bile duct.

2. The **descending part** descends vertically into the right lumbar region, as far as the level of the *third lumbar vertebra*: this part is fixed by cellular tissue, the peritoneum only touching its anterior surface slightly. This fixation is all the more necessary since the common bile duct and the pancreatic duct pierce its posterior surface, a little below its middle. **Relations.**—In *front*, the hepatic flexure of the colon, and the ascending colon. *Behind*, the right kidney, only a little areolar tissue intervening. To the *left*, the head of the pancreas.

3. The **transverse part** extends from the termination of the descending part, passes across the spine, through the umbilical region, to the left side of the second lumbar vertebra; this part is firmly fixed by the *musculus suspensorius duodeni*—a band of non-striated muscular fibres, mixed with fibrous tissue, taking its origin from the left crus of the diaphragm and tissue about the coeliac axis. This portion is partly covered by the peritoneum—the transverse meso-colon. **Relations.**—*Behind*, the vena cava, the left renal vein, the aorta, and the two crura of the diaphragm. It is *crossed* near its termination by the superior mesenteric vessels, and *above* is the lower border of the pancreas.

4. A **second ascending part** is sometimes described; this part is about one inch long, with the front and sides covered by the peritoneum. It extends to a point where the small intestine receives a *complete* investment of peritoneum and a distinct mesentery. At the point where the duodenum and jejunum meet

is a small fold or pouch, triangular in shape, with its broad, crescentic edge upwards, the peritoneum at this point being free from fat and blood-vessels; it is said to exist in about fifty per cent. of the bodies examined, and is the seat occasionally of *retro-peritoneal* or *mesenteric hernia*. It is known as the *fossa duodeno-jejunalis*.

Another possible point, where an **Internal Hernia** may occur, is through the mesenteric hole—a perforation sometimes found at the lower end of the mesentery, between the ilio-colic and the last branch of the *rami intestini tenuis*. At this point there is an area free from fat, glands, and blood-vessels, which is very thin, and sometimes perforated. When such hernia become strangulated, the symptoms are those of acute intestinal obstruction.

Mesenteric Hernia (Sir ASTLEY COOPER) is a condition where, from the presence of a hole in one of the layers of the mesentery, the small gut passes between or behind the layers of that structure.

In the “**Meso-Colic Hernia**” of the same authority, the gut passes between or behind the layers of the transverse meso-colon. An internal hernia may also occur into the foramen of WINSLOW. Thus there are five forms of **Internal Hernia**—(1) Into the fossa duodeno-jejunalis, (2) entirely through the mesentery, (3) between the two layers of the mesentery, (4) between the two layers of the meso-colon, and (5) through the foramen of WINSLOW.

There are yet a few other important **Clinical facts** about the **Duodenum** that ought to be kept in mind—(1) The first, already mentioned, is the relation of its termination to the posterior surface of the stomach for the operation of **Gastro-Enterostomy**. (2) The close relation of its descending part to the right kidney: so close is this relation, that duodenal or pancreatic disease may closely simulate disease of the right kidney, and *vice versâ*. (3) As it lies between the ascending colon and the right kidney, and may extend lower down than the kidney, it may be opened by mistake in the operation of right lumbar colotomy. (4) In cases of injury, the small gut is more often ruptured than the stomach: the parts usually torn are the third part of the duodenum and the jejunum. The duodenum is torn because it is fixed, and, therefore, cannot slip away; and the jejunum, because it is fixed to the duodenum.

This part of the duodenum is about one inch above the umbilicus, and, from its relation to the peritoneum, it may be ruptured either *into* or *behind* that membrane. In cases of rupture behind the peritoneum, there may be emphysema of the abdominal wall. (5) Ulceration of BRUNNER'S glands, in cases of burns. The ulcer may perforate a vessel and cause death from internal hæmorrhage; the special signs of perforation are sudden collapse, with abdominal pain, pallor, and tossing of the extremities. It may also go directly into the peritoneum and set up speedily fatal acute peritonitis; or it may give rise to abscess between the liver and the diaphragm. This ulcer is found in twelve per cent. of fatal cases of burns. (6) Catarrhal inflammation of the duodenum readily spreads back along the bile duct, and causes catarrhal jaundice. (7) The duodenum may be pressed on and obstructed in cancer of the liver, cancer of the head of the pancreas, or malignant disease of the lymphatic glands in the neighbourhood. Primary cancer is very rare; when it does occur it is usually colloid. (8) When the **Small Intestine** is distended it assumes a peculiar spiral or cork-screw-like arrangement, closely resembling the "worm" of a still. In obstruction, towards its lower end, the swelling is most marked in the umbilical and the hypogastric regions, and less so in the epigastric, the flanks and iliac fossæ remaining flat; the abdomen is equally resonant all over, and in those rare cases where the intestinal coils can be seen moving through the abdominal wall, from the anatomical arrangement of the gut, they appear moving more or less in *transverse* lines. In typical cases, the abdomen presents the appearance of a six-months' pregnancy, but a very much distended sigmoid flexure may produce the same appearance.

The Large Intestine.—The **Cæcum** is the blind commencement of the large intestine, and lies in the right iliac fossa; it is usually covered anteriorly and at the sides by peritoneum. In the fœtus it has a well-marked mesentery, and this condition is occasionally found in the adult. The ileum joins it on its inner aspect, about two and a half inches above its blind end, and at this point the ascending colon begins. The **Ascending Colon** passes straight upwards through the right lumbar region. It is covered anteriorly and laterally with peritoneum, and its bare part rests on the fascia

covering the quadratus lumborum muscle, the right kidney, and the second part of the duodenum. The **Transverse Colon** begins in the right hypochondrium, passes downwards into the upper part of the umbilical region, and then ascends into the left hypochondrium; the central part is almost transverse, and crosses the abdomen, so that its lower edge (the convexity of the arch) is a little above the level of the umbilicus (see Fig. 175). Sometimes it is found as low as the umbilicus, or even lower. It is completely covered by peritoneum, and has a wide meso-colon. On the right side it is continuous with the *hepatic*, and on the left with the *splenic flexure*. The splenic flexure is a little higher than the hepatic, and is fixed to the diaphragm opposite the tenth and eleventh ribs by a fold of peritoneum—the *phrenico-colic* or *costo-colic ligament*. The **Descending Colon** lies in the left lumbar region and is attached by loose areolar tissue to the outer border of the left kidney, and then to the fascia covering the quadratus lumborum—at first lying to the outer edge of that muscle, but as it passes downwards it inclines inwards, and lies more to the front of the muscle. It is only covered at the front and at the sides by peritoneum. The **Sigmoid Flexure** lies in the left iliac fossa, and is continuous above with the descending colon, and at the left sacro-iliac articulation becomes continuous with the rectum.

Special Clinical Points.—(1) The **Vermiform Appendix**.—This structure is about four inches in length, situated at the inner, lower, and back part of the cæcum, and usually points towards the spleen; its diameter is rather greater than that of a goose quill. It is said that foreign bodies such as cherry-stones, fish-bones, etc., are apt to lodge here and set up inflammation; it may also inflame from constitutional causes, as struma. The inflammation thus caused may go on to *suppuration*, causing perityphlitic abscess; it may also set up septic peritonitis, or the appendix may become adherent to the neighbouring peritoneum, forming a band or arch beneath which a loop of gut may be strangulated, or over which it may kink. (2) The **Ileo-Cæcal Valve** normally prevents regurgitation of the contents of the large gut into the small, but allows the contents of the small to pass into the large. In typhoid fever there is gurgling on pressure in the right iliac fossa, probably from incompetence of this valve. I merely mention this fact in order

to caution the student *not* to attempt to get this gurgling by pressure, lest, by so doing, the pressure cause an ulcerated patch to burst into the peritoneum. (3) At the point where the colon (right or left) is opened in colotomy, the quadratus lumborum is just behind it, so that this muscle must be divided or pushed to the inner side, in order to reach the gut. Further, the outer edge of the erector spinæ usually corresponds with the part of the colon uncovered by peritoneum. On this bare part is the posterior longitudinal band, which is more easily seen if the gut is looked at obliquely, so as to let the light glint off it. (4) The **Sigmoid Flexure** forms a loop like a capital C, the narrow open part of the C corresponding to the root of the mesentery; and when this is narrow the gut is very apt, when loaded with fæces in chronic constipation, to twist, the upper part of the loop toppling down over the lower half, giving rise to the condition of **Volvulus**—a condition which, when once produced, will never right itself without an operation. (5) Cases of **Intussusception** occur most frequently in the ileo-cæcal region, at the point where the ileum joins the large gut, probably due to the difference in calibre of the two tubes, aided by the fixity of the cæcum and the mobile lower end of the ileum, and probably also by the sphincter-like action of the ileo-cæcal valve. Remember it is usually the ileum and cæcum that pass into the colon, preceded by the ileo-cæcal valve, which in the usual variety always forms the apex of the intussusception, even though it should protrude at the anus. (6) **Malignant Disease** of the large intestine (*columnar-celled epithelioma* or *cylindroma*) is usually found in the rectum, or at the point where it joins the sigmoid flexure, and then after that at the various *flexures*. (7) **Foreign Bodies**, as pins, fish-bones, etc., if they pass the stomach, may stick at the ileo-cæcal valve, or appendix, but most frequently are caught in the rectum, and may there give rise to ischio-rectal abscess. (8) Large masses of foreign materials in the rectum naturally lead to attempts at expulsion, but if the mass be fixed, as in cases of cancer, an intussusception, the attempts, of course, fail, though they are frequently repeated, causing the very painful condition known as *tenesmus*. (9) In cases of obstruction of the large gut anywhere, the cæcum seems to be always more severely distended than any other part of the gut. (10) In cases of

chronic constipation the cæcum is very apt to ulcerate and be perforated, causing fatal peritonitis. (11) An abscess of the liver may open into the hepatic flexure or transverse colon. (12) In cases of gall stone, the gall bladder may become adherent to the transverse colon, and the gall stones ulcerate through into the gut and be discharged per anum. (13) In cases of obstruction, say about the sigmoid flexure, the distension is most marked in the lateral regions of the abdomen, especially in the region of the cæcum (*right iliac fossa*). The same appearances are produced in cases where the gut is loaded in bad cases of chronic constipation, so that it may be possible to trace the gut, both by sight and palpation, right round to the cæcum. In cases of obstruction, however, as from cancer, fibrous stricture, etc., the walls of the gut become hypertrophied, there is a good deal of rumbling, and the peristaltic action may be visible through the abdominal wall. But in cases where the gut is loaded with fæces, from chronic constipation, its walls are in a state of atony, there is no rumbling, nor can peristalsis be observed through the abdominal wall. When the condition lasts any length of time the small gut will show signs of obstruction, too, so that the whole abdomen, both in the lateral and anterior regions, will become tensely distended.

Perityphilitic Abscess may arise—(1) Outside the peritoneum, and (2) inside the peritoneum.

1. **The Extra-Peritoneal** form arises from disease of the cæcum or root of appendix, as catarrhal inflammation, ulcerations of various kinds, as from tubercle, dysentery, chronic constipation, or malignant disease. The pus in this form lies in the cellular tissue between the gut and the iliac fascia; it tends to pass upwards to the kidney, inwards to the pelvis, and downwards to **POUPART'S** ligament, but cannot reach the thigh because of the union between the fascia and the ligament. It points usually towards the outer end of **POUPART'S** ligament, near the anterior superior spine; it may also open into the cæcum. Abscesses *beneath* the iliac fascia, as from disease of the bone, readily pass into the thigh.

2. **The Intra-Peritoneal** form usually arises from ulceration and perforation of the appendix, from foreign bodies, tubercular disease, etc. It differs from the last as it usually occurs in young adult males, while the extra-peritoneal form is more likely to occur

in middle-aged females. As the appendix is usually blocked beforehand, extravasation of fæces is rare, so that the inflammation may remain localised, though it occasionally gives rise to slowly spreading diffuse peritonitis.

Removal of the Appendix.—In opening the abdomen for the relief of a perityphlitic abscess, it is better, at the same time, to remove the appendix as well. The general details of the operation are the same as in any other case of abdominal section. The **incision**—Various forms may be used, but the great point is to secure free access. (1) An incision just above, and parallel with, **POUPART'S** ligament has been used: this form is too low down to reach the appendix easily. (2) One nearer the iliac crest, resembling **ABERNETHY'S** modified incision for ligature of the external iliac artery. This form may be used, either when we wish to open the peritoneal cavity, or where we wish to reach an abscess and the appendix outside the peritoneal cavity, more especially the latter. The objection to this form is that one cannot wash out the peritoneal cavity properly. (3) An incision may be made in the middle line, between the umbilicus and the symphysis pubis; but this form is too far away, and it is impossible to manipulate the parts easily. (4) An incision may also be made in the right linea semilunaris, beginning one or two inches above **POUPART'S** ligament. The chief objection to this form is that the deep epigastric artery is in the way, and will probably be divided; if this is the case, then it must be secured by a double ligature before division. (5) **BULL** (New York) makes an incision from the middle of **POUPART'S** ligament, vertically upwards, or even a little outwards.

Treatment of the Appendix.—There are two chief methods—(1) Simply to ligature the appendix near the cæcum, and cut off the part beyond the ligature. This plan often does very well, but there is considerable risk, on account of the septic matters in the gut and stump of the appendix, that a process of septic ulceration be set up, which will open up the ligatured appendix and cause septic peritonitis. (2) A much better and safer plan is, when the appendix is removed, to invaginate the cut edges of the stump, and stitch them in that position. First turn in the mucous and muscular coats, and introduce a few stitches, and after this tuck in the peritoneal coat, all the way round, like a hem, and keep

it in this position by introducing half-a-dozen or so of LEMBERT'S sutures. Should the stump be long, it will be advisable to fasten it to some neighbouring part, lest, if left free, it may contract adhesions elsewhere, and form a loop under which the gut may be strangulated at a later date.

Development of the Alimentary Canal.—The mouth is formed by an involution of parts of the face, and at first forms no part of the alimentary canal ; this part, therefore, is of epiblastic formation, and is known as the **stomodæum**. It is usually stated that this involution joins the fore-gut about the region of the pillars of the fauces, but Mr SUTTON states that the point of junction is on a level with the cricoid cartilage. From the **fore-gut** are developed the gullet, stomach, and part of the duodenum ; and in connection with different parts of these the rudiments of the lungs, liver, and pancreas. The fore-gut and the stomodæum ought to meet and join at the cricoid cartilage. In some cases, however, they do not do so, and then the gullet communicates with—or rather, has not separated from—the windpipe. In other cases, a thin membranous partition may only intervene, or this partition may be perforated in the centre, and form a congenital stricture of the œsophagus, at the level of the cricoid cartilage. From the **mid-gut**, the greater part of the small and large intestines are developed. According to Mr SUTTON, the fore-gut and mid-gut should join just above the entrance of the bile duct. Here, again, the two parts may be separated by some distance, or the partition between them may be only partially absorbed, or not absorbed at all, thus forming either a complete or perforated septum in the gut at this point. The jejunum and ileum project as a loop through the as yet cleft abdominal wall, with the allantois and vessels of the umbilical cord. The portion of the loop which becomes the ileum is originally continuous with the umbilical vesicle through the omphalo-mesenteric, or vitello-intestinal duct, through which the contents of that vesicle are absorbed as nourishment to the foetus till the placenta is in working order. This duct should entirely disappear, but sometimes it persists as a tube of greater or less length, passing between the lower part of the ileum and the umbilicus, when it is known as MECKEL'S diverticulum. Occasionally it remains patent, and then fæcal matter is discharged at the umbilicus; usually, however, it

forms a blind tube two or three inches in length, from one to three feet above the ilio-cæcal valve.

Clinical Relationships of Meckel's Diverticulum.—(1) It may produce intestinal obstruction by forming adhesions to neighbouring parts, compressing the gut below it, or may form nooses or knots or kinks, and thus obstruct the lumen of the tube, or it may, by traction, entirely obliterate the lumen of the gut. Its free end may be club-shaped, hammer-shaped, pointed, etc. (2) It is the probable source of many of those cases of umbilical fæcal fistulæ met with in children. (3) The possibility of its presence is one reason why the umbilical cord of the newly-born child is tied three finger's-breadth from the child's belly, as already pointed out. (4) As the duct, when present, is sometimes adherent to the umbilicus, in all cases where the abdomen is opened for the relief of internal strangulation, the finger should be introduced and swept over the internal surface of the umbilicus to at once make sure of its presence or absence.

From the **hind-gut**, only a very small part of the alimentary canal is developed—viz., the lower end of the colon and the rectum. It should be particularly noted that the cæcum and colon lie, in their early stage, to the left of the mesial plane, on a level with the umbilicus. After this the cæcum mounts up into the left hypochondrium, passes in front of the duodenal loop, through the epigastric region, into the right hypochondrium, and then descends through the right lumbar region into the right iliac fossa. In some cases the descent does not take place, and it then remains in the right lumbar region, or even in the right hypochondrium. In other cases it may pass too far, descending into the pelvis. In short, the cæcum may be arrested finally in any part of its journey from the left side of the umbilicus to the right iliac fossa. In the child the sigmoid flexure is very long, but the rest of the large gut is very short.

The anus is formed in a precisely similar way to the mouth—viz., by an invagination of the epiblast, which at length opens into the hind-gut; this invagination is known as the **proctodæum**.

Malformations of the Lower End of the Large Intestine.—(1) The anus may be congenitally narrow. (2) The anus may be completely closed by a thin membranous septum, while the rectum

is normal. In this case the distended rectum may cause it to bulge, and the dark colour of the contained meconium can be seen through the thin septum. (3) The anus may be normal, but be separated from the hind-gut by an inch or more of intervening cellular tissue, or merely by a membranous septum, due to the imperfect coalescence of the hind-gut and proctodæum. (4) The anus may be absent and also a considerable part of the rectum, the lower part being merely represented by a fibrous cord. The rectum may even end in the iliac fossa. (5) It may open into the urethra, or more rarely the bladder, of the male. (6) It may open into the vagina of the female—(a) the gut opening directly into the vagina, while the lower part and anus are wanting; or (b) in the form of a recto-vaginal fistula, while the lower part of the gut is present, the anus being closed merely by a thin septum.

In order to explain the occurrence of these malformations, one has to bear in mind how the lower part of the gut is developed. Up to the seventh or eighth week of foetal life, in both sexes, the genital, urinary, and intestinal tubes open into a common cavity or cloaca, a condition which is permanent in reptiles and birds. About this time a transverse partition forms, dividing this cloacal aperture into an anal or posterior division, and an anterior division, called the *uro-genital sinus*. In this way the rectal and urinary parts become permanently separated from each other. In cases, however, where the rectum opens into the urethra in the male, or the vagina in the female, this separation has not taken place, but the original communication between the Wolffian duct in the male, and the Müllerian duct in the female, is maintained. In other cases, where the rectal is completely shut off from the urinary part of the sinus, the malformations are explained by the absence of the proctodæum, or, if it be present, by the fact that it does not join the hind-gut. The kidneys are often imperfectly developed, or even absent, in cases of congenital rectal malformations.

Treatment.—Where the anus is too narrow it must be dilated by tents. Where the *anus* is closed by a thin septum, open by crucial incision, and dilate with the tip of the little finger; some stitch the four corners of the divided septum to the edge of the anus. Where the *rectum* is closed by a thin septum, the anus being normal, pass an ear speculum up to the septum, and then

open it by a tenotomy knife, or trochar and cannula. All incisions must be made in the axis of the pelvis, *i.e.*, with an *inclination towards the sacrum*. In cases where a part of the rectum is absent it is often difficult to know what to do. If the rectum ends *in the pelvis* the ischial tuberosities will be much further apart than when it ends *in the iliac fossa*. If, then, we have reason to believe that the lower end of the gut is in the pelvis an effort may be made to find it from the perineum. The chief points to be attended to are—(a) The small size of the pelvis and the relations of the bladder and the internal iliac vessels; (b) the bladder must be emptied lest it be mistaken for the distended rectum; (c) a sound should be passed into the bladder, in the male, and the vagina in the female, to act as guides to the operator; (d) a crucial incision will give most room for the finger, and it should be made in the position of the anus; (e) all the deeper incisions must be made exactly in the middle line, and in the axis of the pelvis. Very often the bowel can be felt bulging when the child cries, or when the abdomen is pressed upon by an assistant. (f) Try, if possible, to bring the mucous membrane down to the external wound, otherwise the risk of extravasation of fæces and consequent pelvic cellulitis is very great. In cases where the gut opens into the urethra in the male, or the vagina in the female, plastic operations will be required.

In cases where the gut cannot be found by the perineal route, or in cases where plastic operations are out of the question, we may—(1) Perform left inguinal colotomy (LITRÉ). (2) Perform right inguinal colotomy (HUGUIER), as the colon, it is said, frequently bends to the right, when there is no rectum. One very serious objection to opening the cæcum, or any part of the ascending colon, is that the fæces in this part of the gut are very fluid, and cause great irritation around the artificial anus, in spite of the greatest possible care. (3) Left lumbar colotomy may be performed (AMUSSAT). The objections to this operation are that the colon is often loose and takes an irregular course in the child, malpositions are very common, and there may be a long meso-colon. (4) Lastly, we may perform abdominal section, search for the end of the gut, and do the best under the circumstances.

Lymphatics of the Intestines.—The glands of the small gut are very numerous, and lie between the two layers of the mesentery,

with the mesenteric vessels. The glands of the large gut are much less numerous. The lymphatic vessels of the small gut are called *lacteals*; they pass through the mesenteric glands and terminate in the thoracic duct. The glands at the lower end of the small gut are enlarged in typhoid fever. The lymphatics of the descending colon and rectum pass to the *lumbar* glands. In **tabes mesenterica**, which consists of tubercular inflammation of the mesenteric glands, with subsequent caseation, suppuration, or calcification, the functions of the glands are destroyed, and, therefore, the substances which the lacteals should absorb (the fatty matters) are lost to nutrition. Hence the emaciation, the enlarged and tender abdomen, the drawing up of the legs, the voracious appetite, as the child always feels hungry, and the diarrhoea, from the fatty matters passed per rectum, as well as the tubercular inflammation of the mucous membrane of the gut.

CHAPTER XXXVII.

THE ABDOMEN—(Continued).

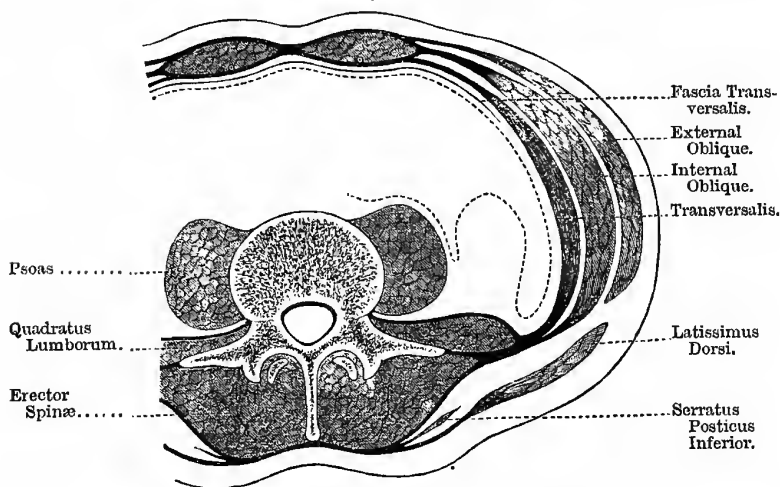
COLOTOMY.

The Posterior Abdominal Wall (Fig. 178).—The posterior abdominal wall (between the last rib and the iliac crest) is formed

Fig. 178.

ABDOMINAL WALLS.

(From CUNNINGHAM'S "Abdomen.")



The dotted line represents the Peritoneum. In front the mode of formation of the upper part of the Sheath of the Rectus is shown.

by two large muscles and the *fascia lumborum*, or the posterior abdominal aponeurosis. The *fascia lumborum* is formed thus—

The aponeurosis of the transversalis muscle splits into three layers, one is attached to the roots of the transverse processes of the lumbar vertebræ, a second is attached to the tips of the transverse processes (between these two layers the quadratus lumborum is situated), a third passes to the tips of the spinous processes of the vertebræ, and between this and the second layer, the erector spinæ is placed. These three layers are likewise known as the anterior, middle, and posterior layers of the lumbar aponeurosis; in addition, however, to these structures, there is attached to the posterior layer of this aponeurosis the tendons of origin of other three muscles, and through it these muscles may be said to arise from the tips of the transverse processes. The muscles are— (1) The latissimus dorsi; (2) the serratus posticus inferior; and (3) the internal oblique. By this means the strong fascia lumborum is formed, which protects the part below the ribs, a part which, in the skeleton, seems very weak. In this region we find the “triangle of Petit” (Fig. 179, 10). It is bounded in *front* by the posterior edge of the external oblique; *behind*, by the anterior edge of the latissimus dorsi. The *base* is formed by the crest of the ilium (about its middle third), while the *apex* is formed by the crossing of the above two muscles.

In Lumbar Colotomy, or Amussat's operation, the descending colon is opened in the left lumbar region. This operation was first suggested by CALLISEN in 1796, for rectal obstruction. AMUSSAT opened the colon in the right loin, revived CALLISEN's plan, and gave the operation a wider application, in 1839. CALLISEN used the vertical incision, while AMUSSAT used the transverse. The colon lies, according to ALLINGHAM, half-an-inch behind a point midway between the anterior and the posterior superior iliac spines. Mr HEATH takes the midpoint between the two spines, while Professor CHIENE uses the outer edge of the erector spinæ as the guide. At the seat of the operation the gut lies in the angle between the psoas and the quadratus lumborum (see Fig. 178). The descending colon (left) is chosen because— (1) It is nearer the anus, and the gut will therefore be emptied more perfectly after the new anus is formed, and there is less risk of irritation of the cancerous mass in the rectum. (2) It is more fixed than the right colon. (3) It has a larger non-peritoneal

surface. (4) A meso-colon is less frequently found on this side. (5) The contents of the gut are less fluid than on the right side. In a *child*, the danger of wounding the peritoneum would be much greater, because a descending meso-colon is often present.

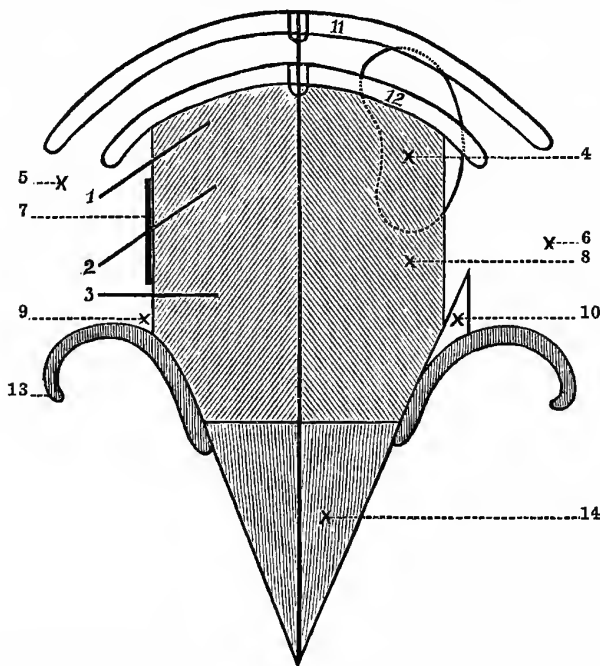
The patient is placed somewhat on the right side, and the loin of the side to be operated upon made prominent by placing a pillow beneath the opposite side. The instruments required are the same as for gastrostomy, except that we will require some special apparatus for inflating the gut if it is empty, as the peritoneum is in great danger if the gut is not distended—such as LUND's apparatus—and some tube and evacuator for emptying it if it be full, and if the operation is to be done in one stage. The Surgeon stands behind the patient, and with a tape measures the direct distance between the anterior and the posterior superior iliac spines, and makes a mark at the mid-point, or half-an-inch behind it, and draws a line from this vertically upwards to the costal margin—usually near the tip of the last rib. Various forms of incision may be used; the oblique is very frequently adopted (Fig. 179, 2), and is the one Mr BRYANT prefers, as there is less risk of prolapse of the bowel afterwards. It is four or five inches in length, and is made parallel with the intercostal nerves and the last rib, and midway between that bone and the iliac crest; its centre is placed opposite the ink line made in the ilio-costal space. (1) The skin and superficial fascia are divided, with fatty tissue, cutaneous vessels, and nerves. (2) The deep fascia is next divided, and then parts of (3) the latissimus dorsi, at the posterior end of the incision, and (4) the external oblique at the anterior part, are exposed and divided; these muscles, as well as those that follow, must be divided to the full extent of the superficial wound. Next (5) the internal oblique is divided in the same manner, and probably a small piece of (6) the serratus posticus inferior muscle. In the wound, part of the transversalis muscle with its undivided aponeurosis, and the posterior lamella of the fascia lumborum is exposed; further, at this stage we will find the last dorsal nerve and artery. They run outwards in front of the quadratus lumborum along the lower border of the last rib, and at the outer border of the muscle pierce the undivided aponeurosis of the transversalis muscle and pass forwards between

it and the internal oblique. Open (7) this aponeurosis in the same way as the sheaths of arteries are opened, and enlarge the incision upon a director; in so doing it will probably be found that the compartment containing the quadratus lumborum is opened up, as well as the undivided aponeurosis, and if the muscle it contains is in the way, its edge may be freely notched. This care is necessary in opening the aponeurosis, lest by the too free use of the knife the peritoneum should be punctured. The edges of the incision are now to be held aside with broad copper spatulæ, and the fatty tissue often found teased aside, when (8) the fascia transversalis is exposed and must be carefully torn through with the fingers or a blunt director, at the posterior angle of the incision, as it lies in front of the quadratus lumborum muscle. The extra-peritoneal fat, against which the colon rests and in which the kidney is embedded, at the upper part of the wound, is then displaced by the finger, which is passed in at the wound to hook the colon forward. The gut may be recognised by its relation to the kidney, which can easily be felt at the upper part of the wound, the gut passing downwards off its anterior surface. In cases where there is great difficulty in finding the gut, the patient may be turned on his back, when the gut will probably fall against the finger; or the gut may be inflated with air by the plan introduced by LUND, or by carbonic acid gas, generated by introducing solutions of bicarbonate of sodium and tartaric acid, separately, into the rectum. The remaining steps of the operation will vary according to the nature of the case. In all cases, where possible, the operation should be done in two stages, just as gastrotomy—an outer row of sutures being used to fix the gut to the fascia at the bottom of the wound, and an inner row, to attach it to the skin. If this is not possible from the nature of the case, the *non-peritoneal* surface of the gut is brought to the wound, and a large curved needle with a stout silk ligature is passed, at the upper and lower parts of the wound, through the skin, then across the bowel, and then through the skin at the opposite side. The threads are then to be given to two assistants, who thus hold the bowel steady and pulled well forward into the wound. The gut is then opened by a longitudinal incision between the two threads, and the finger is next passed into the bowel and the loops drawn

out and divided, and the four ligatures thus formed tied; or the fluid feces may first be drawn off through a large tube, as in

Fig. 179.

POSTERIOR ABDOMINAL WALL, FROM BEHIND.



1. Incision for Operations on the Kidney.

2. Oblique Incision for Colotomy.

3. Transverse Incision for Colotomy.

4. Right Kidney.

5. The point at which to tap the Left Kidney.

6. The point at which to tap the Right Kidney.

7. Vertical Incision for Colotomy.

8. Erector Spinae.

9. The point at which to open a Psoas Abscess posteriorly (CHIENE, 1878).

10. Triangle of Petit.

11. 12. Last two Ribs.

13. Iliac Crest.

14. Sacrum.

ovariotomy, to lessen the risk of extravasation into the cellular tissue behind the peritoneum. The extremities of the wound are

then to be partially closed, and every means taken, by additional stitches, to prevent the escape of fæcal matters into the cellular tissue. The opening thus made in the colon is close to its junction with the splenic flexure. It is recommended that the gut be brought well out into the wound, so as to form a good large "spur," which will prevent the fæces, as far as possible, from passing down into the rectum to irritate the cancerous surface. On the right side, the steps of the operation are exactly alike. To avoid the inconvenience experienced by the accumulation of fæcal matters between the opening in the colon and the seat of the obstruction, MADELUNG cuts the bowel entirely across and stitches the upper end of the divided gut to the edges of the abdominal wound. He then empties the lower segment, washes it out, invaginates, and stitches up its divided end, and drops it into the wound and closes the skin incision over it. This lessens the irritation of the cancerous surface by the presence of fæcal matters, and probably also will lessen the tendency to prolapse of the mucous membrane of the gut. He originally proposed this method for cancer of the rectum and sigmoid flexure.

In the transverse form, the incision (Fig. 179, 3) is made two finger's-breadth above and parallel with the middle third of the crest of the left ilium, making the middle of the incision over the colon. By this incision the structures divided are practically the same as those cut in the oblique form, and the gut is reached through the triangle of PETIT.

The vertical incision (Fig. 179, 7) is the one used by Professor CHIENE, and is made along the outer edge of the erector spinæ, between the last rib and the iliac crest, and in this case the structures divided are—(1) The integumentary coverings; (2) the posterior layer of the fascia lumborum—and in doing so the compartment containing the erector spinæ is opened into, and this muscle is then drawn inwards; (3) the middle layer is next divided, and with its division the compartment containing the quadratus lumborum is opened, and this muscle in turn is drawn well inwards; (4) the anterior layer of the fascia lumborum; (5) the fascia transversalis; and (6) the loose areolar tissue and fat in which the gut is embedded. The gut may be recognised at the bottom of the wound by its greenish and distended appearance.

By using this incision we have well-marked anatomical guides, both in the superficial and deep parts of the wound—the edge of the erector spinæ in the one, and the edge of the quadratus lumborum in the other. It is the centre of this latter muscle that we first reach; but by working a little forwards, its edge is reached and can readily be drawn inwards, or if it is specially well developed, it may be partially divided.

The objections to lumbar colotomy are—(1) The space is small; (2) it is often difficult to identify the bowel, and this has led, in some cases, to opening the duodenum (on the right side), other parts of the small intestine, and even the stomach; (3) the wound is often deep, so that it is impossible to stitch the bowel to the skin without undue tension; (4) occasional, or even frequent abnormalities of the colon, and failure to find it at all; and (5) the patient is unable to attend to the artificial anus himself.

In performing the operation of colotomy, it is necessary to **avoid**—(1) Wounding the peritoneum; (2) allowing the contents of the gut to become effused into the areolar tissue of the wound; and for this purpose, in cases where the gut must be opened at once, a wide india-rubber tube should be introduced into the opening, to allow the contents to escape gradually through it. After this, the sides of the opening in the gut are stitched to the sides of the incision, as already described under the first form of incision. The operation may be **rendered necessary** on account of—(1) Malignant stricture of the rectum with tenesmus, such as from cancer; (2) other strictures, such as from pressure of a pelvic tumour; (3) imperforate anus or other congenital defects; (4) volvulus of the sigmoid flexure, as the incision in laparotomy is too small to allow of the large coil being dealt with properly; (5) in all forms of vesico-intestinal fistula; (6) sometimes in cases of very painful non-malignant stricture of the rectum, to rest the part for a time and allow it to heal; and (7) in cases of cancer of the neck of the uterus opening into the rectum. By performing this operation in the same way on the opposite side, the caput cæcum, or ascending colon, may be reached. As already stated, however, an artificial anus should not, if possible, be made in this situation, on account of the fluid nature of the fæces at this part of the gut.

RÉSUMÉ of left lumbar colotomy (*oblique incision*):—

1. Place the patient on the right side, with a pillow beneath the flank, to increase the space between the last rib and the iliac crest.
2. Measure straight from the anterior to the posterior superior iliac spine, and draw a vertical line up to the costal margin a little behind the mid point of this measurement: or the outer edge of the erector spinæ may be taken as the guide to the position of the gut.
3. Make an oblique incision, of which this line, or edge of the muscle, is the centre, through skin and deep fascia.
4. Then divide the external oblique at the anterior part, and the latissimus dorsi at the posterior part of the incision, and after this, the external oblique. This now exposes—
5. The posterior surface of the fascia lumborum, which is then opened like the sheath of an artery, and divided by a probe-pointed bistoury to the full extent of the external incision. In so doing, the last dorsal nerve and artery are divided—secure the artery at once.
6. Divide the middle layer of the tendon of origin of the transversalis muscle, exposing the quadratus lumborum which should be turned aside or notched if in the way. After that open the anterior lamella of the tendon of origin of the transversalis muscle.
7. Hold the edges of the wound apart by two copper spatulæ, tease through some fatty tissue often met with at this stage, thus exposing—
8. The fascia transversalis, which should be opened at the posterior part of the wound, the extra-peritoneal fat teased through, when the gut should now be reached.
9. The gut, if distended, will usually project into the wound, if not, inject air or fluid, or take the lower end of the kidney as the guide to its position, or turn

the patient on his back while your index finger is in the wound, when the gut will usually fall against it.

10. Roll the patient back on his side again, and prepare the gut for being opened either at once, or stitch it unopened to the edges of the wound, and open it after three or four days.

NOTE.—When the gut is distended the non-peritoneal surface is very much increased in extent (BOND) (Figs. 180, 181).

Fig. 180.

Fig. 181.

COLON AND PERITONEUM.



EMPTY.



DISTENDED.

Observe the effect of Distension of the Gut upon the amount of surface uncovered by Peritoneum.

In the vertical form of incision:—

1. Use the outer border of the erector spinæ as the guide, and make a vertical incision along it.
2. Divide the integumentary coverings.
3. Expose the edge of the erector spinæ.
4. Expose the outer border of the quadratus lumborum, which will be found a little more external, and passing from below upwards in an oblique direction; if necessary the muscle may be notched.
5. Cut through the anterior layer of the lumbar fascia, and, if necessary, notch it transversely; clear aside a little fatty and cellular tissue usually found at this point.
6. Open the fascia transversalis, and tease through the extra-peritoneal fat; the gut should now be exposed.
7. After this, proceed as in the last form of incision.

Litré's Operation, or Inguinal Colotomy.—In this operation the *descending colon*, or the *sigmoid flexure*, is reached in the iliac region by opening into the peritoneal cavity, and into the gut

through its peritoneum-covered surface. The incision resembles that for ligature of the external iliac artery. LITTRÉ operated on the left side. The incision is carried from a little above the level of the anterior superior iliac spine downwards and inwards, about an inch and a half above, and nearly parallel with, POUPART'S ligament, for two and a half or three inches. The incision must be external to the deep epigastric artery, and above the level of the deep circumflex iliac, with one-third above, and the other two-thirds below, the level of the anterior superior iliac spine.

The Structures divided are—(1) The skin and superficial fascia, fatty tissue and deep fascia, with the cutaneous nerves and the superficial external circumflex vessels; (2) the external oblique; (3) the internal oblique; (4) the transversalis muscle, with branches of the deep circumflex iliac artery; (5) the transversalis fascia and extra-peritoneal fat; and (6) the peritoneum. The operation should be done, if possible, in two stages, as gastrostomy. The large gut is distinguished from the small gut by the longitudinal muscular bands, and by the appendices epiploicæ.

LITTRÉ'S operation in the **left groin** was originally proposed for cases of congenital absence, or deficiency, of the rectum; in children, however, it is well to bear in mind that the sigmoid flexure is often misplaced, especially in cases of congenital deformity, and may be on the right side, or in the pelvis. For this reason it has been advised that the operation should always be performed on the **right side**, as one is almost certain to find either the sigmoid flexure or the cæcum in this region. It is also used in cases of stricture of the rectum and *lower* part of the sigmoid flexure. The operation is said to be less severe, and it places the anus in a more convenient situation, so that the patient can attend to it himself; for this reason also it should be preferred in the labouring poor, who are unable to afford a special attendant to attend to and keep the parts clean, when it is placed behind. Statistics, up to 1884, seem to show that it is somewhat more fatal than AMUSSAT'S operation; since that period, however, the mortality has fallen considerably.

Malignant and other stricture is very frequently situated in the flexures, and in the case of the sigmoid flexure, AMUSSAT'S operation must be performed.

This operation meets all the objections urged against lumbar colotomy, and also affords a means of exploring the abdomen, in obscure cases, before completing the operation. The objections urged against it are—(1) The greater tendency to prolapse of the gut, and (2) that it is not suitable for urgent cases, as the peritoneum is opened, and, therefore, fæculent material might reach that cavity. Still, by careful stitching, and the adoption of suitable precautions, the gut *may* be opened at once, though, no doubt, the operation is best performed in two stages.

RÉSUMÉ of the chief steps of the operation of inguinal colotomy:—

1. Take the same precautions, with regard to antiseptics, as in other operations opening into the peritoneal cavity—especially with respect to the clothes, hands, and instruments.
2. Make the incision. In making the incision, Mr CRIPPS pulls the skin a little inwards, so that when it is again relaxed the opening through the fascia transversalis and the peritoneum is on a different level; this makes the opening valvular, and it is more easily closed afterwards with a pad.
3. Secure all the bleeding vessels, and then open the peritoneum to nearly the full extent of the external wound.
4. Push the small intestine aside, recognise the large gut by the usual signs, or else pass a finger into the pelvis, find the rectum, and follow it upwards.
5. Pull a loop of the gut into the wound, and insert two provisional carbolised silk ligatures, two inches apart; they must do little more than go through the peritoneal coat. These sutures are to steady the bowel during the stitching operations, and afterwards to serve as guides when the bowel is to be opened.
6. Now return the loop of bowel, and stitch the parietal peritoneum to the skin at four or five points with fine carbolised silk.

7. Again pull out the bowel, and fix it to the skin and parietal peritoneum by half-a-dozen sutures or so on each side. They must only go through the peritoneal and muscular coats of the bowel, but must not penetrate the mucous membrane, otherwise it will be impossible to keep the wound aseptic, on account of the leakage along the sutures. The gut should be so stitched that two-thirds of its circumference is external to the wound. The sutures pass through the skin one-eighth of an inch from the edge of the wound, then through the parietal peritoneum, and, lastly, through the bowel. The last suture at each angle should go across from one side to the other: it is better to pass all the sutures before tying any of them.
8. Stitch up the extremities of the skin incision as far as may be thought necessary.
9. In dressing the wound, place a piece of green protective over the exposed part of the bowel, otherwise granulations will shoot into the dressing and fix it firmly to the gut.
10. Open the gut in five or six days, using the provisional sutures as the guide, the bowel being opened to the full length between them, paring off the cut margins of the bowel with scissors to the level of its attachment to the skin (CRIPPS). All sutures may be removed by the ninth day, or earlier.

In order to obviate the tendency to prolapse of the gut, Mr CRIPPS, before inserting the provisional ligatures, draws out as much of the loose bowel as will readily come, passing it in again at the lower angle of the wound; this gets rid of all loose folds of the sigmoid flexure above the opening. Some Surgeons bring the loop of bowel *completely outside* the abdomen, in order to secure a good spur, and entirely prevent fæces passing by the rectum. The loop is held forwards by means of a kangaroo tendon suture, entered about an inch from the edge of the wound, then passed through the mesentery in the concavity of the loop of gut, and brought out about an inch from the edge of the other side of the

incision; both ends of the tendon are then knotted. The occasional tendency to contraction of the new anus must be overcome by means of special dilators.

LITTRÉ'S operation may also be performed on the right side, in this case opening the cæcum; this side is also to be preferred in cases of long standing intestinal obstruction. The fluidity of the fæces, however, must ever be a serious objection to all *right* colotomies. This subject is ably discussed by Mr F. TREVES, in his work on "Intestinal Obstruction."

LAPAROTOMY.

This may be defined as the making of an opening into the abdomen, either for the purposes of diagnosis (exploratory) or treatment, or both. It is used in cases of acute strangulation of the gut, of all kinds and from all causes, such as constricting bands, cords, diverticula, strangulation through slits and apertures, etc. It is also used in treating all kinds of internal hernia, and of reduction *en masse* after external hernia, provided the condition cannot be relieved by cutting down at the seat of the hernia first; also for some cases of volvulus, and in intussusception. The incision is the same as in ovariectomy; it is used as a preliminary operation in cases where enterotomy, enterectomy, etc., is to be performed. I will not describe the operation in detail, but merely indicate the more important points; the whole operation must be conducted on the same principles, and with the same care, as ovariectomy. The patient is placed on a high table, with his legs hanging over the end of it, and an incision, sufficiently large to admit the hand, is made between the pubes and the umbilicus through the *linea alba*; by making the incision in the *linea alba* no vessel of any size is divided, no inter-muscular cellular planes opened up, the wound is not deep, and its edges can be readily approximated without any tendency afterwards to hernial protrusion of the bowel.

The instruments required are the same as in gastrotomy, and the instrument clerk should have all the instruments, especially the sponges and WELLS'S forceps, carefully counted and noted, so that he may call the roll before the wound is stitched up, lest any of them be left in the abdominal cavity. The temperature of the room must be carefully regulated and the bladder emptied before

the operation, lest it be cut into. When the outer surface of the peritoneum is exposed all bleeding vessels must be secured before it is opened; it should be opened like the sheath of an artery, and the opening enlarged with a probe-pointed bistoury, guided by the forefinger of the left hand; and after it is opened, care must be taken to prevent protrusion of the intestines. If the operation be performed for obstruction, the hand should first be swept under the umbilicus, to make sure of the absence, or otherwise, of MECKEL'S diverticulum, and then passed on at once to the cæcum; for if this be found distended, the obstruction is in some part of the colon; while, if empty, it is in some part of the small intestine. At the completion of the operation the "peritoneal toilet" must be performed with the greatest care and completeness. In closing the wound the deep sutures of carbolised silk must include the peritoneum, so that the divided sides of that membrane shall be brought into close contact and unite by the first intention, and so lessen the tendency to hernia afterwards.

ENTEROTOMY.

Nélaton's Operation for Intestinal Obstruction—Enterotomy. —The abdomen is opened in the iliac region, preference being given to the right side, by an incision the same as that used in LITTRÉ'S operation—parallel with and a little above POUPART'S ligament, and external to the deep epigastric artery. The first *distended* coil of bowel that presents itself is then drawn into the wound; on the right side it is almost always the lower end of the ileum that presents. The operation is completed in one or two stages, according to the nature of the case; if possible it should be done in two stages, in the manner already explained under "*gastrostomy*." MR TREVES objects to *primary* enterotomy on the following grounds—(a) It is only a palliative measure at the best; (b) it is not founded upon sound surgical principles; (c) it is carried out more or less independently of diagnosis; and (d) it is done in the dark, and leaves the *cause* of the disorder untouched. It may often, however, be performed with advantage as a *secondary* operation—*e.g.*, after lumbar colotomy, where the colon is exposed below the obstruction; sometimes, after an exploratory laparotomy, it may be found that nothing else can be done. In favour of the

operation (*primary*) is its low mortality, ease of performance, and the almost absolute certainty of securing *something*, and of making an opening in the gut *somewhere* above the obstruction.

RESECTION OF THE INTESTINE.

In this operation a diseased portion, of varying size, is cut away and removed from the body. It may be performed for stricture, simple and cancerous, occlusion of the gut by hopeless matting, and for gangrene. It is called **Enterectomy**, when performed on the small intestine; **Colectomy**, when performed on the large. Colectomy was first performed by MR BRYANT. In many cases it is the only operation which *cures* the disease, and, therefore, possesses this great advantage over *enterotomy*; and it, further, does away with the necessity for a permanent artificial anus. As regards the amount that *may* be removed, it is difficult to state definitely, but a couple of yards have been removed without any apparent damage to the intestinal tract, so far as function was concerned.

There are two modes of performing the operation—(1) The part of the gut is removed, and the two divided ends are reunited, thus restoring the lumen of the tube; the gut is then put back into the abdomen, and the external wound closed.

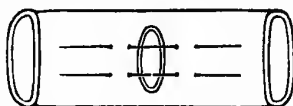
The objections to this plan are—(a) Although the obstructing part is removed, yet the distension of the gut above, remains for some time after the operation, as the segment of the bowel involved in the operation is paralysed for a time, and prevents a free passage along the tube. (b) The operation is very difficult, long, and tedious, and this is bad for the patient, who probably before the operation was already in a low condition, and the long exposure may cause fatal paralysis of the gut. (c) It may be impossible to suture the gangrenous bowel, or the suture line may slough and lead to extravasation and death.

For these reasons the next method should always be preferred—(2) Instead of stitching the divided ends together, an artificial anus is formed by the ends of the divided gut being stitched to the skin incision, first the distal and then the proximal. At a later period another operation is performed for the cure of the artificial anus.

In the first method, a median laparotomy is first performed, and the diseased segment of the gut is pulled out at the wound; the wound is then plugged with clean flat sponges, to prevent the entrance of fæces into the abdomen from the segment to be excised, and also to prevent the protrusion of more bowel. The bowel must now be occluded on each side of the part to be excised by some form of clamp; the one invented and used by

Fig. 182.

LEMBERT'S SUTURE—SURFACE VIEW.



Two Sutures are passed through the Gut at the wounded point.

Fig. 183.

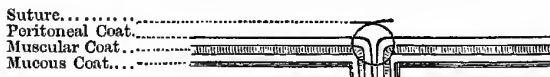LEMBERT'S SUTURE—SIDE VIEW.



The Suture must not go through the Mucous Coat.

Fig. 184.

LEMBERT'S SUTURE TIGHTENED.



Observe how the Peritoneal Surfaces are tucked in when the Suture is tightened.

Mr TREVES has its compressing surfaces covered with india-rubber, and it is so made that the two ends can slide along iron rods, so as to approximate the ends of the divided gut before the introduction of the sutures. The necessary amount of gut is then removed with the scissors, and a V-shaped piece of the mesentery removed, and all the bleeding vessels ligatured. The two parts

of the clamp are next approximated and two rows of sutures introduced—the inner to bring the edges of the mucous membrane together (CZERNY), and an outer row to include the muscular and serous surfaces (LEMBERT). GUSSENBAUER brings both the mucous and serous layers into contact by a single suture. The LEBERT suture is to be preferred, and is quite sufficient alone (Figs. 182 to 184. When the mucous membrane is pierced, leakage takes place along the thread, and is apt to set up septic peritonitis, and it should not therefore penetrate the mucous coat. When the gut is divided the longitudinal muscular fibres retract and carry the serous covering with them, so that the mucous coat can be readily reached and sutured. Various plans have been tried in order to make the gut rigid during the introduction of the sutures—such as plugs of gelatine or dough, decalcified bone, a sausage-shaped india-rubber bag that can be inflated, etc. According to Mr TREVES, about fifteen sutures are required for the inner row, and twenty-five for the outer. The clamps are now removed, the gut dropped into the abdomen, and the abdominal wound closed.

In the second method, when the diseased part is removed, the clamp is removed from the distal end of the gut, and its margin stitched to the skin incision; the proximal end is then treated in the same way, taking care not to allow the contents to escape into the peritoneal cavity. After a time the cavity of the gut is rendered continuous by a second operation. This method is much better, more easily performed, and safer than the other.

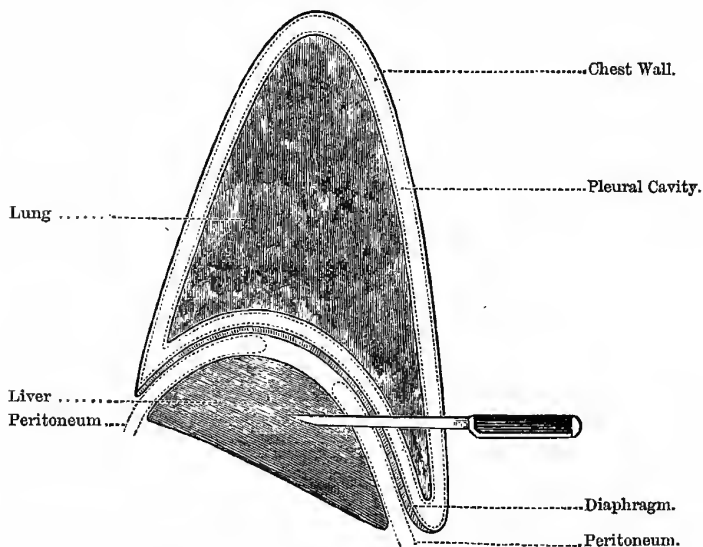
THE LIVER.

This organ fills up the greater part of the right hypochondriac region, extends through the epigastric, and passes slightly into the left hypochondrium, being about an inch and a half beyond the left margin of the sternum. It measures, in its transverse diameter, from ten to twelve inches; from six to seven in its antero-posterior, and is about three inches vertically, at the back part of the right lobe. It weighs from fifty to sixty ounces. The lower border, at the left side, is close to the apex beat; in the epigastric region it is midway between the ensiform cartilage and the umbilicus; and on the right side, from the mammary line, it follows pretty closely the costal margin; in the erect

posture it is a little below the costal margin, but when the patient is recumbent it ascends about an inch. In women and children it is normally a little below the costal margin. On the extreme right the lower border of the liver descends below the last rib to the level of the first or second lumbar spine—a fact of some importance when operating on the right kidney. Being attached to the diaphragm, the liver is depressed during inspiration and rises during expiration; at the end of expiration its upper border corresponds to the fourth intercostal space, or upper border of the fifth rib.

Fig. 185.

STAB THROUGH BASE OF LUNG.



To show how a Stab may involve the Lung and Liver, together with the Pleural and Peritoneal Cavities.

In the mammillary line, the highest part of the convexity of the right lobe of the liver extends to about the fourth intercostal space or fifth rib. If a line be drawn from this point to the apex

beat, it indicates the upper level of the liver, as well as the lower margin of the heart (*margo acutus*). A penetrating wound of the chest wall—say about the fifth, sixth, or seventh intercostal spaces—would go through both liver and lung, and open up both the pleural and peritoneal cavities (Fig. 185). The “**upper**” surface of the liver is in contact with the diaphragm; the **under surface** is in relation with the stomach on the left side, and on the right side with the gall bladder, the duodenum, the hepatic flexure of the colon, the right kidney, and right supra-renal capsule.

The **posterior border** is in relation with the aorta, the inferior vena cava, and the crura of the diaphragm. That portion of the liver that is in contact with the anterior abdominal wall gives an almost absolutely dull note on percussion, and is known as the **area of absolute hepatic dullness**; the upper border of this area corresponds roughly to the lower edge of the lungs (except on the left side, where it merges into the cardiac dullness), about the level of the sixth rib in front, the eighth in the mid-axillary line, and the tenth behind. Above this, a layer of lung tissue, gradually increasing in thickness, intervenes between the liver and the chest wall; this area is known as the **area of the relative hepatic dullness**. It lies about three inches above the absolute; extending up to the fourth right space or the fifth rib. The liver dullness may extend further down than normal, without great alteration in its absolute size or shape—as from (1) an abscess between the liver and the diaphragm, (2) right pneumo-thorax, (3) pleurisy with effusion on the right side, and (4) emphysema of the lungs. It is distorted as well as depressed in “tight lacing.” The hepatic plexus of the sympathetic is the largest offset of the coeliac plexus, and receives filaments from the left pneumogastric and the right phrenic nerves.

Tumours connected with the Liver necessarily partake of the respiratory movements, and in this way may be distinguished from tumours of the right kidney. Further, tumours of the liver have no intestine in front, and it is impossible to insert the fingers between the costal margin and the upper border of the tumour, as in tumours of the kidney; the dullness is continuous with the normal liver dullness, and the tumour enlargement begins above. In cases of cancer, the liver will be nodulated.

The Enlargements of the Liver may be—

- (a) **Uniform**—As fatty liver, waxy liver, congestion, obstruction of the bile duct either from catarrh or gall stones, and in the early stage of cirrhosis.
- (b) **Irregular**—In syphilitic affections usually, “gin-drinker’s liver,” cirrhosis, hydatid cysts, cancer, abscess, and distended gall bladder.

The liver is the *second* most common seat for the secondary deposits in sarcoma, spread by the *systemic* veins: it is the most common in sarcoma, spread by the *portal* vein. Secondary deposits of cancer are by no means uncommon, especially of the softer varieties.

Abscess of the Liver may arise from affections of the bowel, dysentery, typhoid fever, etc., probably from minute venous or lymphatic emboli—as the portal vein, that drains the intestines, passes to the liver, and there breaks up into capillaries. The abscess may open into the duodenum, colon, pleural cavity, or the lungs, and the pus be coughed out—or the stomach, and be vomited up. Sometimes it makes its way into the pericardium, or bursts into the general peritoneal cavity. The usual causes of these abscesses are injuries of the head, pyæmia, and dysentery; also wounds and contusion of the liver itself, irritation of the veins about the rectum as in fistula in ano, and after operations for hæmorrhoids; and, lastly, inflammation and ulceration of the stomach, gall bladder, or bile ducts.

The diagnosis between abscess and hydatid cyst may be made certain by the use of the hypodermic needle, or a fine aspirator; there will also be a history of fever and rigors in the one case, but not in the other, and with hydatids the fluctuation is often accompanied by the peculiar “hydatid fremitus.” If the abscess have adhered to the abdominal wall under the ribs, it may be tapped or opened by direct incision, cleaned out, and a drainage tube inserted; if it is not adherent, the case requires greater caution, lest the pus and discharges escape into the peritoneum. Attempts may be made to open it in two stages, as in gastrostomy. Hydatid cysts should first be tapped; and if this does not cure, then open in two stages, and drain.

Rupture of the Liver is very serious, from the great hæmorrhage and subsequent peritonitis.

Extra-Hepatic Bile Channels.—The bile leaves the liver by the *right* and *left hepatic ducts*; these join to form the *common hepatic duct*, which is in turn joined by the duct from the gall bladder (*the cystic duct*), and the duct thus formed is called the common bile duct—the *ductus communis choledochus*. It is about the size of a goose-quill, and about three inches long, and is placed, with the hepatic artery and portal vein, in the lesser omentum, the duct being to the right, the artery to the left, and the vein behind and between. Along with the duct of the pancreas, it pierces the duodenal wall *very obliquely*, near the end, and to the inner side of the posterior aspect of its descending part. In stones, passing from the gall bladder, as long as they are confined to the cystic duct, there will be no jaundice, as the bile, from the liver, can easily pass into the gut; it is only when they enter the common bile duct that jaundice becomes marked, but even then a little may pass into the intestine, as the stones are usually faceted. The secretion pressure is extremely low, and, therefore, a very feeble obstruction is sufficient to cause its re-absorption—*obstructive jaundice*.

Other causes of obstruction, leading to the re-absorption of bile, are—catarrh of the ducts, often due to duodenal catarrh (*duodenal dyspepsia*); parasites, as a round worm (*ascaris lumbricoides*); and tumours, as cancer of the head of the pancreas or pylorus, as the duct passes behind the first part of the duodenum and is covered by, or included in, the head of the pancreas.

The first inch or so of the common duct runs in the lesser omentum, and is here liable to be compressed from enlarged glands and other tumours; for the rest of its course it runs under cover of, and between, the duodenum and pancreas, and may be compressed by growths springing from these organs. When the ducts are blocked between the transverse fissure and the entrance of the cystic duct, there will be persistent jaundice, without distension of the gall bladder. When there is persistent jaundice, with continued dilatation of the gall bladder, it points to blocking of the common duct, as from stricture, calculus, or disease of the duodenum or pancreas. It is of importance to note that the

gall-stone colic may closely simulate obstruction of the bowel. Vomiting and constipation may be well marked, and there may be a total absence of jaundice. Slighter cases of pain, due to the passage of gall stones, are probably often merely called "spasm of the stomach" (HUTCHINSON).

Dr SYMINGTON describes the liver as a right-angled triangular prism with the right angles rounded off; he speaks of five surfaces—anterior, posterior, superior, and right and left inferior: the left inferior corresponds to the so-called inferior surface. He further regards it as a soft, plastic, sponge-like mass, easily changed in shape from pressure of neighbouring organs, especially by the stomach; when this organ was distended he found that the transverse diameter was considerably diminished, while the vertical extent on the right side was considerably increased, this change in shape being due chiefly to a movement of its left inferior surface.

This plasticity and sponge-like character may account, to a certain extent, for the beneficial effects of physical exercise. Professor RUTHERFORD used to teach us that the liver was like a sponge, and that the compression of the walls of the abdomen and chest around it squeezed out the bile. But physical exercise has another beneficial effect, as it quickens the venous return, by the aspiration of the thorax, through the inferior vena cava—so that at each inspiration the blood is drawn rapidly through it: it thus acts in two ways—by squeezing and by aspirating. It is no doubt for this reason that the hepatic veins have been made non-collapsible. This is seen to the best advantage in mountain climbing. Herein also, no doubt, lies the special value of laughter as a therapeutical agent. "A merry heart doeth good like medicine," said the wisest of men in ancient times; and "Laugh and grow fat," says the profane man of our own time. In this way *melan chole* is got rid of—by which is meant, I suppose, the stagnated products of the liver. The same may also be said for the jolting exercise on horseback, and also the great good derived from taking a few full and deep respirations occasionally. Here, also, I would point out one of the great evils of corsets, as worn by ladies at the present day; not only do they *keep* the liver constantly compressed, distorted, and semi-asphyxiated, but also render it impossible to take full and

deep respirations, or perform that physical exercise which would do it a world of good. For the same reason also they play an important part in the production of phthisis. It is impossible to take full and deep inspirations, and many parts of the lungs are thus thrown out of use, and as a result of this the tissues tend to degenerate, and fall an easy prey to the invading hosts of micro-organisms. Full and free respirations are the gymnastics of the lungs. Hence the value of the frequent practice of vocal music. The waist of the *Venus de Medici* in the Uffizi Gallery, at Florence, forms a graceful oval of nearly twenty-seven inches, but the waists of her modern representatives are reduced, by means of corsets, to an ungraceful circle of from eighteen to twenty-two inches. But not only do corsets distort the body and keep the liver semi-asphyxiated and inactive, because it is surcharged with stagnated blood, but, I believe, they also play a very important part—probably the chief exciting cause—in the production of cancer of the breast. At every step the woman takes the breast partakes of a quivering or trembling movement, and the nipple is irritated against the upper edge of the rigid corsets. This constant irritation of the nipple, over a long period of time, may play a more important part in cancer production than many are inclined to suppose; at any rate, in the cases of cancer of the male breast I have seen, there has always been a sufficient exciting cause, in the shape of local irritation, comparable to that which might be produced by corsets.

With a fair amount of attention to the more obvious laws of health, no one should be conscious that he has got such an organ; but, curiously enough, whether rightly or wrongly I do not say, it seems to be looked upon as the prime cause of half the diseases that afflict human male flesh—in short, it stands in the same relation to diseases of the male sex, that “utero-gestation,” or more correctly, constipation, seems to stand in relation to female diseases. There can be but little doubt, I think, that in most cases it is more sinned against than sinning.

In cases of disordered liver, pain is often felt in the right clavicle and tip of the shoulder; the exact cause is doubtful. It may either be due to conduction along the phrenic to the third and fourth cervical nerves, and then along the acromial branches to the

shoulder tip, or else to irritation of the vagus, transmitted along the spinal accessory, which communicates with the cervical nerves in the posterior triangle. Similar referred pains are also noticed in disorders of the stomach; thus in dyspepsia we find pain under the left scapula and in the loins and limbs, and in gastric ulcer pain is felt over the lower dorsal vertebræ, as well as locally.

THE GALL BLADDER.

The Gall Bladder lies in a depression on the under surface of the liver; its fundus is directed towards the abdominal wall, being directed downwards and forwards and to the right, and projects slightly beyond the anterior edge of the liver. It is about four inches in length, one inch in breadth at its widest part, and holds from eight to ten drachms. It is situated behind the ninth costal cartilage (opposite the tip of the tenth costal cartilage—*QUAIN*), close to the right linea semilunaris (see Fig. 176, *g*). It rests below, on the commencement of the transverse colon, and further back is in contact with the duodenum, and sometimes with the pyloric end of the stomach. In cases where the common bile duct is obstructed, as by gall stones, the gall bladder is distended with bile, often forming a large tumour. The swelling moves with respiration, since it is attached to the liver, and may be seen moving under the abdominal parietes as the patient breathes; further, it is egg-shaped, with the large end forwards. The patient may or may not be jaundiced. It will often be difficult to be quite sure what is the cause of the obstruction before actually cutting down upon it—whether from gall stones, catarrh of the duct or duodenum, or tumours, simple and malignant, pressing on the duct from without.

Cholecystotomy.—To relieve this condition the gall bladder has been opened by *LAWSON TAIT* and others, and the obstruction removed. This operation is known as “cholecystotomy.” The incision is made over the most prominent part of the tumour parallel with the linea alba, in the linea alba, in the linea semilunaris, or, perhaps best of all, obliquely, parallel with the costal margin. The operation may be done in one or two stages, as in gastrostomy. Care must be taken, in dislodging the stones, lest perforation take place.

RÉSUMÉ of the chief steps of this operation:—

1. Make an oblique incision over the most prominent part of the tumour, parallel with, and a little below, the costal margin.
2. Dissect carefully through the abdominal wall till the peritoneum is exposed, and then carefully arrest all bleeding vessels. After this—
3. Open the peritoneum and expose the fundus of the gall bladder, introduce a finger along the bladder and its duct, to make sure of the diagnosis.
4. Grasp the bladder by forceps, and pull it well into the wound; so arrange that the contents will flow out of, and not into, the peritoneal cavity, and then tap to draw off the collected fluid.
5. Holding the bladder still well up in the wound, by means of a large curved needle, insert four or six carbolised silk stitches, at a little distance from the edge of the incision, into the wall of the gall bladder, but, if possible, not entering its cavity, so as to avoid leakage along the stitches. This outer row of sutures is to secure a broad attachment of the peritoneal surfaces round the edges of the wound. After this the incision in the abdominal wall may be narrowed down as far as necessary.
6. Open the gall bladder by scissors in the middle of the exposed portion, and stitch the edges of the opening thus made to the skin margin of the abdominal wound by a close row of radiating stitches; these stitches protect the external wound.
7. Put in a finger and gently clear out the stones as far as possible; in cases where they are impacted near the cystic duct, rather leave alone than use force, lest you cause perforation.
8. Drain if necessary, dust with fine boracic powder, and dress in the usual manner.

The gall bladder may be entirely removed, after closing the cystic duct, by ligature, close to its entry into the common duct. This operation is called **Cholecystectomy**, and has been performed by KNOWSLEY THORNTON.

In cases of complete obliteration of the common bile duct, the gall bladder may be stitched to the jejunum, and, after adhesions have formed, an opening may be made from the gall bladder into the gut. This operation is known as **Cholecystenterostomy**.

Gall Stones.—The chief ingredients of gall stones are *cholesterine* and inspissated mucus; other matters present are colouring matter (*cholochrome*), phosphate and carbonate of lime and magnesia, biliary and fatty acids. They are distinguished from urinary calculi—(1) By being much lighter, when *dry*, they float in water; though when first taken out they are slightly heavier than water, and just sink. (2) They have a greasy or fatty feel. (3) The colour differs from the usual urinary calculi. (4) Their shape is more markedly faceted and triangular than urinary calculi. (5) Glistening fracture.

CHAPTER XXXVIII.

THE ABDOMEN—(Continued).

THE SPLEEN.

THE spleen lies far back in the left hypochondrium behind the stomach. Its **average size**, in the adult, is about five inches in length, three or four inches in breadth, and an inch or an inch and a half in thickness. It **weighs** about seven ounces. It is not placed vertically, as is often described, but lies very obliquely; "it is oblique in two directions—viz., from above downwards and outwards, and also from above downwards and forwards" (CUNNINGHAM). It lies parallel with, and follows the obliquity of, the ninth, tenth, and eleventh ribs; its "upper" extremity therefore points towards, and is not very far removed from, the spinal column. The **upper end** is attached to the diaphragm by the phrenico-splenic ligament; by this means, therefore, the organ partakes of the respiratory movements of that muscle—sinking during inspiration and rising during expiration. This is one valuable aid in the diagnosis of splenic tumours. Its **lower end** rests on the phrenico-colic (*costo-colic*) ligament, which, coupled with the natural obliquity of the organ, guides an enlarged spleen in a direction downwards and forwards towards the umbilicus. The **outer surface** rests against the diaphragm, which lies between it and the ribs before mentioned; between this surface, therefore, and the skin, we find the peritoneum, diaphragm, pleura covering the upper surface of the diaphragm, a wedge-shaped mass of lung tissue encased by pleura, the pleural "cavity," the ninth, tenth, and eleventh ribs covered with pleura on their inner surfaces, and, lastly, the soft parts of the chest wall. It will be evident, therefore, that the spleen cannot

be excised from its external aspect. The **inner surface** is concave, and is connected with the stomach by the gastro-splenic omentum—the structure which causes the most anxiety during excision of the organ, as it contains the large arteries and veins—the splenic and the vasa brevia. The **anterior border** is usually notched; this fact is useful in diagnosing enlargements of the spleen from other tumours. The lower or outer end of the spleen, in health, usually reaches midway between the posterior and mid-axillary lines, over the ribs already named. At this point it most nearly reaches the surface, and a small portion may be made out by percussion; as it passes upwards and backwards, however, from this point it is separated, as already mentioned, from the surface by the left lung and the thick layer of muscles of the back, and is beyond the reach of percussion. The splenic dullness is more evident when the patient lies on his right side, for then the spleen gravitates forwards; the normal spleen is best percussed when the patient is standing with the left arm removed from the side. In consequence, however, of the near presence of the stomach and the splenic flexure of the colon, it is necessary to percuss very lightly, in order to obtain its true position. The **splenic plexus** of the sympathetic is formed by branches from the right semilunar ganglion and from the right pneumogastric nerve.

Occasionally, a communication is formed between the splenic artery and vein, giving rise to **aneurismal varix**. The recorded symptoms are obscure—profuse hæmatemesis, very tender abdomen, diarrhœa, *bruit* over the region of the spleen, resembling a “venous hum,” bleeding from the bowels, and ascites.

Splenic Tumours and Enlargements are to be distinguished by the following points—(1) They move with the diaphragm during inspiration and expiration; (2) the position shifts by turning the patient over to the right side, when it gravitates forwards; (3) the mode of origin and course—they begin above in the left hypochondrium, and grow downwards and forwards towards the umbilicus, curving round in front of the fundus of the stomach and colon, and therefore have no bowel in front, as is the case with renal tumours; (4) the dullness is continuous with that of the normal splenic dullness; (5) they are usually painless; (6) the tumour has a *notch* in the anterior border, which is also sharp

and well defined; (7) by passing one hand into the ilio-costal space, outside the mass of the erector spinæ, while the other rests flat on the front of the abdominal wall, it may be possible to tilt up the tumour against the hand; (8) there is a line of resonance between the tumour and the vertebral spines, and the fingers can be readily dipped between the tumour and the spinal groove; and (9) its angle with the costal margin is greater than a right angle.

Causes of Splenic Enlargement.—It is enlarged *transiently* after every meal; more or less permanently in leucocythæmia, adenia or HODGKIN'S disease, waxy disease, recent syphilis, and in rickets, intermittent and remittent fever, typhus, typhoid, and scarlet fever, and in congestion, from over-filling of the portal system of veins, as from valvular disease of the heart and cirrhosis of the liver. The fibrous capsule of the spleen contains much non-striped muscular fibre, and therefore alters its shape easily. **Rupture** of the spleen is always a very serious accident, from the great hæmorrhage, and especially so in cases of enlarged spleen, as found in India. The free hæmorrhage is not to be wondered at when one remembers the large size of the splenic artery, and the absence of a proper system of capillaries.

Excision of the Spleen.—This operation has been performed for—(1) Wounds or injuries of the spleen, (2) floating spleen, (3) simple hypertrophy, and (4) malarial spleen. It must *not* be performed for the enlarged spleen of leucocythæmia; in sixteen cases where it was performed for this condition, *every* patient died. As regards the **incision**, it may be either made from the eighth costal cartilage along the left linea semilunaris to the required extent (see Fig. 176, 2), or in the linea alba, with its centre opposite the umbilicus. The details of the operation closely resemble those of ovariectomy—the spleen being isolated from its surroundings, and its pedicle clamped and finally secured by ligature; as already pointed out, the management of the gastro-splenic omentum, attached to the sides of the hilus, and containing the large vessels, forms the most difficult part of the operation. All traction on the pedicle must be avoided, lest the splenic vein be ruptured; the best results have been obtained in those cases where there has been naturally a long gastro-splenic omentum. In lifting out the organ, take care and not rupture its capsule.

Some trouble is also occasionally caused by adhesions between the spleen and the pancreas or even with the left kidney. The special dangers of the operation are (1) hæmorrhage from the omental vessels, (2) injury to the pancreas, and (3) injury to the dense plexus of sympathetic nerves in this region, in relation to the left supra-renal capsule: it is probably from this cause that persistent vomiting sometimes follows the operation.

THE KIDNEYS.

The Kidneys are situated in the right and left lumbar regions, opposite three and a half vertebræ—from the last dorsal vertebra to the middle of the third lumbar vertebra; the hilus of the kidney is opposite the first lumbar vertebra, and about two inches from the middle line. They lie entirely *behind* the peritoneum, embedded in loose areolar tissue, and are placed somewhat obliquely, the upper ends of the kidneys inclining towards the vertebræ. This oblique position is important, as in cases where the spine is bent much forwards, the kidney for this reason fits into the bend better, and with less chance of being crushed up. The size of each kidney is about four inches in length, two in breadth, and one in thickness—the left is somewhat larger, though thinner, than the right. The weight of the kidney in the adult male varies from four and a half to six ounces; in the adult female, from four to five and a half ounces, the left being nearly always heavier than the right by about two drachms.

Relations.—Each kidney rests on the corresponding crus of the diaphragm, quadratus lumborum, and psoas; or, rather, on the fascia covering these muscles. In **front** is the colon; at the **upper end** is the supra-renal capsule; the **lower end** is about two inches above the crest of the ilium. The above relations are common to the two kidneys; but there are certain special relations—in front of the right kidney is the second part of the duodenum; in front of the left, the pancreas; at the upper end of the right kidney is the right lobe of the liver; at the upper end of the left, the spleen. The right kidney is a little lower than the left, probably because the liver presses it down somewhat; the left kidney reaches to the upper border of the eleventh rib, but the

right only reaches to the middle of the corresponding rib on the opposite side; the left kidney is also longer and narrower than the right.

The **ureters** arise at the hilus of the kidney, from the dilated pelvis, and also pass down behind the peritoneum. Each ureter is about fifteen inches in length, and is about the size of a goose quill. At the upper part they rest on the psoas muscle, the genito-crural nerve, the *common iliac vessels* on the *left* side, but the *external iliac vessels* on the *right*, and then enter the posterior false ligaments of the bladder, pass across the rectovesical pouch of peritoneum, and run forwards by the side and base of the bladder, below the level of the obliterated hypogastric arteries, and enter the bladder wall about two inches distant from each other. They traverse the bladder wall very obliquely for about three-quarters of an inch, and then open internally about an inch distant from each other and fully one inch behind the urethra, so that the three openings almost form an equilateral triangle. This oblique perforation of the bladder does away with any necessity for a valve to guard the orifice, just as is the case with the bile duct. In cases of the so-called "**double ureter**," the extra ureter opens into the *uterus masculinus*, being, in fact, a persistent MÜLLER'S duct. Both ureters are crossed by the spermatic vessels, and the right ureter lies a little external to the inferior vena cava, while the left is a short distance from the aorta.

The Relation of the Kidneys to the Surface of the Body.
—**Anteriorly** (see Fig. 175).—According to Mr MORRIS, their position may be defined thus—(1) A horizontal line through the umbilicus is below the lower edge of each kidney, but the left is a little higher up than the right; and (2) a vertical line carried up from the middle of POUPART'S ligament, parallel with the middle line of the body, has one-third of the kidney to its outer side, and two-thirds to its inner side. **Posteriorly** (see Fig. 179).—(1) A line parallel with, and one inch from, the spinous processes of the vertebræ, extending from the lower edge of the eleventh dorsal spine to the corresponding part of the third lumbar vertebra; and (2) a line parallel with the first, and of the same length, but two inches and three-quarters to its outer side, will

mark the outer border of the kidney. By joining the upper and lower ends of these lines, a little box is marked out which corresponds to the position of the kidney.

In carrying the dissection through this box the following structures are found covering the kidney—(1) Skin, with the cutaneous branches of the lower dorsal and lumbar nerves, and cutaneous twigs of the intercostal and lumbar arteries; (2) deep fascia; (3) aponeurosis, and part of the muscular fibres of the latissimus dorsi; (4) serratus posticus inferior; (5) posterior layer of the aponeurosis of the transversalis; (6) the internal oblique—the external oblique muscle is also seen, as well as the last rib, and the lowest external intercostal muscle; (7) the erector spinæ muscle; and (8) then the middle layer of the aponeurosis of the transversalis muscle. The quadratus lumborum muscle is now exposed, and resting on its anterior surface are the anterior branches of the four lumbar arteries. (9) The quadratus and vessels are now removed, and after that (10) the anterior layer of the aponeurosis of the transversalis. (11) A quantity of loose adipose tissue is next to be removed, when the posterior surface of the kidney is exposed. Crossing the posterior surface of the kidney from above downward, we find (*a*) the anterior branches of the last dorsal vessels and nerve, (*b*) the ilio-hypogastric nerve, and (*c*) the ilio-inguinal nerve. To the inner side of the kidney is the psoas.

Tumours of the Kidney (1) usually first show themselves a little above and external to the umbilicus, filling up the hollow in the loin, and, further, it is usually *fixed in the loin*; (2) the resonant large intestine passes in front of the tumour; (3) they do not partake of the respiratory movements, as they are not attached to the diaphragm, although they may adhere to the liver and spleen, and when this is the case they will move more or less with the diaphragm; (4) there is no resonant line between the tumour and the spine; (5) it has no sharp-notched edge like the spleen, but is rounded *on every side*; (6) there is a peculiar fainting or sickening sensation when the tumour is handled; (7) it may sometimes cause varicocele; and (8) its angle with the costal margin is less than a right angle. In examining the kidney one hand is placed in the flank, with the fingers outside the mass of the erector spinæ, the other in front, outside the rectus abdominis.

Rupture of the Kidney is not necessarily so serious as rupture of the liver and spleen, and is often recovered from; the bleeding need not be great; and, further, it lies behind the peritoneum. Hydronephrosis is apt to follow should the pelvis be involved, as blood clots plug the ureter, and may subsequently undergo organisation and block up the orifice.

The kidney is apt to be displaced in the game of lawn tennis during the period of menstruation, especially if, at the same time, tight-lacing be indulged in; during menstruation the kidney is enlarged and heavier than at other times.

Primary Malignant Disease (*sarcoma*) of the kidney is very apt to occur in children. It may reach an enormous size, filling up the entire abdomen, and obliterating the inferior vena cava; hence, the whole of the blood from the lower extremities and abdomen must be conveyed through the superficial veins of the abdominal wall, and reach the superior vena cava through the internal mammary and intercostal veins. Fortunately, the pain caused by these growths is often very slight; there may be blood in the urine.

The relation between the right kidney and the **duodenum** should be specially noted, as many diseased conditions of this part of the gut may simulate kidney disease, as calculous pyelitis and the pain accompanying that condition, or attacks of renal colic. But in duodenal disease the pain, vomiting, etc., has a close relation to food, being most severe about three hours after food, as about that time the contents of the stomach pass into the duodenum; in ulcer and inflammation of the duodenum there is usually also a rapid loss of flesh. Further, note the relation of the kidney to the **colon**: in tubercular disease of the kidney the abscesses may open into the colon, or point in the loin. The left kidney may be reached by the finger, when the hand is introduced into the rectum; this fact has also been taken advantage of for the purpose of securing the kidneys after death without any visible mutilation. Another point of importance is that the transverse processes of the lumbar vertebræ jut out some little distance over the posterior surface of the kidney—probably about half-an-inch—and hence in puncturing the kidney with a needle from the surface to ascertain the presence of a calculus, without making a diagnostic incision

down to the kidney, the needle may strike a transverse process and lead to a mistaken diagnosis.

Hydronephrosis.—This is a chronic affection, and may occur at any period of life, and may even be congenital, causing obstruction during the second stage of labour; this seems to show that the kidneys secrete actively for some time before birth. It is a mechanical dilatation of the pelvis of the kidney, with atrophy, first of the malpighian pyramids, and finally of the whole interior of the organ, forming a large, often lobulated, *smooth-walled* cyst with a few ill-developed septa in its interior.

Causes.—It is caused by obstruction anywhere between the upper end of the ureter and the meatus urinarius. If **single** it must be from obstruction somewhere in the ureter of that side, as an impacted calculus, stricture from ulceration and inflammation of the ureter itself, or of the pelvis of the kidney, tumours of the pelvis of the kidney, as papilloma or sarcoma, tumours of bladder obstructing one ureter, compression by a tumour external to the ureter, unilateral pelvic cellulitis, especially in women, tumours and cysts of the ovary, or broad ligament, on one side, injury to, and subsequent organisation of a blood clot in, the ureter. In bad cases of single hydronephrosis the obstruction is usually either at the upper or lower end of the ureter. **Double Hydronephrosis**—where the obstruction is in, or in front of, the bladder, as stricture of the urethra, enlarged prostate, paralysis of the bladder following spinal injuries, widespread villous or other tumour of the bladder. Hydronephrosis is almost twice as frequent in females as in males, probably due to the frequency of pelvic cellulitis (utero-sacral) and cancer of the neck of the uterus, as the ureter in the female passes along the sides of the cervix uteri and upper part of the vagina. **Congenital Hydronephrosis** is usually due to twists of the ureter, arteries or bands passing in front of the ureter and compressing it, an abnormally narrow opening into the bladder, or a very narrow opening in the point of the penis. This condition is often associated with other deformities, as club-foot, hydrocephalus, and spina bifida.

From this relation of the ureter to the upper part of the vagina it occasionally happens that a **uretero-vaginal fistula** forms, from accidents during parturition, pelvic cellulitis, abscess, and

ulcerations. In this condition the water from *one* ureter comes away constantly, while the water from the other one collects in the bladder, which the woman herself can empty from time to time. This constant dribbling of urine, together with the occasional emptying of the bladder as in health, distinguishes uretero-vaginal from vesico-vaginal fistula, where the water *all* comes away in a continuous dribble when the patient is in the erect posture. A constant dribbling of urine is also a very early sign of retroflexion of the gravid uterus; this dribbling, however, is the overflow of an over-distended bladder, resembling the condition met with in the opposite sex from enlarged prostate, being really due to retention.

Pyelitis is an acute or chronic inflammation of the mucous membrane of the pelvis of the kidney. It is usually caused by calculi, or tubercle, either primary, or spreading from some other part of the genito-urinary tract. Note how the pain radiates in renal affections—along the line of the ureters to the bladder or testicle, causing retraction of that organ; it may also shoot down the thigh: there is also *local* pain in the lumbar region.

In **Abscess round the Kidney**, the thigh of that side is flexed to prevent the psoas pressing upon the inflamed tissue; hence, the patient is lame, and often walks with the body bent forwards and leaning to one side, and also sits on one tuber ischii, and is unable to extend the thigh. The knee joint is often complained of, and it is then apt to be mistaken for morbus coxæ; but when the thigh is flexed the pain is less, and the joint can be moved freely in all directions. Perinephritic abscesses are very apt to involve the pleura and lung, causing empyema, pneumonia, and abscess, or may open into the colon or bladder. It very frequently forms a "lumbar abscess."

Pyonephrosis.—This differs from hydronephrosis in that the fluid distending the pelvis is not water but pus: it is hydronephrosis, *plus* pyelitis.

"Surgical Kidney."—This may be defined as suppurative nephritis, pyelitis, or both together, forming *suppurative pyelonephritis*, and is usually *secondary* to obstruction to the outflow of urine, to reflex irritation, or to decomposition of the urine in the bladder, the micro-organisms then spreading up to the kidney. It is the worst form of "urinary fever." It is the constant risk

of "catheter life," where the prostate is enlarged, and there is a constant partial retention, or "residual urine;" it is probably in many cases begun by the use of an imperfectly-purified catheter. The residual urine is thus infected, the organisms thrive there, and then spread to the kidney; this is the beginning of the end, the signing of the patient's death-warrant. The moral of this is evident—*always purify catheters very thoroughly before drawing off the urine from a patient with obstruction in any part of the urethra, but especially in old men with enlarged prostates.*

It is one of the great risks, too, in cases where the spinal cord is destroyed above the lumbar enlargement, as by crushes, myelitis, etc.; the risk is during the first fortnight, when there is usually retention, and the urine has to be drawn off; after this period there is incontinence.

Supra-Renal Capsules.—The supra-renal capsules are situated behind the peritoneum, just in front of the upper part of each kidney. **Relations.**—The *anterior surface* is in relation, on the right side, with the inner surface of the liver; and on the left with the pancreas and spleen. The *posterior surface* rests upon the corresponding crus of the diaphragm, opposite the tenth dorsal vertebra: the *lower border* rests upon the upper end of the kidney: the *inner border* is in relation with the great splanchnic nerves and semilunar ganglia, touching the inferior vena cava on the right side, and the aorta on the left. The **Nerves** are derived from the solar and renal plexuses, and from the phrenic and pneumogastric nerves; the branches of the plexus are very large, and have numerous ganglia developed on them. The **function** of these bodies is ill-understood—or rather, not understood at all. They are supposed to have some connection with ADDISON'S disease, as in about half the cases the capsules are tubercular, with caseated masses in their interior; this disease is accompanied by a bronzed tint of the skin, especially on the exposed parts, or parts naturally pigmented, vomiting, progressive emaciation, extreme debility, and profound anæmia. The symptoms are probably due to implication of the solar plexus. Sarcoma of the supra-renal capsules may simulate ADDISON'S disease. Their usual **size** is from one to two inches in length, rather less in width, and from two to three lines in thickness. Their **weight**, from one to two drachms.

OPERATIONS PERFORMED ON THE KIDNEY.

Diagnostic Incisions.—A diagnostic incision is one that is used, in cases of doubt, to clear up the diagnosis, and also, if necessary, for treatment as well. Various forms are used—(1) Professor CHIENE always uses a vertical incision, as for colotomy, only well up into the angle between the last rib and the erector spinæ; by this incision the anatomical guides are more definite—first the edge of the erector spinæ, and then the edge of the quadratus lumborum. Should the kidney require removal, the space may be increased by a more or less transverse cut at the upper end of the vertical incision. (2) Another way is to make the oblique cut first, and then, if necessary, add the vertical. An incision is made from below the free end of the last rib backwards to the edge of the erector spinæ; the posterior end of this incision must be at least three-quarters of an inch below the rib, lest the pleura be wounded. Then, should the kidney require excision, a vertical incision is made downwards, along the outer border of the quadratus lumborum.

Tapping the Kidney.—This operation is performed for (*a*) hydro-nephrosis, (*b*) pyonephrosis, and (*c*) large isolated cysts, whether serous, bloody, or from hydatids, when there is danger of the cyst wall giving way, or the pressure symptoms are serious.

Seat of Puncture.—Over a fluctuating point, if there is one; if not, then on the **left side**, about an inch in front of the last intercostal space (see Fig. 179, 5); on the **right side**, midway between the last rib and the iliac crest, about two inches and a half behind the anterior superior iliac spine (see Fig. 179, 6). The puncture is made in this position on the right side, to avoid the liver.

Risks of the Operation.—(*a*) Effusion of the contents into the peritoneal cavity—the peritoneum is usually adherent and prevents this accident; (*b*) puncture of gut; (*c*) puncture of some of the large abdominal vessels; (*d*) puncture of the liver; and (*e*) puncture of the pleura, if too near the last rib.

Nephrotomy.—By this is meant an incision into the kidney for purposes other than the removal of a calculus. It is used for—(*a*) Hydro-nephrosis, when the cyst refills quickly, after repeated

tappings. In cases of this nature, Dr DUNCAN recommends the injection of iodine into the cyst, after evacuation of its contents, before resorting to nephrotomy; the only disadvantage of this plan is the severe pain to which it gives rise. (*b*) In cases of hydatid cysts where it is impossible to empty the cyst thoroughly; (*c*) pyonephrosis; and (*d*) for calculus, or tubercular abscess. The incision resembles that for lumbar colotomy, only being a little nearer the median line and higher up (Fig. 179, 1). The incision Mr MORRIS recommends is slightly oblique, in the ilio-costal space, beginning over the outer edge of the erector spinæ and continued forwards for three inches and a half. The kidney is then exposed, the cyst opened and the contents evacuated, the edges stitched to the sides of the incision, and a drainage tube inserted—the intention being to make the wound heal from the bottom upwards. In cutting down upon the right kidney the operator may first reach the liver: it forms at this point a narrow resisting edge, with a shallow groove between it and the kidney. Dr SYMINGTON first pointed out to me that this was the case, especially if the stomach was at all distended, and I was able to confirm this observation when operating upon the dead body. Of course, to actually expose the liver the peritoneal cavity must be opened, an accident that must be carefully avoided.

Nepbro-Lithotomy.—This operation was first performed by Mr HENRY MORRIS in the year 1880. It is an incision into the secreting tissue, or the pelvis of the kidney, for the express purpose of removing a calculus. The cases in which he recommends this operation are, when the symptoms of renal calculus are not influenced by medicinal treatment and interfere with the comfort and usefulness of the patient's life. Where there is almost constant pain in one loin, passing along the ureter probably to the testicle of the same side; where there are recurring attacks of renal colic, with blood, pus, or albumen in the urine, probably with the passage of gravel per urethram. An incision four inches and a half long is made parallel with the last rib, and three-quarters of an inch below it (Fig. 179, 1). When the kidney is exposed, then feel its posterior surface with the finger for the presence of hardness or irregularity; and if this fail to detect a stone then pass a fine needle into the secreting substance. In

removing a stone it is better to cut into the secreting substance, as there is less risk of urinary fistula than when the incision is made into the pelvis. A drainage tube is then introduced and the wound stitched up, dressings applied, and a pad of German peat moss placed below to absorb the urine. The dangers are hæmorrhage from the divided renal substance, cellulitis, renal abscess, renal fistula, and lumbar hernia. As regards palliative and preventive treatment, the patient should avoid excess of animal diet, and live chiefly on milk, use alkaline drinks to dissolve the stone, especially salts of the alkalies (potassium and lithium) with the organic acids, or the waters of Vichy or Ems.

Composition of Renal Calculi.—In infancy the nucleus is urate of ammonium, recognised by its fawn colour; in childhood, other urates; in the young adult it is uric or oxalic acid; and after forty years of age it is oxalic acid or phosphates.

Nephrorraphy.—This operation consists in cutting down upon and exposing the kidney, and stitching it to the edges of the wound. It is employed for floating, movable, or wandering kidney, which is the seat of frequent severe and spasmodic attacks of pain, or continuous suffering. An incision is used similar to that for nephrotomy. A **floating kidney** is one that has a meso-nephron and for this reason is able to move about; a **movable kidney** is one that moves about behind the peritoneum, but which has not a meso-nephron.

Nephrectomy is the complete removal of a kidney from the living body. It is used for the removal of a diseased kidney in which all less radical measures have failed; in some cases where nephro-lithotomy is not practicable; in ureteral urinary fistula; in badly wounded or ruptured kidney; tumours, *small and medium sized*, of various kinds; and sometimes in wandering kidney. It was first performed by SIMON, of Heidelberg, who laid down the law that it is only to be done when the patient's life is in danger and all other means have failed. It may be performed through a lumbar incision; the advantages of this form of incision are (1) the peritoneum is not opened, and (2) the wound drains well. An incision is made four and a half inches in length, slightly oblique, at least half-an-inch below the last rib, lest the pleura be wounded (Fig. 179, 1). Except that it is on a higher level, the

incision resembles that for colotomy. When the kidney is reached a second incision is made by dividing the tissues from within outwards by a probe-pointed bistoury; this second cut is vertical, along the outer border of the quadratus lumborum, and joins the previous incision about an inch from its posterior end. By means of the second incision the pedicle is ligatured more easily; in cases where the space is small, some Surgeons advise excision of a part of the last rib, although Mr MORRIS strongly condemns this practice, preferring, if more room be required during ligature of the pedicle, to drag the lower ribs forcibly upwards, with the fingers of the left hand dipped into the wound. In the pedicle the vessels and the ureter are usually ligatured separately; the ligature is passed by means of an aneurism needle. If the vessels are ligatured separately the *artery* must be ligatured before the vein. The lower ribs are then pulled upwards and the kidney dragged into the wound, another ligature applied to the pedicle, which is then divided and the kidney removed; in many cases it will be advisable to incise the capsule and enucleate the kidney, leaving the capsule behind with the pedicle—especially in cases where there has been much peri-renal inflammation. All bleeding vessels are then tied, the sutures cut off short and dropped into the wound; a tube, like that used in lithotomy, *i.e.*, without lateral perforations, is then inserted and the wound closed. This tube is to carry off the urine alone; if the wound requires drainage a separate tube must be used, as the urine is not to be allowed to flow over the surfaces of the wound. If the wound is in the substance of the kidney, the tube is left in two or three days; if in the pelvis, it must be left in a week or ten days. The dangers of this operation are—tearing open the peritoneum or colon, injury to the vessels from too great strain, giving rise to hæmorrhage later, uræmia, hæmorrhage from the broken up kidney-substance, and shock.

The Abdominal Incision.—This form is used in the case of large tumours, and for the excision of wandering kidney. An incision is made, opposite the kidney to be removed, in the corresponding lineæ semilunaris, its length varying with the size of the tumour to be removed. This incision is the more fatal of the two, and for this reason the other is to be used where possible. Its chief

dangers are—Septic peritonitis, pulmonary embolism, and pyæmia. An advantage of the abdominal method is that both kidneys can be examined, especially if the incision be made in the linea alba, so that there is less risk of removing the healthy kidney and leaving the diseased one. Of course a median laparotomy might be performed, the kidneys examined, and then the diseased one removed by the lumbar operation.

PARACENTESIS ABDOMINIS.

A small incision is made with a scalpel in the middle line, a little below the umbilicus (about two inches), and through this opening the trocar is thrust; if the aspirator is used, a preliminary incision is unnecessary. It is better, however, to keep up pressure on the abdomen as the fluid escapes, lest the abdominal vessels burst on account of being thus suddenly relieved from the pressure of the fluid.

The instruments required are—Scalpel, trocar or aspirator, split sheet, sponges, needle and silk sutures, scissors, wool and collodion, bucket, adhesive plaster, brandy, etc. Pressure is best kept up by means of a broad flannel roller, split at each end to within six inches of the middle, and applied in such a way that the untorn part covers the front of the abdomen, while the ends are crossed behind and given to an assistant on each side to keep up the pressure as the fluid escapes. A small hole must be made in the anterior part of the flannel roller through which to introduce the trocar or aspirator. The Surgeon must be ready to close the cannula with his finger should the flow threaten to become intermittent, lest air be admitted. Another precaution is to make sure that the bladder is empty before the operation. In tapping the abdomen in other situations, the course of the epigastric vessels must be kept in mind. The possible dangers of the operation are fatal syncope, peritonitis, especially in cases of BRIGHI'S disease, hæmorrhage, wound of the bladder, wound of the bowel from not selecting a dull area, or from plunging the instrument too deeply.

SOUTHEY uses a small "drainage-trocar," which is left in till the distension is relieved. The fluid is drawn off *slowly*, and this avoids the risk of syncope, and the necessity of bandaging. It has no tendency to set up peritonitis, and is almost painless.

Ovarian Dropsy and Ascites in the Female:—

Ovarian Dropsy.

1. The tumour gradually develops from one iliac fossa, and is in front of the intestines, and is attached by pedicle to pelvis.
2. Tumour is more or less central in position and ovoid, and causes the centre of the abdomen to project when the patient lies on her back, or may be more at one side than the other.
3. On percussion, the dullness is round about the umbilicus, the intestines giving a clear note at the sides. The upper limit is convex.
4. The fluid is confined in a cyst, and, therefore, change of position does not alter the shape of the dullness, though the whole cyst may fall to one side.
5. Swelling of the feet and ankles only occurs in the last stages.
6. No particular change in the veins of the abdominal wall.
7. Fluctuation, or fluctuation wave, often indistinct, and if the cyst be multilocular is unequal at different parts.
8. No bulging into the posterior wall of the vagina, in uncomplicated cases.

Ascites.

1. There is no history of lateral development, and the intestines float up upon the fluid.
2. The bulging is at the flanks when the patient lies on her back, and the front of the abdomen is flattened, but when well marked may be of a uniform globular outline.
3. The dullness is at the flanks, as the fluid gravitates there; the centre is clear as the intestines are floated up. The upper limit is concave in the erect posture.
4. The fluid is free, and change of position alters the line of dullness, as it gravitates to the lowest part.
5. Swelling of the feet and ankles an early symptom.
6. The veins are very well marked, and fill most quickly from below upwards, as the pressure of the free fluid presses on the inferior vena cava.
7. Fluctuation, or fluctuation wave, well marked, always, equally, and in every direction.
8. Bulging into the posterior wall of the vagina, from the pressure of the fluid in DOUGLAS'S pouch.

Note the difference between "Fluctuation" and "Fluctuation Wave." In **Fluctuation**, when the *balls* of the fingers of one hand are placed gently and firmly on one side of the fluid swelling, and the other hand presses the opposite side of the tumour gently, the tumour is felt to rise *under the fingers of the first hand*. It is not alone the *sinking* of the fingers of the second hand that constitutes

fluctuation, but the raising of the other hand as well. Elasticity is merely the sinking of the fingers of one hand, but without raising the fingers of the other. *Both* hands must be used, and the swelling must be firmly fixed, so that it cannot move *en masse*. **Fluctuation Wave** can only be obtained where there is a fairly large collection of fluid, as in ascites and large unilocular ovarian cysts. The *palm* of one hand is placed flatly over one side of the abdomen, while the opposite side is tapped sharply with the fingers of the other, when a distinct wave will be found to strike the palm of the first hand. It is necessary, however, to exclude the vibrations of the abdominal walls, which is done by placing a book in the front of the abdomen, or by getting an assistant to place the edge of one hand gently on the centre of the abdomen. This will check the vibrations of the abdominal wall, just as a violinist checks the vibration of the strings of his fiddle at any given point, but will not stop the fluid wave.

It is also necessary to diagnose ascites from **colloid cancer** of the peritoneum. In this case there is great enlargement and dullness over the whole of the abdomen, but an absence of fluctuation. It must also be diagnosed from distended bladder, large elastic tumours, renal cysts, and from a pregnant uterus. It is often very difficult to diagnose an ovarian cyst from an encysted dropsy of the peritoneum. In encysted dropsy, however, the tumour is more likely to occupy a central position, and the umbilicus is usually markedly everted.

Nature of Different Fluids.—Parovarian fluid.—The parovarium, or organ of ROSENMÜLLER, corresponds to the epididymis in the male. The fluid is clear, transparent, and limpid, and consists of nothing but water and salts. It is slightly opalescent, and the specific gravity is about 1005; it is not coagulated by heat or nitric acid, and therefore does not contain albumen.

Hydatid fluid closely resembles parovarian fluid, but it contains hooklets. It is watery and limpid, of specific gravity 1008 to 1013; it contains no albumen; there is a certain quantity of extractives and salts, especially chloride of sodium; and, floating in the fluid, are a number of hooklets and scolices or echinococci heads.

Ovarian fluid is very often markedly viscid, of a dark greenish-brown colour, and may be so thick as almost to be gelatinous,

often containing scales of cholesterine. The specific gravity varies from 1010 to 1040, or even more. The viscosity is said to be due to the paralbumen of SCHERER; this substance differs from ordinary albumen, in that it does not coagulate when boiled with a small quantity of acetic acid. It is stated that this form of albumen is never present in ascitic fluid. Ascitic fluid, on the other hand, often deposits fibrin, but fibrin is not a constituent of ovarian fluid. Should a fluid, therefore, contain paralbumen and deposit fibrin, it is probably due to an ovarian cyst bursting into the peritoneal cavity. In some cases it is impossible to distinguish between ovarian and ascitic fluid. It is stated that special cells are found in ovarian fluid. The cell is about the size of a pus cell, generally round, delicate and transparent, full of granules, but has no nucleus. Acetic acid increases the transparency of the cell and makes its granules more evident. In cases of malignant disease, large pear-shaped, round or oval cells are found. These cells contain granular material, with one or several large clear nuclei, with nucleoli and a number of transparent globules or vacuoles.

Ascitic fluid is a yellowish serous liquid, closely resembling slightly diluted liquor sanguinis, from which, indeed, it is directly derived. It is a clear yellow, or greenish-yellow, alkaline fluid, with a specific gravity varying from 1020 to 1035. It consists of water, salts, albumen, and the elements of fibrin, and hence, on standing, may coagulate, depositing fibrin; indeed, in some cases it may be so thick and viscid, from coagulated matter, as to be incapable of flowing through the cannula.

CHAPTER XXXIX.

THE ABDOMEN—(Continued).

HERNIA.

By this term is meant a protrusion of a part of the viscera through some weak point in the abdominal wall; it is generally through some natural canal or opening, either actual or potential, which has become dilated: it may also take place through adventitious apertures, due to the separation of aponeurotic fibres from distension of the abdomen.

A **Hernia** consists of a **sac** (that is the prolongation of the peritoneum which envelops the hernia), **contents**, and **coverings**.

The **coverings** of any hernia consist of skin, fascia, muscles, and fat. Hernia is said to be *inguinal* when it comes through the opening or canal situated in the inguinal region of the groin; and *femoral* when it comes through the opening or canal situated in the femoral region of the groin. The **sac** has its *neck* or narrow part situated in the ring. The **life history** of the *neck* consists of three stages—(1) Its formation, when it is simply a corrugated or folded membrane; (2) its adhesion, where the folds adhere, and it becomes, more or less, a round hole; and (3) its contraction, where the adherent tissue contracts like ordinary fibrous adhesions. In all herniæ there is a swelling in communication with the abdominal cavity, and which has been suddenly or gradually produced; if it has appeared *suddenly* the sac must have been pre-formed, as in the different forms of “congenital” hernia.

Pathological Varieties.—A hernia is said to be **reducible** when *all* the contents can be pushed back into the abdominal cavity. It is called **irreducible** when all the contents cannot be returned without the sac, and yet is neither strangulated nor obstructed; it may be wholly or partially irreducible. An **obstructed hernia**

is where the *contents of the bowel* are checked in their passage at the seat of the hernia—a local constipation; the term **incarcerated hernia** is sometimes applied to the same condition occurring in an *irreducible* hernia. An **inflamed hernia** is one in which the peritoneal envelope, or sac, is inflamed—a local peritonitis. A **strangulated hernia** is one where the venous blood return is checked by some constricting structure; this is followed by swelling, œdema, and then the arterial supply is also checked, and unless relieved the condition quickly passes on to gangrene of the bowel; in addition to this, it is also irreducible and obstructed. Congenital herniæ are most liable to strangulation.

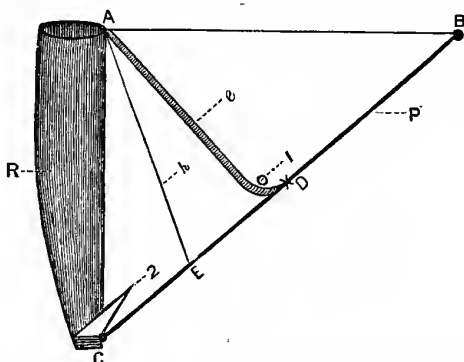
INGUINAL HERNIA.

This form is much more common in males, because in them the inguinal canal is larger, while the crural ring is smaller, than in females, on account of the less expanded iliac crests. The space concerned in inguinal hernia is triangular, corresponding to the inguinal region of the groin, and has the following boundaries—**Below**, by **POUPART'S** ligament; **internally**, by the linea alba; and **above**, by a line drawn from the anterior superior iliac spine to the linea alba. In connection with the subject of hernia, it will be well to consider the structure of the abdominal wall at this point; the two longitudinal muscles (the rectus and pyramidalis) may be left out of account for the time being. If we were to examine the triangular space, mentioned above, from the inside of the abdomen, we would find that it is subdivided into two triangular parts by the deep epigastric artery (Fig. 186, e)—the artery, in fact, almost bisecting the triangle in question—an outer triangular part, and an inner triangular part known as **HELSELBACH'S** triangle (Fig. 186, C, A, D). In dissecting the abdominal wall in the region of the outer triangular part, we find—(1) Skin; (2) superficial fascia; (3) tendon of the external oblique; (4) the internal oblique; (5) the transversalis muscle; (6) fascia transversalis; (7) extra-peritoneal fat; and (8) the peritoneum. In the inner triangular space (that is, **HELSELBACH'S** triangle) the structures met with are similar, except that the tendons of the internal oblique and transversalis muscles are inseparably united, forming the “conjoined tendon,” which is attached to the crest of the pubes

and the pectineal line, and which, therefore, takes the place of the above muscles in this space. The conjoined tendon, however, does not entirely cover in the whole of HESSELBACH'S triangle. The obliterated hypogastric artery (Fig. 186, *h*) passes across the triangle in question, internal to and almost parallel with the deep epigastric artery, and the space between these two structures is not covered by the conjoined tendon. For this reason, we shall see later that there may be *two* forms of **direct Inguinal Hernia**.

Fig. 186.

SPACE CONCERNED IN INGUINAL HERNIA, FROM THE INSIDE.



B. Anterior Superior Spine.
 C. Crest of Pubes.
 D. Centre of Poupart's Ligament.
 P. Poupart's Ligament.
 R. Rectus Abdominis.
e. Deep Epigastric.
h. Obliterated Hypogastric.

1. Internal Abdominal Ring.
 2. External Abdominal "Ring."
 C. A. D. Hesselbach's Triangle.
 C. A. E. Part covered by the
 "Conjoined Tendon."
 E. A. D. Part not covered by
 that Tendon.

The Inguinal Canal.—This is an oblique opening through the anterior abdominal wall, and is directed downwards and inwards, lying parallel with and a little above the inner half of POUPART'S ligament. It commences at the internal abdominal ring, and ends at the external ring, and is about an inch and a half to two inches in length. The **external abdominal ring** is oval or triangular in shape, directed upwards and outwards; the base is formed by the crest of the pubis, and the lateral boundaries are known as the

pillars of the ring (Fig. 186, 2). The upper, or *internal*, pillar or column consists of a flattened part of the tendon of the external oblique, passing downwards to be fixed to the front of the symphysis pubis; the lower, or *external*, pillar is chiefly formed by the inner end of POUPART'S ligament, and is thicker and more rounded than the other pillar, and is attached to the spine of the pubes. At the upper part of the ring there are some fibres seen passing in a transverse direction, and these are called the *inter-columnar fibres*. POUPART'S ligament is attached internally to the spine of the pubes, and also into the pectineal line forming GIMBERNAT'S ligament, and is to be regarded as part of the insertion of the external oblique; a part, however, of its tendon of insertion, springing from the pectineal line and pubic crest, passes behind the internal pillar of the ring, and decussates in the linea alba with the tendon of the opposite side, forming the "triangular fascia." The ring transmits the spermatic cord in the male and the round ligament in the female. The **internal ring** is an opening in the fascia transversalis, and is situated about half an inch above the middle of POUPART'S ligament (a point midway between the symphysis pubis and the anterior superior iliac spine.—CUNNINGHAM.) (Fig. 186, 1).

Boundaries of the Canal.—In **Front**—(1) The external oblique (throughout its whole length); (2) the internal oblique (for its outer third); (3) the cremaster muscle. **Behind**—(1) The fascia transversalis (throughout its whole length); (2) the conjoined tendon (for its inner third); (3) the triangular fascia; and (4) the deep-epigastric artery. The **floor** is formed by POUPART'S ligament, and the **roof** by the free arched lower border of the transversalis muscle.

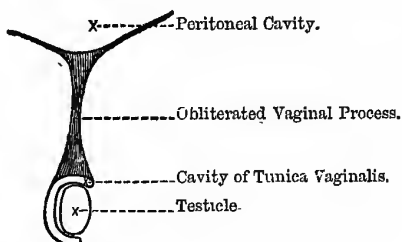
The Descent of the Testicles.—The testicles are originally situated in the abdominal cavity, below the kidneys and behind the peritoneum; but before birth they pass down into the scrotum. Up to about the end of the sixth month of foetal life they are found below the kidney, at the posterior part of the abdominal wall; but as the process of development becomes more and more complete, they gradually descend, so that, by the seventh month, they are situated behind the internal abdominal ring. During the eighth month they pass through the canal, and by the end of the

ninth month they have reached the bottom of the scrotum. The means by which this descent is effected is rather obscure, and was formerly believed to be due to the contraction of certain muscular bands—the “gubernaculum testis”—which piloted the testicles into their proper haven, but is now commonly believed to be the result of a general process of development. In some mammals—*e. g.*, the elephant—the testes remain permanently within the abdomen, and in the rodentia they only descend at each “rutting” season. Sometimes the testicles in the human subject are retained in the abdomen, and then they are very frequently imperfectly developed; this condition is known as *cryptorchismus*. A process of peritoneum—the *processus vaginalis*—passes down into the scrotum, and precedes the testicle by some time in its descent; and as the testicle originally lies behind the peritoneum, and still retains this position in its descent, both layers of this pouch of peritoneum necessarily lie in front of the testicle. But, as the testicle passes down it receives certain coverings from the layers of muscle and fascia forming the anterior abdominal wall: thus it receives—(1) The *inter-columnar* or *external spermatic fascia* (sometimes called the “fascia propria” of CAMPER) from the external oblique, as it passes between the pillars of the ring; (2) the *cremasteric muscle* or *fascia*, continuous with the internal oblique; (3) the *infundibuliform* or funnel-shaped fascia, from the fascia transversalis (also called the *internal spermatic fascia*). The transversalis muscle gives no covering to it, as the free arched border of the muscle is too high, the testicle passing through below it. All these coverings are continued over the testicle as it lies in the scrotum. The pouch of peritoneum, preceding the testicle, at first communicates with the peritoneal cavity; but a little time before birth its narrow neck becomes closed, while the unobliterated lower end forms the tunica vaginalis, which is in this way entirely shut off from the abdominal cavity (Fig. 187). This complete obliteration of the tunica vaginalis is peculiar to the human species, probably on account of the erect attitude. In the female foetus an analogous pouch of peritoneum descends for a short distance along the round ligament of the uterus, and is known as the *canal* of NUCK. Occasionally the ovaries are prolapsed into this canal, being an attempt, apparently, to imitate

the "descent of the testicles" in the male subject. We have described the descent of the testicle at this point, because one form of inguinal hernia takes exactly the same course, and receives similar coverings. In some cases the **descent is incomplete**, or the testicle is **misplaced**. It must first be sought for in the inguinal canal, then in the iliac fossa close to **POUPART'S** ligament, and, lastly, in the perinæum or crural canal. A misplaced testicle is more apt to become inflamed, or the seat of malignant disease, than a testicle in its proper place.

Fig. 187.

NORMAL CONDITION OF THE PROCESSUS VAGINALIS IN THE ADULT.



DIRECT AND OBLIQUE INGUINAL HERNIA.

The Oblique.—This form is named oblique, or indirect, from the direction it takes, passing through the oblique inguinal canal; it is also called *external* from its relation to the deep epigastric artery, which lies to its inner side. It is most common in young males. It takes the same course as the testicle did—that is, it enters at the internal abdominal ring, passes through the whole length of the canal, and escapes by the external ring into the scrotum; it passes through that part of the triangular space concerned in inguinal hernia that lies to the outer side of the epigastric artery, and whose structure has already been described (see Fig. 186). The hernia usually passes down in front of the cord, between the cord and its coverings; its neck lies above **POUPART'S** ligament, and internal to the spine of the pubes. The spine of the pubes and the external abdominal "ring" can be best felt in the male by invaginating the scrotum with the point of the finger and then passing it up in front of the cord. The

oblique variety of inguinal hernia often attains a large size, as, when once begun, there is but little resistance to its growth. The **coverings** of this form of hernia are—(1) The skin; (2) superficial fascia; (3) inter-columnar fascia; (4) cremasteric fascia or muscle; (5) infundibuliform fascia; (6) the extra-peritoneal fat; and (7) the peritoneal sac. The "**fascia propria**" of the hernia is the united extra-peritoneal fat and the fascia transversalis, and immediately invests the sac. The sac, as here seen from the outside, may be recognised by its *rough* and *bluish* appearance; it is *not* smooth and glistening.

Direct Hernia.—It is called direct, from the direction it takes; it is also called internal, from its relation to the deep epigastric artery, which lies to its outer side. This form does not pass through the whole length of the inguinal canal, but escapes from the abdomen through that part of the triangular space concerned in inguinal hernia, known as HESSELBACH'S triangle (the boundaries of which, and a description of the structures forming the abdominal wall at that point, have already—see Fig. 186—been described), enters the inguinal canal, pushing the conjoined tendon before it (unless, as is sometimes the case, the conjoined tendon is small, and does not fill up all the triangle in question), passes through the lower part of the canal, and escapes by the external abdominal ring. The testicle is placed behind the hernia. It is probably oftenest met with in elderly men, and rarely attains a large size, but usually forms a small globular tumour, just above the crest of the pubes, as the resistance to its growth is considerable. The **coverings** in this form of hernia are almost the same as in the oblique form; the only difference being that, instead of reading "cremasteric fascia or muscle," as in the oblique variety, read "conjoined tendon." This tendon, as we have said, is the tendon of the conjoined internal oblique and the transversalis muscles; but, as the transversalis muscle gives no covering to any form of inguinal hernia, it may simply be read in place of the cremasteric muscle, which is continuous with the internal oblique: in other respects the coverings of the two forms are exactly the same.

But as already indicated there are two forms of direct Hernia. The obliterated hypogastric artery passes across HESSELBACH'S triangle, dividing it into two parts (see Fig. 186, *h*)—(a) In the

most common form of direct hernia, the gut leaves the abdomen *internal* to the obliterated hypogastric artery, and therefore passes through the conjoined tendon. (*b*) In the **second**, the hernia passes between the obliterated hypogastric artery and the deep epigastric (see Fig. 186), but altogether external to the former structure, and therefore has no covering from the conjoined tendon, the coverings in this case being practically the same as in the ordinary oblique form. On the inner surface of the abdominal wall in this situation certain ridges are found—in the middle line is the *urachus*, and then on each side of this we find ridges formed by the obliterated hypogastric and the deep epigastric artery. By means of these ridges little peritoneal fossæ are formed, called “digital fossæ,” because they look like indentations caused by the tips of the fingers—one external to the deep epigastric artery, another between that vessel and the obliterated hypogastric, and a third internal to this latter structure. These fossæ indicate a *local weakness* in the abdominal wall, and this, combined with some exciting cause, explains the frequency of hernia in these situations. Were the walls of the abdominal cavity equally strong in all situations there could be no reason why it should occur in one situation more than in another. In practice, it is extremely difficult, and often impossible, to distinguish between the oblique and the direct forms; because in the oblique form the internal abdominal ring is apt to be drawn towards the middle line, more especially if the hernia be of long standing. The diagnosis would not be important were it not for the different relations of the two forms to the deep epigastric artery—the oblique being external and the direct internal to that vessel; and this might have an influence in determining the direction of the incision in the operation for strangulated hernia, it being necessary to cut *from* the artery—or, at least, not to cut towards it. But, from the difficulty in diagnosis above indicated, the best rule is, in *every* case, to cut upwards and slightly inwards, parallel with the deep epigastric artery; by this means the artery escapes injury. When recent and of small size, it may be possible to distinguish between the oblique and the direct forms by reducing the hernia and then asking the patient to cough, when, in the **oblique** form, the protrusion of the gut will be felt at the internal abdominal ring, and in the **direct** immediately

behind the external abdominal ring. It may be possible also, at first, to observe the oblique neck of the tumour in the one case, but not in the other. The great causes of hernia in old men are chronic constipation, bronchitis, and dysuria. The deep epigastric artery in the normal condition, as we have already stated, almost bisects the triangular space concerned in inguinal hernia—passing from near the middle of the base (POUPART'S ligament) to its apex, which is formed by the meeting of the horizontal line with the linea alba (see Fig. 186).

The Seat of Strangulation may either be—(1) Due to the neck of the sac becoming thickened and constricted by plastic deposit, and its subsequent organisation and contraction—this is the most common cause; (2) by the inter-columnar fascia; or (3) by the transversalis fascia; (4) by the ravelling of the contents among each other—*e.g.*, a kink of bowel through a hole in the omentum; (5) during some strain, a fresh loop may pass into the neck of an already full sac, or past a partially descended testicle; and (6) occasionally by the body of the sac.

STRANGULATION.

Operation for Strangulated Inguinal Hernia.—The operation for the relief of this condition in hernia of any kind is often called **Kelotomy** or **Herniotomy**. The objects of the operation, as in all cases of a similar nature, are—(1) To divide the constricting structure, and (2) to perform the radical cure at the same time—*viz.*, to tie the neck of the sac flush with the interior of the abdomen, and mat the rest of it together by several catgut sutures, or else cut it off altogether, and then bring the walls of the canal together by catgut sutures, leaving enough room below the lowest suture for the passage of the spermatic cord. In all cases of hernia, the usual rule is, **when in doubt, operate**, and never let the patient vomit three times before operating. Of course, one must never operate, against the patient's will, for this condition or any other; as otherwise, should the patient recover, he or she may bring an action for assault against the Surgeon, and claim heavy damages. Such is the ingratitude of human nature! There are two forms of operation—(a) The **extra-peritoneal**, where the sac of the hernia is not opened, the constricting cause being divided outside the neck.

and the bowel afterwards reduced. This form, as a rule, is to be avoided, for the usual constricting cause is the thickened and contracted neck of the sac itself; and besides, the contents might be ravelled amongst each other, or the bowel gangrenous. It may be used in cases where the symptoms of strangulation are not very marked, and where the hernia has only been down for say less than thirty hours. Where the state of the bowel is doubtful, where there has been much vomiting, and where the parts are tender on pressure, the sac should be opened. (b) The peritoneal method, where the sac is opened. This is the best method, and no bad results are likely to follow the opening of the sac, with the present improved methods of operating and treating wounds; and, further, the true condition of the hernia can be thus readily seen, and the contents examined. In the former method, a feeling of doubt and insecurity must always exist as to the condition of the hernia. The instruments required are—A sharp scalpel, a probe-pointed bistoury, dissecting forceps, directors straight and curved, SPENCE'S hernia director (Fig. 188), a hernia knife (Fig. 189), catch forceps, retractors, scissors, ligatures and needles, silver wire, razor, sponges, chloroform, a half grain morphia suppository, antiseptic dressings, etc. The patient's bladder is to be emptied, and the parts must be previously shaved and soaked with some antiseptic solution. He is laid on his back, with his shoulders somewhat raised, and the knee of the affected side slightly bent over a pillow; no more of his body should be uncovered than is absolutely necessary. The spray being turned on, an incision of sufficient length is made over the neck of the sac, obliquely downwards and inwards, the centre of the incision corresponding to the external abdominal ring. To make the incision, the skin is pinched up at right angles to the line of incision, at each side of the proposed site, between the fingers and thumbs of an assistant, or the Surgeon may take one side, and the assistant the other; the Surgeon then transfixes this fold, the back of the knife being towards the hernia, the knife being then made to cut its way out. When the parts recover their normal position, a linear incision is left, and the divided superficial external pudic seen and secured at once by a pair of forceps. The dissection is then carried carefully down through the various layers of tissue, all

bleeding vessels being at once tied or twisted. As the Surgeon approaches the sac, the different layers must, in all cases of doubt,

Fig. 188.

SPENCE'S HERNIA DIRECTOR.



Fig. 189.

HERNIA KNIFE.



Knife used to divide the Constriction.
Observe the Cutting Part.

be opened in the same way as the sheath of an artery is opened ;
SPENCE'S hernia director is then slipped in, and the layer slit open

by a probe-pointed bistoury. The sac is known by its rounded tense appearance, filamentous character, and by the arborescent arrangement of vessels on its surface; it is bluish in appearance, and it may be possible to see fluid and the intestines through it. It may be difficult to distinguish the fascia propria from the sac, but in all cases of doubt, open *as if it were* the sac. The gut wall is smooth and polished, probably congested, but has no arborescent vascular network; but should the sac be opened inadvertently, as a rule, a sudden jet of fluid will escape, and the doughy, granular omentum protrude.

To distinguish the **fascia propria from the sac**—The fascia propria is prolonged indefinitely upwards on the swelling, *being continuous with the margins* of the aperture through which the hernia protrudes; whereas, when the sac is fairly exposed, the sharp defined margins of the aperture can readily be felt. The greatest difficulty is most likely to be met with in femoral hernia. When the fascia propria is not divided, the tip of the finger cannot be made to enter the abdomen; when it is divided, the nail can be inserted under the sharp margin of the ring.

The sac in femoral and in all small herniæ should be opened at its *lower part*, because in this position there is usually some fluid which protects the bowel from injury; in large herniæ the *neck* of the sac must be opened. If the sac is not very tense, take it between the finger and thumb and displace the contents, and then pinch a small part up by the forceps, and divide it with the edge of the scalpel, held horizontally; a director is then introduced, and the opening enlarged by a probe-pointed bistoury, and then each side of the opened sac seized by a pair of WELLS'S forceps. If the fluid is clear and transparent, or slightly yellowish, like serum, and communicates *no bad odour* to the finger, the prognosis is good, as it indicates that the inflammation has not been of very long standing or severe; the gut will probably be found deep red and *glistening*. Some hours later the fluid is dark-brown in colour, the gut purple, but still glistening. Still later the fluid resembles a strong infusion of coffee, the gut is purple or black, and the *glisten lost*; it has a sodden appearance, like wet parchment, or is ash-grey in colour. When the fluid has a very bad odour, it probably indicates gangrene, and the prognosis is bad; should

bubbles of gas escape, it indicates perforation or putrefaction. In dividing the constriction, the director may be used to divide the tight margin, but for the deeper parts of the stricture the finger is the best and safest director; it is passed up into the sac (the left index finger) and the nail slipped under the tight edge of the constricting band; the hernia knife is then passed along its palmar surface, lying flat upon it, till it is passed through the constriction, and has the cutting edge opposite that point. The blade is then turned for about a quarter of a circle, with its edge pointing in the proper direction, and the sharp edge of the constriction is in this way notched, and the finger is then passed into the abdomen to feel that all is clear. The contents must now be examined. The gut is pulled down a little way, and the part where the compression was applied, and the gut immediately above it, carefully examined; it may either be at once returned or left in the wound. After reducing the gut, put the finger up the canal, to make sure that the gut is *in the abdominal cavity*. The *colour* is of little consequence, provided the natural gloss of the gut is not lost, and as long as this glisten remains the gut may be put back into the abdomen; if in doubt, relieve the constriction, and let the gut lie in the wound. If it has an ashy-grey, softened look, and the glistening appearance gone, then it must not be put back, but must be left in the wound; and in doubtful cases return it just within the ring, keeping the doubtful part opposite the wound, and leave the wound open.

Recent adhesions may be torn through, old ones ligatured, if necessary, and cut.

The Omentum may be either returned, or left in the sac, to plug up the orifice, or ligatured, and a part cut off, according to its condition and size. The neck of the sac is then to be separated well up into the internal ring, and tied flush with the interior of the abdomen, and the walls of the canal drawn together by catgut sutures. The wound is then closed, and a catgut drain or small tube introduced at its lower angle, and a good broad antiseptic dressing applied, with plenty of wool, and the whole steadied by a domett spica. The patient is then put to bed and kept warm, and a dose of opium administered, either by the mouth, hypodermically, or per rectum (one-half grain morphia suppository).

For thirst and vomiting, give him ice to suck: the food must consist of milk, arrowroot, and beef-tea. He must not be purged, but the bowels left to act of themselves; or at the most a castor oil and gruel enema given; even though many days pass one must not be anxious. When the bowels have acted spontaneously, then the patient may be regarded as convalescent.

Accidents of the operation are—Wound of the gut, or wound of some of the vessels near the openings. The operation is sometimes followed by peritonitis.

Reduction en masse or en bloc.—By this is meant the return of the hernia, sac and all, bodily behind the abdominal parietes, within the internal ring, still in a state of strangulation, or, in any case, the external protrusion made to disappear somewhere, whether *into* the abdomen or not. Properly speaking, it is said to be pushed into the extra-peritoneal tissue, or between the fascia transversalis and the muscles. But it probably also includes other conditions, as cases where the bowel bursts through a hole in the neck of the sac, but the hernia is still strangulated by the mouth of the sac. MR BRYANT says it can only occur in a femoral hernia.

Reduction en bissac.—In some cases an intra-parietal sac exists as a diverticulum from the ordinary sac, and the hernia is displaced into it instead of into the abdomen; this only occurs in congenital forms of hernia.

After the gut has been apparently reduced, the **Symptoms of Strangulation** may still persist. **Causes**—(1) It may have been reduced *en masse*, but in this case there will have been no gurgle on reduction, the canal is open, and neither sac nor tumour to be felt. (2) A strangulation may have existed within the sac while taxis only overcame the external strangulating cause—*e.g.*, a kink of bowel through a hole in the omentum. (3) The nipped segment of gut remains in a state of paralysis from acute inflammation—“laming of the bowel.” (4) Reduction *en bissac*, or the sac may have been hour-glass-shaped, one part in and the other outside the abdomen, and the gut is simply displaced from the one to the other. (5) A second strangulated hernia may exist at some other aperture. (6) The gut may have ruptured and set up acute peritonitis; or (7) acute peritonitis may have been set up without rupture of the sac. (8) Other forms of displaced hernia—(a) Where

the neck of the sac is detached from the internal ring, and the hernia thus pushed up beneath the abdominal wall, the gut being still strangulated by the narrow mouth of the sac; and (b) where the sac and the gut escape into the subserous fatty tissue, but still strangulated. Two courses are open to the Surgeon—either to cut down upon the canal, and see what has gone wrong, or else perform laparotomy, having made sure of the absence of a second hernia and peritonitis. It is probably better to open the canal in the inguinal region, as the Surgeon can then perform the radical cure, as well as relieve existing constrictions and adhesions.

In cases of reduction *en bloc*, the late Professor SPENCE taught that if the hernia could be brought down again by coughing, it could not be an example of that condition. Mr BRYANT states that of the four forms of displaced hernia—(1) reduction *en masse*, (2) detachment of the sac and peritoneum from the internal ring, (3) cases where the sac bursts, and (4) reduction *en bissac*,—the first two may be reduced, forced down again by coughing, and re-reduced frequently. It is most difficult to be quite sure, but absence of the sudden jerk as the hernia is reduced, and the return of the symptoms of strangulation after the effect of the chloroform has passed off, should put the Surgeon on his guard, and will warrant him in cutting down on the hernial canal and exploring. This is better than opening the abdomen, because (1) we can with more certainty and greater ease find the constricted hernia, (2) judge of its fitness for reduction or otherwise, and (3) when actually gangrenous, or doubtful, it can be dealt with more satisfactorily than when the abdomen is opened in the middle line.

The late Professor SPENCE, however, distinguished two varieties of reduction *en bloc* or *en masse*. The true reduction "*en bloc*," where it is reduced completely within the abdominal parietes, and no effort, such as coughing or sneezing, can make it re-appear, because the sac, with its contents, no longer corresponds to the opening or axis of the canal, as it is pressed aside and the body flexed on the neck, altogether out of the line of the canal. The other kind, to which, I think, he rather applied the term reduction "*en masse*," is where the hernia is partially pushed back, with the constriction unrelieved, but where the hernial sac and contents still lie in *the line of the canal*—the fundus still occupying the

upper opening of the canal, and the body still corresponding to its axis. In this case a cough or sneeze may easily cause the hernia to come "down with a bolt *en masse*." This is most apt to happen in small recent femoral, whether reducing by taxis, or by the extra-peritoneal method of operation, unless care be taken to first empty the sac of its contents, and not push both back together. This test of SPENCE'S is also diagnostic in cases where an *internal strangulation* exists, coincident with a reducible hernia; the hernia can easily be made to reappear in this case, and shows that the persistence of the symptoms must be due to something else than the hernia.

Taxis in Inguinal Hernia.—In the operation of taxis—that is, reducing the hernia by manipulation—the parts should be relaxed as much as possible; and for this purpose the shoulders should be raised and the lower extremities flexed at the hip and knee and adducted. By this means the fascia lata, which is attached to POUPART'S ligament, is slackened, and, of course, POUPART'S ligament itself, and in this way also the walls of the canal are relaxed. The bladder should be emptied to increase the capacity of the abdominal cavity, and the patient should be made to keep his mouth open and breathe freely, to relax the diaphragm and lessen intra-abdominal pressure; further, the pelvis should be a little higher than the abdomen, so that the weight of the intestines may help to pull in the protruded gut. The neck of the hernia should be steadied with one hand, while pressure is made in the direction of the canal with the other, with gentle lateral motion, if need be. By gentle compression for a long time the venous and serous contents are emptied out, which will also be aided by raising the sac. Taxis must not be carried out too vigorously or for too long a period, if the constriction does not yield. In children, it is important to remember that the canal is not oblique.

The principal Adjuvants to Taxis are—(1) A large enema, (2) cold, and (3) chloroform. An enema is useful by exciting peristalsis, as well as probably lessening the total contents of the abdomen. Cold must only be used for a short time in *recent* herniæ, but *never* if there is any suspicion of gangrene; it calms and relieves the local irritation and congestion, causes the vessels to contract, and condenses gases, thereby lessening the bulk of the

protruded part. The greatest adjuvant of all, however, is **chloroform**, but before giving it, gain the patient's consent to an operation, if necessary; this will save much valuable time, as otherwise it will be necessary to allow him to recover consciousness.

RADICAL CURE OF HERNIA.

1. A Truss.—Professor CHIENE strongly insists that a properly-fitting and properly-worn truss ought to be a *radical* cure, instead of a *palliative* measure, as it is usually called. If the bowel is prevented from ever again passing down, by pressure of sufficient amount and at the same time properly directed, nature will do the rest. The canal has a natural tendency to contract and close, and it is only the occasional passage of the gut that prevents it, just as the occasional passage of a bougie prevents the closure of a urethral stricture. A properly applied and properly fitting truss *constantly* worn, most nearly approaches Nature's method of cure. The pressure must be applied directly to the canal and the internal abdominal ring, and must be just of sufficient amount to keep up the hernia; if it be too powerful, it will induce atrophy of the walls of the canal. Pressure over the *external ring* merely prevents the hernia passing into the scrotum. All that is wanted is to allow the neck of the sac to close; this is specially the case in children, where the natural tendency to close is very marked. The pressure must not be nipple-shaped, but *flat*, or rather, corresponding to the *curve* of the abdominal wall, so as to keep the walls in contact throughout their whole extent. The pad must be as large as possible, provided it does not press upon the spine of the pubes, for then the hernia would slip out beneath it, nor must it interfere with the flexion of the hip joint, lest the thigh, when flexed, push up the pad. It should be light, firm, and elastic, and well fitted; *ready-made* trusses are an unmixed evil. It must pass round the *bony* pelvis, and yet be out of reach of the effects of contraction of the glutei. It must be worn night and day, or, at night, a properly applied elastic spica, with cotton wool below it, may be used if the truss is uncomfortable, but the truss must be put on *before* the patient gets out of bed in the morning, or even before he assumes the sitting posture; a special gum-elastic truss must be worn when taking a bath. The objection to the *constant* use of

a truss is that the *continuous* pressure causes atrophy of the walls of the canal; some, therefore, advise that it should be taken off during the evening or night, to make the pressure *intermittent*. In almost every case, and certainly always in children, a double-headed truss should be used. Femoral hernia is the worst to manage, as it is very difficult, or almost impossible, to press on the neck of the sac; in these cases an "opposite-sided" truss (SALMON & ODY), or SPENCE'S triangular pad, must be used. In fitting a truss on a *child*, remember that the canal is not oblique, but straight in above the crest of the pubes. If the truss allows the hernia to slip through beneath it, instead of being a safeguard, it is an additional source of danger. Unless the truss fits well and keeps up the hernia, the patient is far safer without it.

Measurements and Directions to be sent to the Instrument Maker in regard to a Truss.—It is better always to send the patient, if possible, both to be measured and to get it "fitted on" afterwards. If this be inconvenient, or impossible, then (1) take the circumference of the body one inch below the iliac crests, or midway between the great trochanter and the anterior superior iliac spine, the tape being carried from the lower lumbar spines, and then sloping down to the symphysis pubis. Instrument makers state that this is sufficient for single or double-headed spiral trusses, and for the double-headed SALMON & ODY truss. For the single-headed spiral truss, however, it is probably also as well to send (2) the distance between the anterior superior spine and the hernial orifice. (3) State whether the hernia is single or double, and if single, whether it is on the right or left side. (4) State the nature of the hernia, whether inguinal or femoral; and give some idea of its size. (5) Take a rigid cast of one or both sides of the pelvis by means of a strip of lead, or a flattened gas-pipe; and if this cast cannot be sent as it is, then take a full-sized outline of it on a sheet of paper and send that. This is of great value, because it shows the shape of the pelvis, whether it is flattened or rounded; and if the cast can be sent it will also show the requisite amount of spiral or bevel to give the spring. (6) Lastly, send a rough sketch, showing the hernial orifices, pubic spine, POUPART'S ligament, and the anterior superior iliac spine, and mark upon it the exact place where the pad should press.

In the single-headed SALMON & ODY ("opposite-sided truss"), in addition to the total circumference of the body, send also the distance between the spines of the vertebræ and the hernial orifice, the tape being carried round the *opposite side* of the pelvis.

The patient should be told (1) that the truss must be worn constantly; (2) that it must always be adjusted while he is in the recumbent position; (3) that he should have a duplicate truss, in case of accident, or for repairs; and (4) that he should have a special bathing truss.

In **infants**, one of the best and most effective of trusses for inguinal hernia is an ordinary skein of worsted, twenty-two inches long, and consisting of twenty threads. The end passing round the side opposite from the hernia is held at the seat of the hernia, while the other end is passed through the loop at this point, is then made to encircle the thigh, from before backwards, upwards, and outwards, and is then fastened to the waist part.

To Test the Truss.—The patient should sit on the edge of a chair, with his legs widely apart, his body bent forwards, and then cough forcibly.

2. **Wood's Operation for Inguinal Hernia (1885).**—Mr WOOD thus describes the operation:—The instruments required are—(1) A tenotomy knife; (2) a semi-circular needle, mounted on a stout handle, flattened at the eye, with a sharp point and blunt shoulders, formed so as to slip along the front of the curved forefinger; with (3) about a foot of tendon, or wire, as thick as stout twine. The patient is laid on his back with his shoulders raised. The scrotum and pubes are shaved and cleaned with carbolic lotion, and all other ordinary antiseptic precautions are taken. The hernia being reduced, a small incision, about three-quarters of an inch long, is made with the tenotomy knife over the cord, and parallel with it, just below the pubic crest. This is carried down to the sac, any bleeding vessel being secured as it is cut. The finger is then passed into the canal, as far as the internal ring, carrying the sac invaginated before it. At the inner side the conjoined tendon can be felt and the finger passed behind it. The needle is then carried along the finger until its point can be felt behind the conjoined tendon, through which it is pushed so as to project beneath the skin. The integuments are then drawn well

over to the inner side and the needle pushed through the skin. The needle is then threaded with the tendon suture, or, if wire be used, a bend at the end of it is hooked on. The needle is then withdrawn at the scrotal wound and the suture detached, leaving about six inches projecting from the puncture in the abdominal wall. The finger is then passed behind *POUPART'S* ligament, the spermatic cord felt for and pushed aside. The point of the finger is then carried close to the ligament, along the groove of the outer pillar of the external ring, to a point opposite the internal ring; the needle is then passed through the aponeurosis of the external oblique, and, by drawing the skin well outwards, is made to appear at the puncture already made. The end of the suture which is projecting from the puncture is then attached to the needle, which is drawn out at the scrotal wound.

There is thus a loop left projecting at the puncture on the abdominal wall, and two free ends from the scrotal wound. The needle is then carried from the scrotal wound across, behind the sac, between it and the cord, the latter being isolated and drawn backwards with the finger and thumb of the left hand while the needle is being passed, as in the operation for varicocele. The end of the suture, which passes through the conjoined tendon, is then attached to the eye of the needle, and drawn through between the cord and the sac. If the hernia be large and the ring wide, the needle is now to be passed again from the scrotal wound through the end of *POUPART'S* ligament, just above the pubic spine, and then carried through the inner pillar of the ring and the triangular fascia close to the os pubis, at the edge of the rectus muscle. The outer edge of the suture, that passing through the outer pillar of the ring, is then connected with the needle and drawn across, so as to lace up the canal like a boot.

If a tendon suture is used, the ends are now drawn firmly downwards at the scrotal wound, by which the loop projecting at the puncture in the abdominal wall will be drawn in beneath the skin. The free ends are then secured firmly by a reef-knot, cut short, and buried in the wound. A short drainage tube is then inserted, reaching to the external ring, and an antiseptic dressing applied. If all goes well the wound heals by first intention, and the tendon suture is gradually absorbed.

If a wire is used a loop is left at the puncture in the abdominal wall; the lower ends are twisted down into the scrotal aperture, the upper loop drawn upon so as to tighten the wire, and held firm by two or three twists down into the puncture. The bight of the upper loop is then bent downwards to meet the ends bent upwards; these are curved into the form of a hook to fasten on the loop. A firm pad of lint is placed on the skin under the arch thus formed, and a broad spica bandage secures the whole. No drainage is required. The wire is removed in a week or ten days. The lower end is first untwisted and the ends stretched to take out the spiral twist, and then cut short. Traction on the loop will then usually bring the wire out in one piece, but if there is any difficulty, the loop must be untwisted and the two pieces removed separately. This operation is said to be best fitted for cases of recent hernia in young healthy subjects.

3. **Spanton's Method.**—He closes the canal by screwing in, from above downwards, an instrument closely resembling an ordinary corkscrew, after invaginating a portion of the subcutaneous tissue of the scrotum and sac, as in Wood's method, the finger in the canal protecting the cord. It is left in from seven to ten days. The weak point of this method is that the sac is not removed.

4. At the present time, however, the operations for the radical cure usually include **Ligature of the Neck of the Sac**, flush with the interior of the abdomen, as the principal part of the operation. The sac may then be cut off, and the ligatured opening allowed to slip back into the abdomen; the walls of the canal and the external ring are then drawn together by silver wire, silk, or catgut sutures, taking care to leave sufficient room at the lower part for the cord to pass without compression. The above should always form part of any operation for the relief of strangulated or irreducible hernia. The hernia is exposed, the sac opened, the contents reduced, the neck of the sac freed and tied up as high as possible, and then the sides of the ring and inguinal canal stitched together. Should the sac be left, and the wound be kept aseptic, a drainage tube will not be required, as the serous membrane will absorb all that is necessary to be got rid of; but even when it is cut off, the proximity of the tunica vaginalis of the testicle will also perform the function of

a drainage tube, always provided, of course, that the wound be aseptic. Professor ANNANDALE passes a drainage tube through the bottom of the scrotal tissues.

This operation was first performed by Professor ANNANDALE, in the beginning of 1872, in a case of strangulated femoral hernia. The method he then used was to expose the sac, open it, reduce the hernia, separate the sac as high up as the internal opening, and tie it with strong catgut as close to the general peritoneal cavity as possible. The ligatured sac was then fixed by catgut sutures at the abdominal orifice of the canal, to act as a plug. The rest of the sac below this was removed.

Nearly every Surgeon performs this operation in a slightly different way. Professor CHIENE transfixes the neck of the sac as high up as possible, with a long double ligature of strong catgut, and then ties it in two halves. The two halves are then tied together, and when this is done there are four free ends—two on the inner, and two on the outer side; these ends are then used as stitches for drawing the walls of the canal together—thus matting canal, sac, and all into one mass, which effectually plugs up the aperture in question. Two of the ends are used to fix the ligatured sac in position, the other two are used to bring the walls of the canal together, and after this the two pairs of ends are tied together. In this way there is a triple obstacle to a future hernia—(1) The ligatured sac, (2) the ligatured end plugging the upper opening of the canal, and (3) the matting of the walls of the canal together.

Mr BALL isolates the sac, grasps its neck with a broad pair of catch forceps, and twists it by four or five revolutions of the forceps, and then ties it as high up as possible.

Mr BARKER, after freeing the neck of the sac, passes a double ligature round it, and ties it in two places, and then divides it between the ligatures. The upper part is then pulled up, by means of sutures, to plug the internal opening; the lower part of the sac is not removed. By this means the risk of sloughing or other injury of the testicle is avoided.

The operation, in one of its many forms, where the neck of the sac is tied, is to be preferred to the older and more complicated operations, for various reasons:—(1) Its ease of performance;

(2) the greater permanency of the cure; (3) it gets rid of the sac, which is the chief cause of the persistency of any hernia; (4) it resembles more closely Nature's method of cure, by closing the sac and canal, not corking them; (5) it restores the abdomen to its natural condition, merely leaving a dimple or scar, which tends to disappear, at the site of the internal ring—so that if hernia is reproduced, the new hernia has all the work of sac formation to do over again. Dr MACEWEN, instead of leaving a dimple, aims at making a projection over the internal ring.

It is doubtful if any form of "radical" cure will be constantly and always "radical;" it is always better and safer to wear a *light*-well-fitting truss. The advantage of an operation is, that it will make the truss *certain* of keeping up the hernia.

The radical cure may be required for—(1) Irreducible hernia, because the patient is in constant danger, for (*a*) it may become inflamed, (*b*) it may become obstructed, and (*c*) it may become strangulated; the operation is performed therefore to save the patient from these risks. (2) In reducible hernia that cannot be kept up by a truss. The operation in this case is easier, because the hernia is first reduced and kept in the abdomen, while the sac is exposed and opened, without the risk of wounding the contents of the hernia. (3) For strangulated hernia, because the same incision does for both operations—relief of strangulation and the performance of the radical cure. For the first two conditions, the time of operation may be chosen; and one should therefore see that the health of the patient is good, especially that there is no acute cough, from any cause. Antiseptic precautions are specially important in this operation.

RÉSUMÉ of the operation for strangulated hernia, with the radical cure:—

1. The patient is laid on his back, his shoulders raised somewhat, and the knee of the affected side bent over a pillow. Empty the bladder, shave and wash the seat of the operation.
2. An incision of sufficient length is made over the neck of the sac, by pinching up the skin and subcutaneous

tissue at right angles to the line of incision, and transfixing it, with the back of the knife towards the sac; secure the superficial external pudic artery. In cases of gangrene, or where the parts are much matted by inflammatory action, this method cannot be followed, and one must dissect carefully downwards in the usual manner.

3. Now divide the aponeurosis of the external oblique by opening it at the lower part, and then extending the incision to the full extent of the skin wound, by a probe-pointed bistoury, through the inter-columnar fascia.
4. Next open the cremasteric fascia, by raising it with a pair of dissecting forceps, making a small opening in it, as if it were the sheath of an artery; then introduce a flat director, and slit it and the edge of the internal oblique open.
5. The "*fascia propria*" is now exposed and must be treated in the same way, but very carefully, as it immediately overlies and envelops the sac, and has almost the same shape as the sac, more especially in femoral hernia.
6. The sac must now be isolated; if small, the entire sac may be freed; but if large, the neck only may be cleared; and, in any case, any extra-peritoneal constriction should be divided if possible; if not, the sac should be opened and the constriction divided from within.
7. To open the sac, pinch up a part of its wall between the finger and thumb, when it will be possible to rub the opposed surfaces together, or feel if there is anything gliding under the supposed sac; then raise a small point between the finger and thumb or by the dissecting forceps, and cut a small part of it horizontally, and then enlarge upwards and downwards on a flat director. When the hernia is small, the sac should be opened at the lower part, as there is usually a small collection of fluid there which protects the gut; in large hernia, open over the neck of the sac. In reducible hernia

and incarcerated non-strangulated hernia there is no fluid in the sac. When the sac is opened some fluid usually escapes, and it is customary to smell this fluid, as it will indicate to some extent the state of the gut. The gut will be recognised by its smooth glistening appearance and transverse ramifying arteries.

8. Introduce the director and notch the tight *margin* with the bistoury, its edge being directed upwards; withdraw the director, introduce the finger and divide the deeper part of the constriction, with the finger as guide, keeping the edge of the knife in the same direction as before.
9. Disengage the gut, draw it *gently* down, so that the constricted point, and especially the part immediately above it, can be examined and its fitness for reduction judged of. The principal points to note are, the colour, gloss, and smell; the most important is the *gloss*; if this is lost, the prognosis is grave. If in doubt, having divided the constriction, leave the gut opposite the wound; if not, reduce it, following it with the finger right into the abdominal cavity, so as to make sure that it is properly reduced.
10. After this, separate the neck of the sac, as high in the canal as possible; should the hernia be congenital, this will be difficult, as it practically forms part of the spermatic cord.
11. Tie the neck of the sac, with "*fascia propria*" round it, high up, flush with the interior of the abdomen, with strong catgut ligature. The part below the ligature may or may not be removed.
12. Lastly, stitch the walls of the canal together with catgut, but leaving enough room for the cord to pass below without being compressed; stitch the external wound, introduce a drainage tube, and dress.


It will be observed, therefore, that, from a Surgeon's point of view, there are but five structures to divide, viz.—(1) Skin and fascia, (2) external oblique, (3) cremasteric fascia, (4) "*fascia propria*," and (5) sac.

MACEWEN'S OPERATION.

Preparation of the Parts prior to the Operation.—Before operating, the hair of the pubes and neighbouring parts is closely

Fig. 190.

MACEWEN'S NEEDLES.

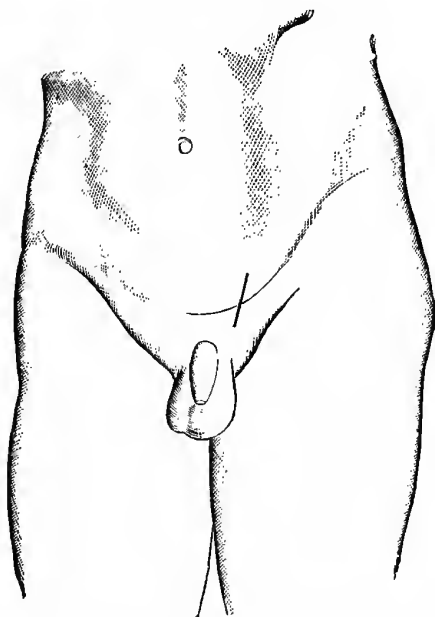


Needles, Right and Left, used in operation for Radical Cure of Hernia. The handle and blade are continuous, being made from one piece of steel.

shaved; the skin is washed with soap and water, a nail brush being employed for this purpose. After drying, turpentine is smeared over the parts to remove any grease which may remain, a little methylated spirit clearing away the turpentine, and leaving the skin in a good condition for operating. The parts are then

Fig. 191.

SITE OF INCISION.



The Dark Line shows Site of Incision, exposing External Opening of Inguinal Canal.


covered with a portion of lint, saturated with an antiseptic solution, until the patient is placed under the influence of an anæsthetic.

When the patient has been anæsthetised, the limb on the side of the hernia is flexed at the knee by a pillow, which is placed under the latter. An assistant, whose duty it is to retract the parts, stands at the opposite side of the Surgeon.

Hernia Needles (Fig. 190).—The needles found to be most useful for the insertion of the stitch into the inguinal canal are figured here, one being used for passing the thread from right to left, the other from left to right. They are serviceable for many other purposes, such as for inserting sutures through broad ovarian pedicles,

Fig. 192.

SEPARATING THE PERITONEUM.



Showing Finger inserted through Inguinal Canal, separating the Peritoneum from Abdominal Aspects of Circumference of Internal Ring.

or through masses of omentum which are about to be removed. Wood's needle might, however, be employed for all the sutures, except the double one introduced into the conjoint tendon.

Operation.—After having reduced the bowel, make an incision sufficient to expose the external abdominal ring (Fig. 191).

An exploration of the sac and its contents is then made, and the finger introduced through the canal examines the abdominal aspects of the internal ring and the relative position of the epigastric artery. The operation may then be divided into two parts, the one relating to the establishment of a pad on the abdominal aspects of the internal ring, the other to the closure of the inguinal canal.

The steps of the operation are as follows :—

1. The Formation of a Pad on the Abdominal Surface of the Circumference of the Internal Ring.—(a) Free and elevate the distal extremity of the sac, preserving along with it any adipose tissue that may be adherent to it; when this is done pull down

Fig. 193.

TREATMENT OF SAC.



The Sac transfixed and drawn into a Series of Folds.

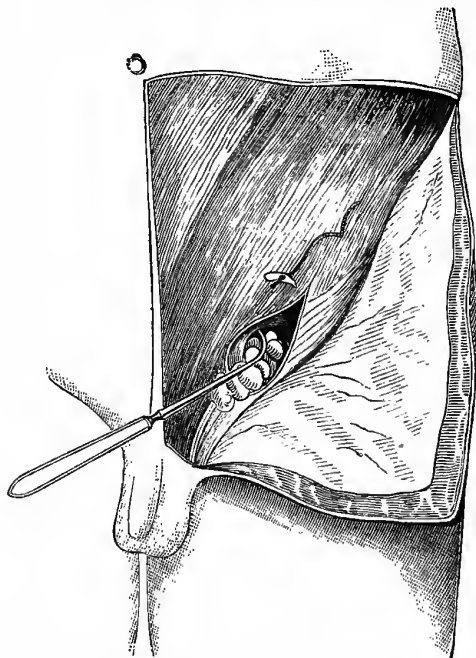
the sac, and, while maintaining tension upon it, introduce the index finger into the inguinal canal, separating the sac from the cord and from the parietes of the canal. (b) Insert the index finger outside the sac till it reaches the internal ring; there separate with its tip the peritoneum for about half-an-inch round the whole abdominal aspects of the circumference of the ring (Fig. 192). (c) A stitch is secured firmly to the distal extremity of the sac. The end of the thread is then passed in a proximal direction several times through the sac, so that when pulled upon, the sac becomes folded upon itself like a curtain (Fig. 193).

The free end of this stitch, threaded on a hernia needle, is introduced through the canal to the abdominal aspect of the fascia

transversalis, and there penetrates the anterior abdominal wall, about an inch above the upper border of the internal ring. The wound in the skin is pulled upwards, so as to allow the point of the needle to project through the abdominal muscles without penetrating the skin (Fig. 194).

Fig. 194.

THREAD INTRODUCED TO PULL UP SAC.



The Hernia Needle carrying the Thread from the upper portion of the Sac through the Abdominal Muscles from behind forward, about an inch above the Internal Ring.

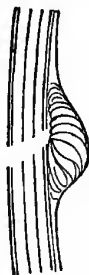The thread is relieved from the extremity of the needle, when the latter is withdrawn. The thread is pulled through the abdominal wall, and when traction is made upon it, the sac, wrinkling upon itself, is thrown into a series of folds, its distal extremity being drawn furthest backwards and upwards. An

assistant maintains traction upon the stitch until the introduction of the sutures into the inguinal canal, and when this is completed, the end of the stitch is secured by introducing its free extremity several times through the superficial layers of the external oblique muscles. A pad of peritoneum is thus placed upon the abdominal side of the internal opening, where, owing to the abdominal aspect of the circumference of the internal ring having been refreshed, new adhesions may form (Fig. 195).

2. **Closure of the Inguinal Canal.**—The sac having been returned into the abdomen and secured to the abdominal circumference of the ring, this aperture is closed in front of it in the following manner:—The finger is introduced into the canal, and lies

Fig. 195.

SAC IN NEW POSITION.



Pad covering Abdominal Aspect of Internal Ring.

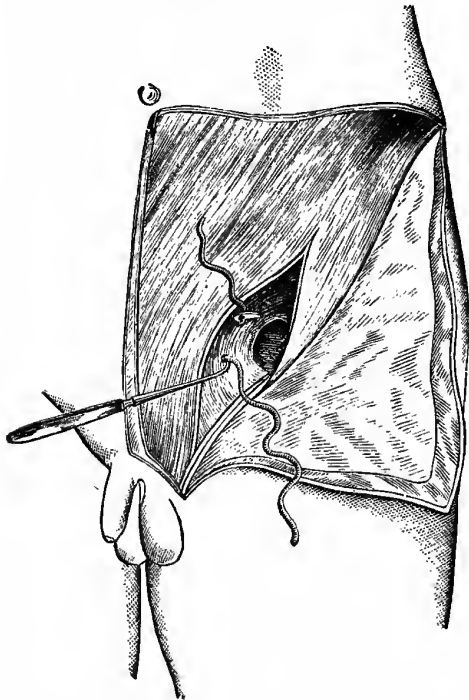
between the inner and lower borders of the internal ring, in front of and above the cord. It makes out the position of the epigastric artery, so as to avoid it. The threaded hernia needle is then introduced, and, guided by the index finger, is made to penetrate the conjoint tendon in two places; first, from without inwards, near the lower border of the conjoint tendon; second, from within outwards, as high up as possible on the inner aspects of the canal. This double penetration of the conjoint tendon is accomplished by a single screw-like turn of the instrument (Fig. 196). One single thread is then withdrawn from the point of the needle by the index finger, and when this is accomplished, the needle, along with the other extremity of the thread, is removed. The conjoint tendon

is therefore penetrated twice by this thread, and a loop left on its abdominal aspect (Fig. 197).

Secondly, the other hernia needle, threaded with that portion of the stitch which comes from the lower border of the conjoint

Fig. 196.

CONJOINT TENDON.



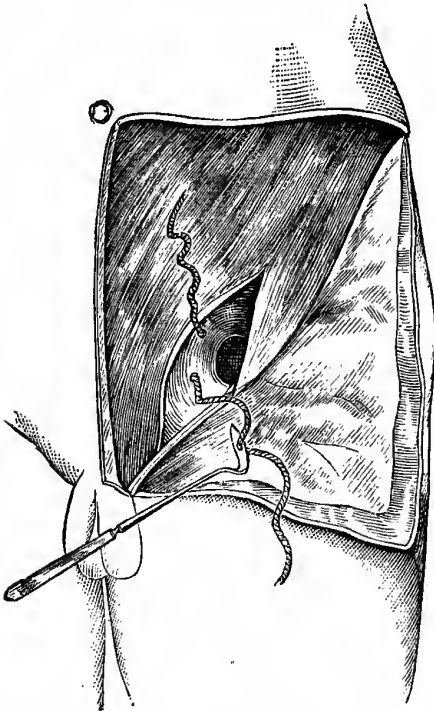
The threaded Hernia Needle making double penetration of Conjoint Tendon.

tendon, guided by the index finger in the inguinal canal, is introduced from within outwards, through *POUPART'S* ligament, which it penetrates at a point on a level with the lower stitch in the conjoint tendon (Fig. 198). The needle is then completely freed from the thread and withdrawn.

Thirdly, the needle is now threaded with that portion of the catgut which protrudes from the upper border of the conjoint tendon, and is introduced from within outwards through the transversalis and internal oblique muscles, and the aponeurosis of the external oblique, at a level corresponding with that of the

Fig. 197.

LOOP IN CONJOINT TENDON.



upper stitch in the conjoint tendon. It is then quite freed from the thread and withdrawn (Fig. 199).

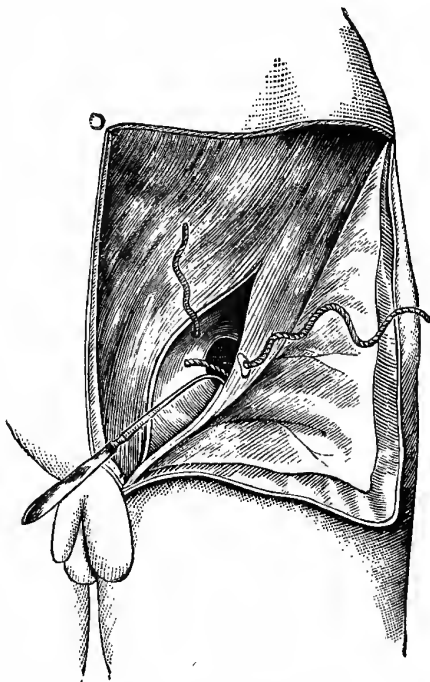
There are now two free ends of the suture on the outer surface of the external oblique, and these are continuous with the loop on the abdominal aspect of the conjoint tendon. To complete

the suture, the two free ends are drawn tightly together and tied in a reef-knot. This unites firmly the internal ring.

In order to avoid compression of the cord, which might lead to serious embarrassment and sloughing or ultimate atrophy of

Fig. 198.

EXTERNAL PILLAR.



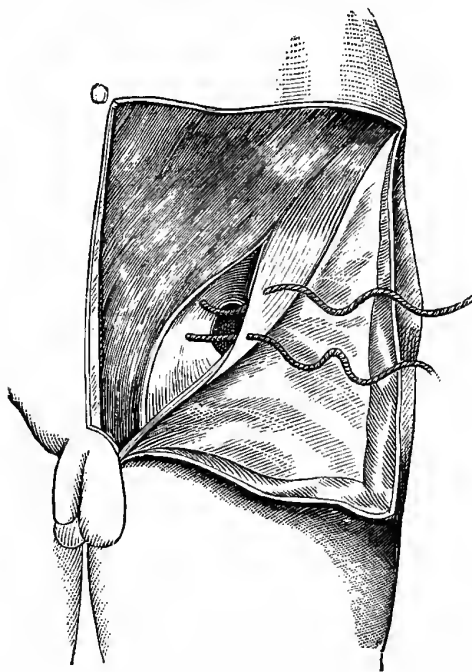
Thread from Lower Border of Conjoint Tendon being carried through
Outer Pillar of Internal Ring.

the testicle, it ought to be examined before tightening each stitch. The cord ought to lie behind and below the sutures, and be freely movable in the canal. It is advisable to introduce all the necessary sutures before tightening any of them. When this

is done, they might all be experimentally drawn tight, and maintained so, while the operator's finger is introduced into the canal to ascertain the result. If satisfactory, they are then tied, beginning with the one at the internal ring, and taking up in

Fig. 199.

THREAD READY FOR TYING.



In Figures 192, 194, 196, 197, 198, and 199, the Skin and Cellular Tissue is reflected in a flap, and the External Oblique is opened up in such a way as to expose the interior of the Canal and the Internal Ring.

order any others which may have been introduced. In the great majority of cases the stitch in the internal ring is all that is required.

During the operation the skin is retracted from side to side, to bring the parts into view, and to enable the stitches to be fixed

subcutaneously. When the retraction is relieved, the skin falls into its normal position, the wound being opposite the external ring. The operation is therefore partly subcutaneous.

When the canal has been brought together, a decalcified chicken-bone drainage tube is placed with its one extremity next the external ring, the other projecting just beyond the lower border of the external wound. A few chromic gut sutures are then introduced along the line of skin incision.

Dressing the Wound.—Iodoform is dusted over the wound, the interstices of the scrotum, and its junction with the thigh. A sublimated wood-wool pad is applied, held in position by an aseptic bandage. As a rule, a portion of elastic webbing is placed over the margins of the pad to secure it firmly. As the patient is laid in bed, a pillow is placed under his knees, while his shoulders are slightly raised, so as to relax the tissues about the canal.

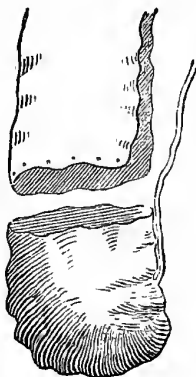
After Treatment.—The rectal temperature is taken night and morning, and at the same time the dressings are inspected. The dressings are left undisturbed from fourteen to twenty-one days, unless they are previously stained or the temperature is abnormally high. On their removal at the end of that period, the wound is found healed, the extremity of the decalcified drainage tube which projected beyond the margin of the skin is seen to lie loose on the dressings along with the external portion of the majority of the superficial stitches. A fresh pad is applied to maintain pressure over the part. From four to six weeks after the operation the patient is allowed to rise from bed, but he is not permitted to work until the end of the eighth week. He is further advised not to lift heavy weights until the end of the third month at the very earliest. Adults engaged in laborious occupations are advised to wear a bandage and pad as a precautionary measure. Those who are not so engaged are not required to wear a belt except when of very lax habit. All are recommended not to over-strain themselves. In the majority of children (six to fourteen years) the closure is so complete and firm that further treatment by pad or belt is quite unnecessary.

In Congenital Inguinal Hernia the sac is first isolated from the cord. As this structure is generally intimately connected with the posterior surface of the sac, often by close organic

adhesion, the sac should be divided longitudinally by two parallel incisions, one on each side of the cord, and the latter permitted to lie behind clear of the sac. The isolated sac should then be divided transversely about an inch above the testicle. The lower part is formed into a tunica vaginalis. The upper is pulled down as far as possible, and dealt with quite as the sac of an acquired hernia, additional precautions being necessary to clear the cord at the internal abdominal ring. It is freed of its connections, and placed as a pad on the abdominal aspect of the circumference of the internal ring (Fig. 200). On

Fig. 200.

CONGENITAL INGUINAL HERNIA.



Manner of treating the Sac in Congenital Inguinal Hernia.

one occasion a separate tube was formed for the cord out of the sac, but this has not been repeated.

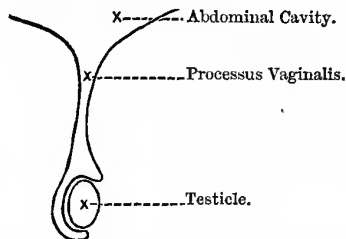
In congenital inguinal hernia it has been advised that the testicle should be ablated. On two occasions this has been done—once when the testicle was injured by a blow received prior to admission, and once when that organ was affected by cystic degeneration. In both instances the absolute firmness and rigidity of the abdominal wall which resulted, taken along with the ease of the procedure, explains the desire for ablation of the testicle in congenital hernia evidenced by the advocates of this method.

OTHER VARIETIES OF INGUINAL HERNIA.

1. **Congenital**, or hernia in the sac of the tunica vaginalis; the *tendency* is congenital, not the disease. The hernia in this case lies inside the tunica vaginalis, and therefore in contact with, and completely enveloping, the testicle, so that that organ cannot be distinctly felt, separate from the tumour; it is always oblique, and takes the same course as the testicle. It is always suddenly produced as the sac is pre-formed, extending into the scrotum at once; and further, the neck is very long and narrow, passing up into the abdomen obliquely. This form of hernia is often found along with congenital phimosis, preputial adhesions, or a very narrow meatus; it is therefore necessary to attend to these points

Fig. 201.

CONDITION OF THE PROCESSUS VAGINALIS
In Congenital Hernia.



first, and it is a good plan *always* to examine the child's penis in cases of hernia, and for many other diseased conditions, such as apparent hip disease. Always examine the scrotum also, to find out whether both testicles are down. The possibility of its occurrence is due to the fact that the process of peritoneum (*processus vaginalis*), which passes down before the testicle into the scrotum, has not become obliterated, as in the normal condition, but remains open (Fig. 201) and thus serves as a medium of communication between the general cavity of the peritoneum and the tunica vaginalis, through which the congenital hernia descends. It is very apt to be strangulated, as the neck is long and narrow, with a tendency to become longer and narrower, and when it is

strangulated, the prognosis is serious; the operation here admits of *no delay*. In operating on this variety, two things must be kept in mind—(1) that there is no sac apart from the tunica vaginalis, and (2) the close relation of the constituents of the cord to the tunica and its narrow neck; these two points make it very difficult to obliterate the neck of the sac. In relieving strangulation, which is so common and so serious in this variety,

Fig. 202.

CONDITION OF THE PROCESSUS VAGINALIS
Predisposing to the Infantile and Encysted Forms of Hernia.

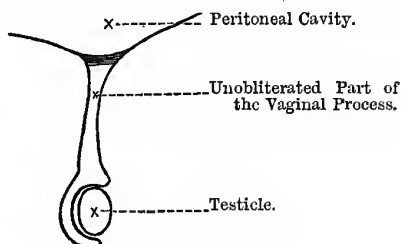
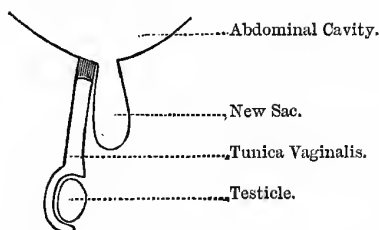


Fig. 203.

INFANTILE HERNIA.



the *whole length* of the canal, from its scrotal to its abdominal end, must be divided, as the strangulation here is due to a process of condensation, elongation, and increasing obliquity, which this canal naturally undergoes (SPENCE).

2. *Infantile Hernia* (HEY).—The hernia in this case, with its new sac, passes down *behind* the unobliterated tunica vaginalis, and is due to the fact that the *processus vaginalis* is only obliterated

at the internal abdominal ring (Fig. 202), and the gut passes down behind the large tunica vaginalis (Fig. 203). Should strangulation occur in this form, in the operation for its relief, the Surgeon will have to pass through *both layers of the tunica vaginalis* before he reaches the neck of the sac, and the layer forming the anterior wall of the sac before he reaches the hernia, or three layers in all.

Fig. 204.
ENCYSTED HERNIA.

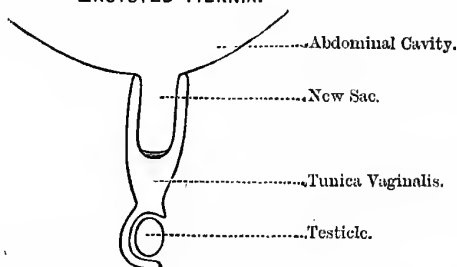
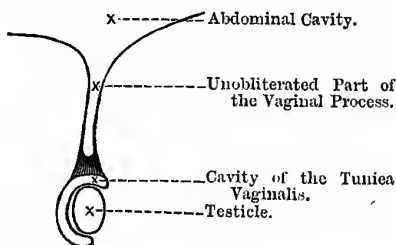


Fig. 205.
CONDITION OF THE PROCESSUS VAGINALIS
In Funicular Hernia.



3. **Encysted Hernia** (SIR ASTLEY COOPER).—This is where the sac is invaginated into the unobliterated vaginal process, and not behind it, as in infantile (Fig. 204).

NOTE.—*Hernia in infants, especially when the gut is empty, is said to be occasionally translucent, just like hydrocele.*

4. **Hernia into the Funicular Process.**—In this case the *processus vaginalis* is only obliterated close to the testicle, leaving

the whole upper part open (Fig. 205), into which the gut descends. The hernia only extends to the *top* of the testicle and does not envelop it; it is always oblique and suddenly produced.

There is another congenital malformation of the processus vaginalis—viz., where the entire canal remains open, but an annular constriction of its walls takes place somewhere between the external abdominal ring and the testicle. In this condition we may get what is called an "**Hour-glass Hernia.**"

In the female there is a process of peritoneum that passes down along the round ligament, corresponding to the processus vaginalis of the male, and is known as the **Canal of Nuck**; from the presence of this structure, the female child is very frequently the subject of congenital inguinal hernia. It may also occur in the adult female as well; the inguinal canal in the female is slightly longer than in the male.

The contents of the hernial sac vary. If it consist of the intestine alone, it is called an **Enterocoele**; it is resonant on percussion, smooth and elastic, and gurgles on manipulation, from the mixture of air and fluid. It is usually some part of the small intestine, most frequently the ileum; sometimes the caput caecum of the large. Hernia of the omentum is called **Epiplocele**; it is dull on percussion, firm, lobulated, and doughy, and there is no gurgle on manipulation; and the impulse on coughing may be very slight or absent. Hernia of both intestine and omentum together, is called an **Entero-Epiplocele**; the symptoms are a mixture of the two previous forms.

CHAPTER XL.

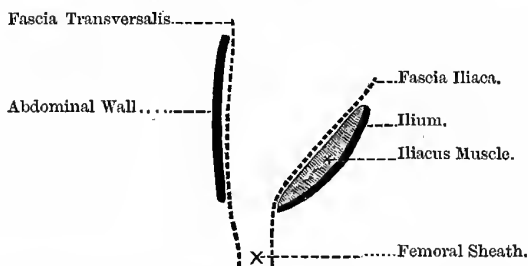
THE ABDOMEN—(*Continued*).**FEMORAL HERNIA.**

It will be well at this point to say a word or two about the anterior part of the fascia lata of the thigh and the saphenous opening. The fascia consists of (1) an *iliac* part, lying external to the saphenous opening, and (2) a *pubic* part, lying internal to the same opening. The *iliac* part is attached to the crest of the ilium, anterior superior spine, POUPART'S ligament, and the pectineal line, and becomes continuous below with the pubic part. From the pectineal line and spine of the pubes it is reflected down, forming the superior cornu and the falciform process of the saphenous opening. The *pubic* part is attached above to the pectineal line, and internally to the margin of the pubic arch; it passes *beneath* the sheath of the femoral vessels, binding down the psoas and iliacus muscles, and is then lost on the capsule of the hip joint. At the lower part it becomes continuous with the iliac part, and at the point where the two meet they form the inferior cornu of the saphenous opening. The iliac part thus passes in *front* of the femoral vessels, while the pubic part passes *behind* them, and between the two is the **saphenous opening**. This is an oval opening at the upper and inner part of the thigh, just below the inner end of POUPART'S ligament, and internal to the line of the femoral vessels, and is produced by the above splitting and folding of the fascia lata of the thigh. It is directed obliquely downwards, forwards, and inwards; its length is an inch and a half, and its width about half an inch. Its lower margin is well defined, and is called the *inferior cornu*; its upper margin, the *superior cornu*; its outer edge, the falciform process of BURNS; its inner edge, however, is ill defined, and lies, as we have seen,

on a plane posterior to the outer edge, passing behind the femoral vessels. The *superior cornu* touches POUPART'S ligament and is situated about midway between the spine of the pubes and the femoral vessels. There is a strong band of fibres passing between the superior cornu of the falciform border of the saphenous opening, and GIMBERNAT'S ligament; it arches over the femoral artery, and is known as the *femoral ligament of Hey*. This so called opening, however, in the recent state, is covered by the *cribriform* or sieve-like fascia—this fascia being perforated by a large number of lymphatic vessels, and the long saphenous vein, hence the name. If the fascia lata and the cribriform fascia be reflected, the *femoral sheath* is exposed (see Fig. 159); the anterior part of this sheath is a continuation of the fascia transversalis

Fig. 206.

FORMATION OF THE FEMORAL SHEATH.



lining the abdominal wall, and passing down beneath POUPART'S ligament; the posterior part of the sheath is a continuation of the fascia iliaca, also from the abdomen (Fig. 206). On the anterior part of this sheath there are a few thickened transverse bands of fascia just below POUPART'S ligament, which are called the "*deep crural arch*" (the "*superficial crural arch*" being POUPART'S ligament). The *femoral* or *crural* sheath is funnel-shaped, being too wide just beneath POUPART'S ligament, but closely adherent to the vessels about one inch below the saphenous opening; it is divided into three compartments, by septa passing from the anterior to the posterior wall—the *external* contains the femoral artery, the *middle* the femoral vein, while the *inner* contains and is closed by condensed areolar tissue, a lymphatic gland, and some lymphatic

vessels and fat,—the whole mass being called the *septum crurale*, and the compartment containing them the *crural canal*. This canal is, therefore, situated between the femoral vein and the inner wall of the crural sheath. It extends from the *crural ring* to the upper part of the saphenous opening, and is about half-an-inch in length.

Boundaries of the Canal.—**Anterior wall**, the fascia transversalis, **POUPART'S** ligament, and the falciform process of the fascia lata; **posterior wall**, the iliac fascia and the pubic part of the fascia lata; **outer wall**, the fibrous septum covering the inner side of the vein; the **inner wall**, the inner side of the femoral sheath.

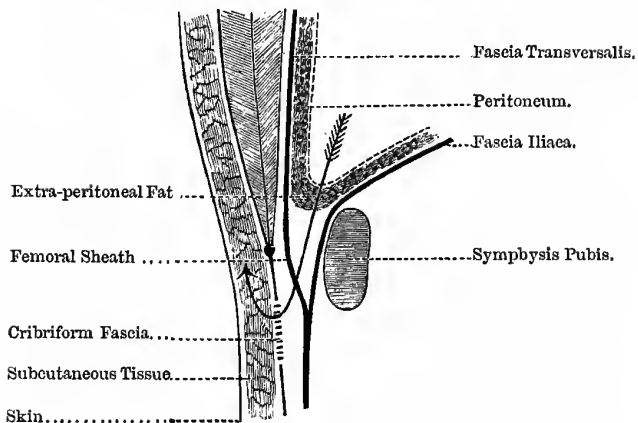
Boundaries of the Crural Ring.—In **front**, **POUPART'S** ligament, and deep crural arch; **behind**, the body of the pubes, covered by the pectineus and the fascia iliaca; on the **inner side**, the sharp border of **GIMBERNAT'S** ligament, conjoined tendon, and fascia transversalis; on the **outer side**, the femoral vein, covered by its sheath. Femoral hernia is more common in women—(1) Because the distance between the iliac and pubic spines is greater, and **GIMBERNAT'S** ligament is smaller, and for these reasons the femoral ring is larger; and (2) from changes in the abdominal viscera during pregnancy. The long diameter of the hernia is transverse, not vertical, as in inguinal. The **coverings** of this form of hernia are—(1) The skin; (2) superficial fascia; (3) cribriform fascia; (4) the femoral sheath; (5) crural septum, which is equivalent to the extra-peritoneal cellular tissue and fat; and (6) the peritoneum (Fig. 207).

The *fascia propria* is the anterior part of the crural sheath fused with the septum crurale, and therefore immediately invests the sac; to distinguish between the sac and fascia propria (see vol. ii., page 350).

In reducing femoral hernia by taxis, it is necessary (1) to bear in mind the course of the hernia, and (2) to put the limb in such a position that the falciform process of the saphenous opening will be relaxed. The hernia enters the crural ring, passes down the crural canal, till it is checked by the adhesion of the sheath to the femoral vessels, and then passes forwards and escapes by the saphenous opening—at first passing downwards and forwards, and

Fig. 207.

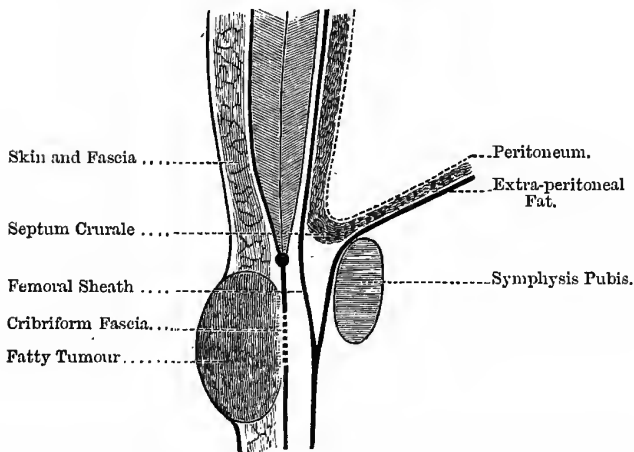
COURSE AND COVERINGS OF FEMORAL HERNIA.
(After HEATH.)



The arrow indicates the course of the Hernia.

Fig. 208.

AN ORDINARY FATTY TUMOUR.

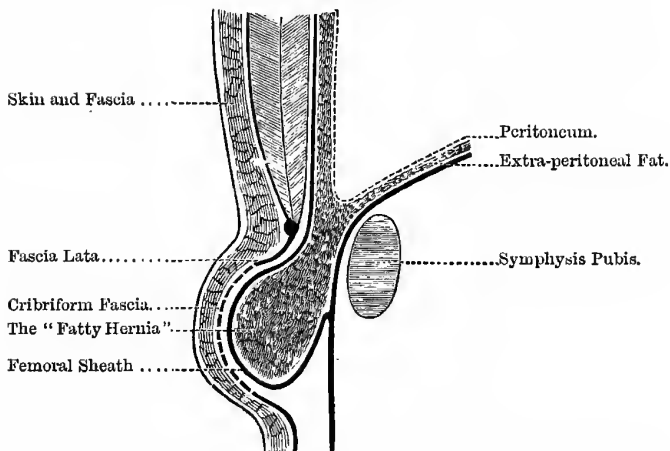


Tumour not fixed below, but freely movable in the Subcutaneous Tissue.

then upwards; and, therefore, in applying pressure, it must be directed downwards, backwards, and upwards; and to relax the falciform margin of the saphenous opening, the thigh must be flexed on the abdomen, adducted, and rotated inwards. The hernia is directed upwards on account of the close attachment of the superficial fascia to the lower margin of the saphenous opening, which thus prevents its further descent. The fact that there is greater friction and pressure on the upper surface, from POUPART'S ligament, will also direct it upwards, and perhaps also the flexing of the thigh will press in the same direction. The seat of stricture in femoral hernia is usually the sharp edge of GIMBERNAT'S ligament. Femoral enterocele must be distinguished from three forms of fatty swelling in this region—(a) a subcutaneous lipoma (Fig. 208), (b) hernia of septum crurale (“fatty hernia”) (Fig. 209), and (c) epiplocele (Fig. 210). The two latter are tethered on their deep surface, an ordinary fatty tumour is freely movable in the tissues. Occasionally, however, a “fatty hernia” may become detached from the extra-peritoneal fat and be engrafted on to the tissues in its new position, and grow there, closely resembling an ordinary fatty tumour. It must also be diagnosed from an enlarged gland with inflammation *around it*; here the fixing on the deep surface is not at *one* point, but is more general and all round the gland, with *probably* thickening and adhesion of the skin over it. The gland in the femoral canal may thus enlarge and come forwards; of course, an inflamed gland might be *plus* a hernia at the same time. If the bowels move with castor oil, and there is no vomiting, it is not likely to be a strangulated hernia.

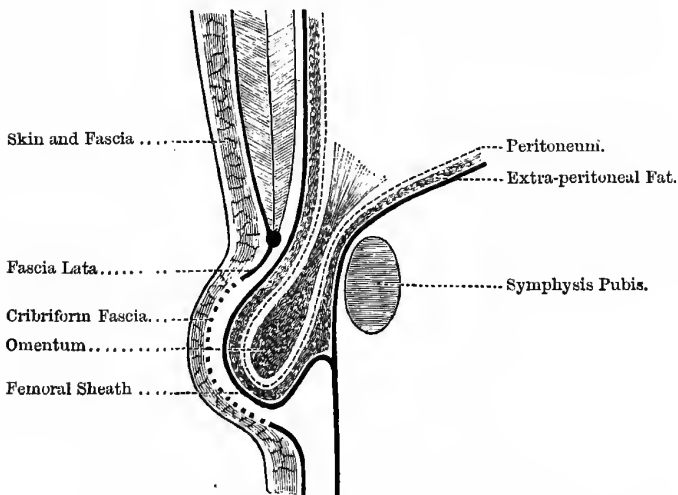
Operation for Strangulated Femoral Hernia.—The superficial structures are divided by a vertical or a T-shaped incision. The vertical limb of the incision is made over the neck of the tumour; it may be two or three inches long, and its centre must correspond to the upper part of the saphenous opening. The horizontal limb is made parallel with POUPART'S ligament, and immediately below it. Whether the T-shaped or a vertical incision be used, it is better to make it *as far as possible* from the genital organs, compatible with the object in view; it will thus be more easily kept aseptic. The various coverings are carefully divided till the sac is reached; and the finger is then passed along the canal till the stricture is found,

Fig. 209.
"FATTY HERNIA."



This mass is tethered on its deep surface. The "Sac" of this Hernia is the Femoral Sheath.

Fig. 210.
FEMORAL EPIPLOCELE.

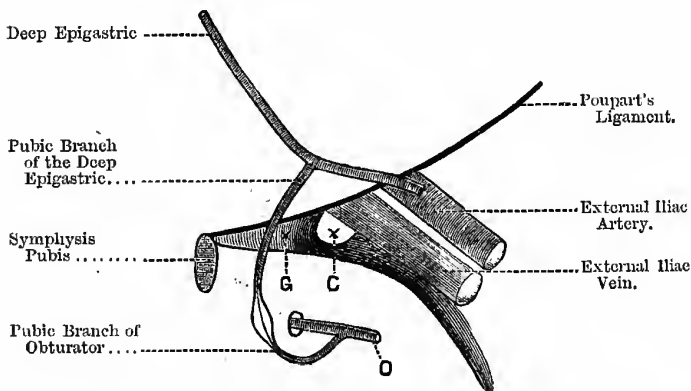


This mass is also tethered on its deep surface.

which is relieved by cutting cautiously upwards and inwards,* so as to notch or divide both GIMBERNAT'S and HEY'S ligaments; if this cannot be accomplished by the extra-peritoneal method, the sac must be opened at the *lower* part and the stricture divided from within it. The section is made in this direction not only for the reason given above, but for other reasons: thus, if the section were made outwards, the femoral vein is in danger; if upwards and outwards, the epigastric artery; and if directly upwards, the spermatic

Fig. 211.

VESSELS NEAR CRURAL RING—NORMAL.



G. Gimbernat's Ligament. C. Crural Ring. O. Obturator Artery.

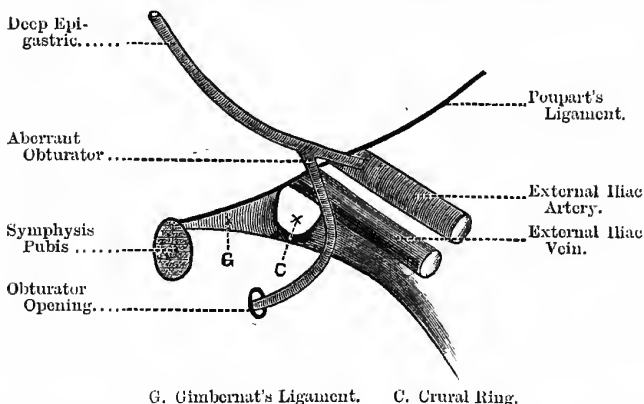
cord might be cut. The great danger is in the possible abnormal origin of the obturator artery, which may come in the way of the inward incision; try if possible to feel the pulsation before cutting, and if the pulsation be felt, blunt the edge of the knife, which will even then easily cut the tense fascia, but will displace the artery before it. The blood-vessels near the crural ring (Fig. 211) under normal conditions are—(1) The femoral vein, to its outer side; (2) the deep epigastric artery, to the front and outer side of the

* It will be noticed that I have said to cut *upwards and inwards* in both femoral and inguinal hernia; this simplifies matters, and is really the proper direction in both cases; but, of course, *upwards* in inguinal, and *inwards* in femoral does perfectly well.

opening; and (3) the pubic branch of the deep epigastric, also in front, and passing inwards over it. The obturator artery usually arises from the anterior division of the internal iliac artery, and escapes from the pelvis by the upper part of the obturator foramen; but this artery sometimes arises from the deep epigastric, and when it does so, it is usually the pubic branch very much enlarged. In order to reach the obturator foramen, it may pass in either of two directions—(1) It may pass down close to the vein, and external to the crural ring (Fig. 212), in one out of every four cases (WOOD); or (2) it may arch over the crural ring, and descend internal to it

Fig. 212.

ABERRANT OBTURATOR—NON-DANGEROUS VARIETY.

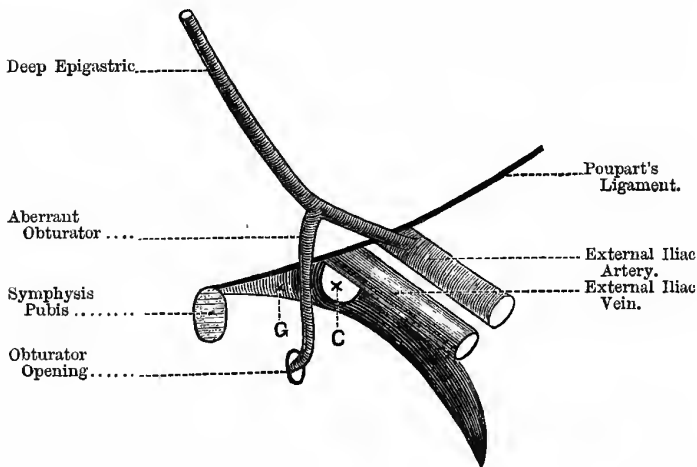


(Fig. 213), in about one out of every eighty cases. It is in this latter variety that the danger exists, because in cutting inwards on GIMBERNAT'S ligament, the vessel is also apt to be divided or wounded; but, fortunately, this variety of abnormal distribution of the artery is not very common, and this is all the more fortunate because it is impossible to foresee or avoid the accident. In the diagnosis between this form of hernia and the inguinal form, it is well to remember that the neck of the sac in femoral hernia is situated below POUPART'S ligament, and external to the spine of the pubes; whereas in inguinal hernia the neck of the sac is above POUPART'S ligament, and internal to the pubic spine.

To find the spine of the pubes, in the female, abduct the thigh, make the adductor longus tense, and run the finger along the tense edge of the muscle, which will guide to the projection in question, as the muscle is inserted just below it; in males, the same plan may be adopted, but it is usually found by pushing the forefinger into the bottom of the scrotum and up along the cord to the external abdominal ring, when it can easily be made out whether the swelling occupies that opening or not.

Fig. 213.

ABERRANT OBTURATOR—DANGEROUS VARIETY.



G. Gimbernat's Ligament. C. Crural Ring.

In performing the radical cure in a case of femoral hernia, one must remember the presence of the femoral vein on the outer side of the crural ring and canal; indeed this constitutes the difficulty of the operation. Mr WOOD, after tying the neck of the sac, removing the protruding part, and allowing the stump to slip into the abdomen, relaxes the parts by position, pushes the femoral vein out of the way (protecting it with the finger), and stitches the pubic portion of the fascia lata to POUPART'S ligament by two or three sutures. Other operators also tie the neck of the

sac flush with the interior of the abdomen, and cut off the protruding part, leaving the stump to plug up the opening, or stitch it to GIMBERNAT'S ligament; or it may be entirely reduced into the abdomen, and the various fascial structures about the opening stitched together. Thus the inferior cornu of GIMBERNAT'S ligament, or the fascia covering the pubic bone may be stitched obliquely to POUPART'S ligament, or the pubic part of the fascia lata may be stitched to the same structure. The **chief points** of the operation are (1) to get rid of the sac, and (2) take care of the femoral vein.

The obliteration of the canal is brought about by—(1) Leaving an omental stump to plug up the crural ring, (2) tying the neck of the sac, and (3) stitching the resistant tissues together outside, over the canal—*e.g.*, the pubic part of the fascia lata to POUPART'S ligament.

Table contrasting the equivalent Coverings of the three chief forms of Hernia:—

Oblique Inguinal.	Direct Inguinal.	Femoral.
1. Extra-peritoneal fat.	1. Extra-peritoneal fat.	1. Septum crurale.
2. Fascia transversalis, or infundibuliform fascia.	2. Fascia transversalis.	2. Femoral sheath.
3. Cremaster muscle, in series with internal oblique.	3. Conjoint tendon of transversalis and internal oblique.	3. } Cribiform fascia.
4. Inter-columnar, or spermatic fascia.	4. Inter-columnar, or spermatic fascia.	4. }
5. Superficial fascia.	5. Superficial fascia.	5. Superficial fascia.
6. Skin.	6. Skin.	6. Skin.

Littre's Strangulated Hernia.—In this case only a *part* of the circumference of the bowel is involved. It is usually femoral, sometimes obturator, and, as a rule, occurs in women.

Cloquet's Hernia.—When the hernia passes behind the femoral vessels and rests in the pectineus muscle.

Laugier's Hernia.—When the hernia passes through GIMBERNAT'S ligament.

Obturator Hernia.—This is a rare form, and very often is not detected during life: it usually occurs in women. It may be possible to feel it per vaginam, or per rectum, and it causes a slight fullness, or actual tumour, or it may be only an increased sense of resistance and tenderness on pressure, at the inner and upper part of SCARPA'S triangle, deep among the adductors and to the inner side of the femoral vessels. When strangulated, the obturator nerve is pressed on, and there is pain down the inner side of the thigh and at the knee joint, especially on eversion of the thigh, and it may therefore simulate hip-joint disease. In likely cases it will be justifiable to incise and explore; the incision should be parallel with the femoral artery, and on the adductor longus muscle. The fascia lata and pectineus muscle must be divided. The **coverings** of an obturator hernia are—skin, superficial fascia, fascia lata, pectineus, fascia covering the obturator externus, the obturator externus itself, extra-peritoneal fat, and then comes the sac of the hernia. The pelvic fascia does not give it a covering, as the opening through which the hernia comes is above the upper edge of the parietal pelvic fascia. In dividing the constriction, the edge of the knife must be directed *downwards*, because the artery is usually above.

Umbilical Hernia (*Omphalocele* or *Exomphalos*).—This form—“starting of the navel”—is not uncommon in children; in the adult, it is more usually ventral, and not exactly at the umbilicus. It occurs in stout-bellied people usually, and comes through some of the fibrous septa, such as the linea semilunaris, or lineæ transversæ, but very rarely *at* the umbilicus. It is supposed that the apertures through which the vessels or pellets of fat pass, cause the *local weakness*, necessary for the production of any form of hernia. It usually forms a large tumour, which rapidly becomes irreducible from omental adhesions. In the child, the coverings are often very thin, consisting of little else than the integument of the umbilical cord—the contents consist for the most part of bowel; in the adult the coverings are thicker, consisting of integument and deep fascia, transversalis fascia, and sac. Umbilical hernia (or ventral), in the adult, has a great tendency to become incarcerated, but very little tendency to strangulation, as the opening is usually large, and there is practically no neck to the sac. In the child the opening readily closes, if the bowel be kept in

the abdomen for a few months by a broad flat pad; in the child, this form of hernia never strangulates, and never causes death. Should it become strangulated in the adult, it is always at the lower part of the hernia, where it is sharply bent over the fascial aperture from its own weight; as the contents are usually omentum and jejunum, the effects of strangulation are very serious, as it is so high up and so near the great solar plexus. Operations are not very successful or safe in this form of hernia, probably from the proximity to the great nervous plexuses, and the peritoneal sac, the adhesion of the bowel to the sac; and the fact that the bowels are apt to protrude during the operation, from the great intra-abdominal pressure, considerably embarrass the operator. It is only to be undertaken when no other means can give relief. Formerly the patients often succumbed to septic peritonitis; now-a-days this risk is greatly diminished. Hence, if reducible and a pad can keep it in, do not operate; and, even though irreducible, do not operate unless there is pain and well-marked signs of strangulation. For the radical cure, the "neck" of the sac is tied, and the projecting part cut off; after this, the stump may be left to plug up the opening, as Mr BANKS does; or the most resisting tendinous structures at the sides of the opening, as the fascia transversalis, may be freshened and stitched closely together, as after an ordinary laparotomy.

When a hernia in this region consists of omentum, it may be necessary, just as in the femoral region, to distinguish it from a fatty tumour, and an outgrowth of the extra-peritoneal fat. In **Lipoma**, the mass is perfectly movable in the belly-wall; is not, and never has been reducible, and has no impulse on coughing. The **extra-peritoneal fat** is fixed on its deep aspect to the belly-wall, is not reducible, and has no impulse on coughing. **Epiptocele** is also fixed to the belly-wall, but is or has once been reducible, and has an expansile impulse on coughing. One must, in all cases of hernia, distinguish between a true impulse, which fills out and expands the tumour on all sides and indicates its communication with the abdominal cavity, and a mere thrust forwards—just as in the case of a true aneurism and a tumour over an artery. In hernia of the cæcum and bladder (*Cystocele*), the sac is absent or only partial, as the normal peritoneal covering is only partial; for this reason these herniæ are practically always irreducible.

Ventral Hernia.—By this is meant a hernia through any part of the abdominal wall, except the inguinal, the femoral, or the umbilical apertures. The treatment and the radical cure are the same as in umbilical hernia.

Lumbar Hernia.—Here the gut escapes through the "**triangle of Petit**," either by piercing the structures forming the floor, or by pushing them before it. This triangle is **bounded** by the latissimus dorsi behind, the external oblique in front, and the highest point (about the middle third) of the iliac crest below; the floor is formed by the internal oblique and the fascia lumborum. A lumbar hernia may follow in the track of an old lumbar abscess, and may be mistaken for an abscess, especially if there be traces of a previous abscess at the part, and at the same time the spine is stiff and rigid; under such circumstances one is very apt to think that it is a recrudescence of the old disease, and that the swelling is a collection of pus, and plunge a knife into it. If the swelling be a hernia, this of course is a serious mistake; and before opening any abscess in this region it is well to percuss the swelling—if intestine, it will be resonant; but if an abscess, dull on percussion. In operating on a case of lumbar hernia, after getting rid of the sac, stitch the contiguous margins of the latissimus dorsi and the external oblique with strong catgut.

Diaphragmatic Hernia.—**Varieties**—(1) *Congenital*, the left leaflet of the central tendon being absent; this is the most common variety, and is due to an arrest of development whereby the original *pleuro-peritoneal cavity* has not been completely divided into thorax and abdomen. (2) Where the abdominal viscera pass through one of the naturally deficient parts of the diaphragm, usually just behind the ensiform cartilage, or in front of the vertebræ, occasionally through the œsophageal opening. (3) Cases where the diaphragm is ruptured by external violence; it is said that rupture of the diaphragm is usually followed by excessive and insatiable thirst. From the presence of the liver, protrusions of abdominal viscera into the thoracic cavity will only occur on the left side. The displaced thoracic viscera may be recognised by percussion and auscultation; the stomach, transverse colon, and omentum, are the viscera usually herniated.

THE PERINEUM.

Dissection of the Perineum.—The Anatomical perineum corresponds to the inferior outlet of the pelvis, and in shape resembles an heraldic lozenge, and has the following boundaries—In *front*, the symphysis pubis and sub-pubic ligament; *laterally*, in *front*, the divergent rami of the pubic arch and tuberosities of the ischia—*behind*, the convergent great sacro-sciatic ligaments, overlapped by the glutei maximi muscles; and *behind* by the tip of the coccyx. The space is divided into two parts by a line passing from the anterior border of one tuberosity of the ischium to the other; the posterior division is called the rectal part, and the anterior division the urethral. The Surgical perineum does not extend so far back; it must be regarded as ending at the “central point of the perineum”—the point where the terminal prolongation of the triangular ligament is attached, and where the superficial perineal fascia turns round the transversus perinei muscle to be attached to the base of the triangular ligament; the two transversus perinei muscles, accelerator urinæ, and sphincter ani all meet at this point: it is midway between the anus and the root of the scrotum. All beyond this point is to be regarded as ischio-rectal fossa, or the *rectal part* of the anatomical perineum. The **female perineum** is the angular interval left between the rectum (third part) as it passes downwards and backwards, and the vagina as it passes downwards and forwards.

The Posterior or Rectal Part.—This part is the same in both sexes, and contains the lower end of the rectum and tip of the coccyx; and on either side there is a space known as the “**ischio-rectal fossa.**” Each space is pyramidal in shape, and has the following boundaries—Its **base** is formed by the skin and fascia covering it; its **apex** by the meeting of the outer and inner walls; the **outer wall** is the obturator fascia covering the obturator internus muscle, and giving a sheath to the internal pudic artery; the **inner wall** is the fascia covering the levator ani and external sphincter muscles; the **anterior wall** is formed by the base of the triangular ligament and transverse perineal muscle; the **posterior wall** is formed by the gluteus maximus, great sacro-sciatic ligament, and the coccygeus muscle.

The **Contents** of the space are—(1) Twigs of the small sciatic nerve; (2) the inferior hæmorrhoidal nerve; (3) the fourth sacral nerve—to the external sphincter; (4) the superficial perineal nerves; (5) inferior hæmorrhoidal vessels; and (6) much loose granular fat, which forms a movable elastic packing for the rectum.

Abscesses may form in this space; and unless they are early and freely opened, they will either burst into the interior of the gut, or spread widely upon the nates, being unable to “point” readily at the base of the space on account of the strong fascia covering it. They should also be opened early, because they cause great suffering, both from tension and pressure on the nerves of the space. In opening abscesses of any kind in this region, the knife should be directed so as to cut towards the anus, parallel with the radii of a circle of which the anus is the centre, to avoid, as far as possible, division of the vessels and nerves of the space, which radiate towards the anus. Another reason why it should radiate towards the anus is that when the finger is introduced, if it be found to have almost entered the gut, the incision should be extended and the operation for the radical cure of fistula in ano performed.

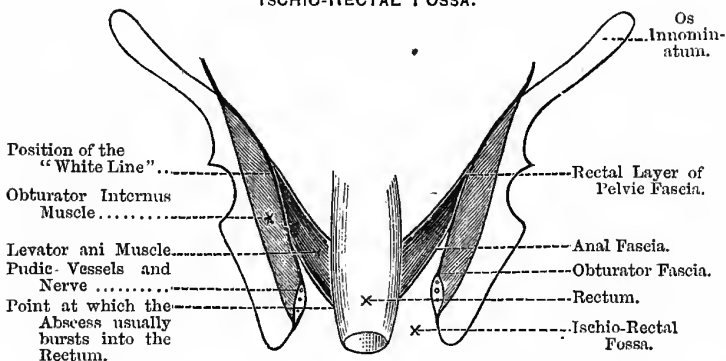
This space is also concerned in the various forms of **Fistula in Ano**, which frequently arise from abscess in this region; and in the complete form of fistula the structures between it and the rectum must be divided, so as to lay the two cavities into one, before a cure can be effected.

In this operation the **Structures divided** are—(1) The integumentary coverings, (2) the sphincter ani and wall of the rectum, (3) fatty tissue, and (4) small blood-vessels and nerves. As the great cause of persistence of this fistula is the constant movement of the parts, the section of the sphincter paralyses this movement, and gives the parts rest. Abscesses in the anal region may also begin just under the skin over the base of the space, or beneath the mucous membrane of the bowel: fistula in ano is sometimes caused by malignant disease of the rectum and tertiary syphilitic ulceration. It is worthy of notice, too, that fistula in ano is very frequently associated with **phthisis**—perhaps due, in the first instance, to the excessive coughing. In rapidly advancing phthisis, where the fistula has a large, ragged orifice and undermined edges,

and the local condition is only of secondary consequence, it is probably better not to operate for the cure of the fistula, but rather simply to treat the constitutional cause; but otherwise, phthisis is no objection, as experience shows that getting rid of a suppurating tract has a beneficial effect on the person suffering from phthisis. But, of course, we must make sure that we have got rid of it—that it is *soundly healed*—as otherwise the tubercular matter under pressure will be absorbed and make matters worse; it is possible, therefore, that an open sore is a safeguard, only there is the additional risk from the entrance of septic organisms. These fistulae usually open into the bowel from half-an-inch to an inch

Fig. 214.

ISCHIO-RECTAL FOSSA.



and a half above the anus, or just above the sphincter, no matter in what part of the fossa the abscess arises. This is because of the anal fascia which coats the levator ani, and which resists the passage of the abscess towards the rectal wall, so that the pus passes down by the side of the fascia, and perforates the rectal wall just above the point where the anal fascia joins it (Fig. 214).

An ischio-rectal abscess tends to open both ways—into the gut, and externally. When this takes place it is called a *complete fistula*; when it has only an internal opening, it is called a *blind internal fistula*; and when it has an external opening only, it is called a *blind external fistula*. The treatment for the incomplete

forms is to make them complete, and then lay the anal and abscess cavities into one. In cases of hæmophilia, the *elastic ligature* is used for this purpose. The abscess sometimes burrows round the rectum, in a horse-shoe fashion, before it opens into it. The complete form is the most common, and is usually from some irritation in the bowel; the incomplete forms are usually from constitutional causes. Mr BELL says that ischio-rectal abscess and fistula are most common just after the 12th of August, from swallowing grouse bones, which then stick about the rectum, and cause abscess and complete fistula. Two early and troublesome signs of *fistula* are the involuntary passage of flatus at awkward times, and soiling of the linen. The ischio-rectal fossa is also opened into in the operation of lateral lithotomy.

Abscesses near the Rectum.—The various forms of abscesses met with in this neighbourhood are:—

1. Marginal, in the cutaneous folds surrounding the anus, and therefore quite superficial, and probably due to some local cause—*e.g.*, piles.
2. True ischio-rectal abscess, tubercular in nature usually, depending for its origin on the constitutional dyscrasia. Very often incomplete, opening into the gut only. It is more difficult to treat, and the prognosis much worse than in the purely local forms of abscess and fistula.
3. Abscess internal to the sphincters, lying between the muscular and mucous coats of the bowel, and opening into the rectum above the internal sphincter; this usually arises, in healthy men, from some local cause, and is very amenable to treatment when the local cause is removed. This form is not in the ischio-rectal fossa at all.
4. Peri-rectal abscess in the cellular tissue surrounding the gut (*peri-proctitis*). Should it arise above the level of the visceral pelvic fascia, we get a condition corresponding to pelvic cellulitis in the female. In the male, such abscesses often spread up along the vas deferens to the inguinal canal, and there form what is usually known as "**Abscess of the Cord.**" They are

known by the history of the case—signs of inflammatory fever, *with rigors*; and when the abscess is opened, by the very fetid odour and brownish colour of the pus.

The Anterior or Urethral Part.—It will be well here to say a few words about the *triangular ligament* of the urethra, or deep perineal fascia; it is sometimes called the "*suspensory ligament of the urethra*" (MACLEOD), or the "*urethral ligament*" (CHIENE). This is a ligament which fills up the pubic arch, and is, therefore, triangular in shape—hence its name; it divides the urethral triangle into superficial and deep parts. The urethra pierces it, but the penis is entirely in front of it, and the bulb lies in contact with its anterior surface. The so-called "posterior layer" of the triangular ligament is simply a part of the parietal layer of the pelvic fascia attached to the posterior lips of the margin of the pubic arch, and below to the base of the true triangular ligament. By this means there is a small space enclosed, which is spoken of as the "space between the two layers of the triangular ligament." In the dissection of this part of the perineum, after having reflected the skin, we come to the superficial fascia—in this region it has been divided into a superficial and a deep layer; but these two layers are practically one, only the layer has two distinct surfaces. This fascia is sometimes called the *Fascia of Colles*.

Extravasation of Urine.—This may be caused by a rupture or wound of the urethra, as falling on a rail with the legs apart, a kick in the perineum, retention from a tight stricture, or perineal abscess behind a tight stricture. It may also complicate fracture of the pelvis. In cases of retention from a tight stricture, the mucous membrane ulcerates, and when the patient is straining with great force the urethra suddenly gives way, and the urine is rapidly extravasated; if it ruptures in front of the bulb, urine is effused into the erectile tissue, and may cause gangrene of the penis, beginning in the glans. In cases of abscess the pus opens into the urethra, and urine passes into the abscess cavity, and if not opened externally will tend to diffuse itself widely in the tissues of the perineum. The fascia concerned in this accident is thus attached—**Laterally**, it is attached to the margins of the pubic arch, as far back as the tuberosities of the ischia—beyond

this it is firmly blended with the fascia lata of the thigh; **behind**, it bends round the transverse perineal muscle, and is attached to the base of the triangular ligament of the urethra; in **front**, it is unattached, and is continuous with the fascia of the scrotum and penis; and in this way a pouch is formed, which is open *above*, in the interval between the symphysis pubis and the pubic spine. From the median line an incomplete septum projects downwards towards the urethra and into the scrotum. From the above attachments, it is evident that the extravasated urine cannot pass backwards into the posterior half of the perineum—that is, the posterior half of the *anatomical* perineum, or ischio-rectal fossa—because of its attachment to the base of the triangular ligament; nor down the thighs, because of its attachments to the pubic arch and fascia lata of the thigh; but it will fill the pouch and pass into both sides of the scrotum, and then pass up the front of the abdomen, along the spermatic cord: and even when it has reached the abdomen it is still unable to pass down the thighs, because the deep layer of the superficial fascia of the abdomen is firmly attached to **POUPART'S** ligament, nor can it pass the linea alba for a like reason.

In cases also of "**perineal abscess**" the pus spreads in this same fascial compartment, and during the acute stage causes great suffering, both because of the dense fascia, and also pressure upon the three long scrotal nerves which lie in this "pouch."

To treat this condition a *free and deep incision* should be made in the middle line of the perineum, from the lowest part of the perineal swelling forwards to the root of the scrotum; some, instead of making a single median incision, make two lateral incisions. Similar incisions must also be made into the scrotum, in the middle line of the abdomen, and along **POUPART'S** ligament, if necessary, and, in fact, wherever the urine has infiltrated; the finger also should be introduced into the incisions and septa broken down, so as to ensure free drainage. Over all place a large charcoal poultice.

Thus far in the dissection we have simply removed—(1) The skin; (2) the superficial fascia; and when the pouch above mentioned is opened into, we come to (3) the long scrotal nerves—(a) anterior superficial perineal, (b) posterior superficial perineal,

(c) the long pudendal; (4) the blood-vessels—(a) the superficial perineal artery, (b) the transverse perineal artery. These structures being reflected, we then expose (5) the superficial muscles of the space, three in number, which form a small triangle (the perineal triangle), the floor of which is formed by the triangular ligament. The muscles are—(a) The accelerator urinæ, lying on the penis; (b) the erector penis, lying on the crus penis; and (c) the transversus perinei. When these are removed, (6) the bulb (the dilated posterior part of the corpus spongiosum) and root of the penis are exposed; and if they in turn be removed, (7) the anterior surface of the triangular ligament is exposed. (8) Remove the anterior layer of this ligament, and the structures **between its two layers** are exposed, viz.—(a) the membranous part of the urethra, surrounded by (b) the compressores urethræ (GUTHRIE'S muscle), (c) the artery to the bulb, (d) the internal pudic artery, (e) COWPER'S glands, (f) the pudic nerves, (g) the dorsal vein of the penis, and much compact cellular tissue. Reflect these structures and cut through (9) the posterior layer of the triangular ligament, and (10) reflect the levator ani, and the prostate gland is exposed, surrounded by its capsule and the prostatic plexus of veins; and if the rectum be turned aside, (11) the base of the bladder, with the vesiculæ seminales and the vasa deferentia are exposed. There are various structures which **pierce the anterior layer** (that is, the *true* triangular ligament) of the triangular ligament, viz.—(1) the urethra, in the median line, one inch below the pubes; (2) the dorsal vein of the penis, also in the median line, half-an-inch below the pubes; (3) the internal pudic artery; (4) the dorsal nerve of the penis; and (5) the artery to the bulb—this vessel lies about half-an-inch above the base of the ligament, and an inch and a half in front of the anus. COWPER'S glands are a little to one side of the middle line, and therefore, when they are inflamed, as during an attack of gonorrhœa, the swelling, and probably suppuration later, will not be median, but to one side of the middle line.

Professor CUNNINGHAM points out an interesting thing about this dissection, viz.:—that, from the surface to prostate, we meet with an alteration of muscular and fascial strata, thus—

1. Superficial fascia.
2. *Superficial perineal muscles.*

3. Triangular ligament.
4. *Compressor urethrae muscle*.
5. Parietal pelvic fascia, or posterior layer of triangular ligament.
6. *Levator ani muscle*.
7. Capsule of prostate and pubo-prostatic ligament.

In relation to the subject of extravasation of the urine from rupture of the membranous part of the urethra (which is said to be the usual seat of traumatic rupture), it is difficult to see how the urine can spread as it does, because the space between the two layers of the triangular ligament, where the membranous urethra is situated, is practically a closed membranous box. But when a patient falls, and is caught by a beam in the "fork," it is anatomically impossible that the *membranous urethra* could be ruptured. This portion of the urethra stops at the anterior layer of the triangular ligament, and this ligament is not at right angles to the surface of the earth, but almost *parallel* with it, and therefore, in falling, its whole anterior surface, and not its edge, would strike the beam, and the part jammed between the beam and the pubes is the bulbous portion of the urethra, and hence there is no difficulty at all in understanding the course of the extravasated urine. In *fractures* of the pelvis, however, it is the *membranous urethra* that is torn, and hence the extravasated urine is confined in the space between the two layers, and between the pubes and the bladder, and does not present the usual well-marked and characteristically-shaped swelling.*

I saw a beautiful example of this fact in a case of Dr CAIRD'S. The case was one of rupture of the urethra, due to lateral compression of the pelvis, and the catheter could only draw off a *limited* amount of fluid from the space between the two layers of the triangular ligament and behind the pubes, and which was evidently being filled from time to time from the bladder. Dr CAIRD cut down in the middle line in order to find the divided ends of the urethra, and when it was reached the finger could be passed into a cavity behind the pubes in front of the bladder, and which had evidently no connection with the "pouch" in the perineum.

* In relation to this subject, see a Paper by Dr AXEL IVERSEN.

The case could not be verified by dissection further than during the progress of the operation, as the young lad is now perfectly well except for a slight traumatic stricture. In cases where a patient receives an injury to his perineum, and this is followed by a discharge of blood from the urethra, independently of micturition, there is every reason to suspect a complete or partial rupture of the urethra. An exception to this rule will be found in cases of rupture of the vas deferens.

From a fall in the "fork," therefore, the urethra usually ruptures a little in **front** of the triangular ligament, through the spongy part of the urethra; very frequently the rupture is only partial. The signs are rapid swelling in the perineum from blood and urine, should the patient attempt to pass water, difficulty in passing urine, or complete "retention," and the passage of blood from the meatus.

Rupture of the membranous urethra is usually secondary to fracture of the pelvis, blood rarely flows from the meatus, rather passing backwards into the bladder, and there is no primary swelling in the perineum. The urine passes behind the pubis and through the weak anterior part of the pelvic fascia into the sub-peritoneal cellular tissue, giving rise to abscess that may perforate the peritoneum, or descend by the side of the rectum, and point at the anus (IVERSEN). If the attachment of the pelvic fascia to the rami of the pubes and ischium be split, the urine may find its way into the adductor region, and there give rise to abscess.

Various plans of treatment are open to the Surgeon—(1) He may be able, by keeping its point against the roof of the urethra, to pass a catheter into the bladder, as the rupture is very often only partial; the catheter is then left in the bladder. (2) In cases where he cannot pass a catheter, he may cut down in the middle line of the perineum, find the rent, and then pass a soft catheter into the bladder, and leave it in for eight or ten days. (3) If it even then be impossible to find the proximal end of the torn urethra, a supra-pubic cystotomy should be performed, and then, by the aid of posterior catheterisation, an instrument can be passed along the urethra into the bladder. (4) In case of rupture complicated with fracture, BELL gives the following advice:—

Do not catheterise, but tap the bladder above the pubes with the fine needle of the aspirator, and repeat the procedure every eight or twelve hours for at least ten days.

The Anterior Space in the Female.—In the female there is situated in this space the orifice of the vagina, and the parts connected with it—the true perineum in the female being that part between the posterior commissure of the labia and the orifice of the anus, and is from an inch to an inch and a half in length. A work of this kind is not quite the place to take up the subject of development; still, a few words on it will not be amiss, in order to trace out the homologous parts in the two sexes. Up to the seventh or eighth week of foetal life, in both sexes, the genital, urinary, and intestinal tubes open into a common opening, or cloaca, a condition which is permanent in reptiles and birds. About this time a transverse partition forms, dividing this cloacal aperture into an anal or posterior division, and an anterior division, called the *uro-genital sinus*. From the part of this sinus lying above the opening of the Wolffian duct in the male, and the Müllerian duct in the female, the prostatic portion of the male urethra, and the *whole* of the female urethra, is developed; the part below this, forms the vestibule in the female, and the membranous part of the urethra in the male. The uro-genital sinus is, however, further sub-divided by a fold forming in the antero-posterior direction, called the *genital eminence*, and which ultimately forms the penis in the male and the clitoris in the female. The under surface of this body is cleft, and is further bounded by two folds, which in the male grow down and close in the furrow, forming the corpus spongiosum of the penis; but in the female they remain open, and, diverging from each other, form the nymphæ or labia minora. At the sides of the sinus other integumentary folds arise, which in the male join to form the scrotum; but in the female they remain open, and form the labia majora. In the male, the small prostatic pouch or *sinus pocularis*, seen in the prostatic portion of the urethra, is the homologue of the vagina and uterus in the female. This space further differs from the corresponding space in the male—(1) Because the superficial fascia, owing to the position of the vulva, is divided in the middle line, and becomes continuous with the sheath of the vagina;

(2) situated between the orifices of the vagina and the anus, is a structure known as the "**perineal body**," which corresponds in position to the central point of the perineum, but contains much elastic tissue; (3) the two halves of the muscle, corresponding to the accelerator urinæ in the male, are separated by the vulva, forming the bulbo-cavernosus muscle or sphincter vaginae; and (4) the vagina pierces the triangular ligament of the urethra. From the above it is evident that we cannot get "extravasation of urine," as in the male.

Nerves of the Perineum.—The **Pudic Nerve** supplies, by its inferior hæmorrhoidal branch, the skin around the anus, and communicates with the long pudendal nerve; the anterior and posterior divisions of the perineal branch supply the skin of the ischio-rectal fossa, the scrotum, and under part of the penis, and sends filaments to the levator and sphincter ani. The **Dorsal Nerve** of the penis supplies the integument of the upper part and sides of the penis and prepuce. The **Muscles** supplied by the pudic nerve are—(a) *Transversus perinei*, (b) *accelerator urinæ*, (c) *erector penis*, and (d) *compressor urethræ*. The pudic nerve also supplies the mucous membrane of the urethra. These communications of the pudic nerve explain the painful erections (*chordee*), and the spasm of the urethral wall in cases of acute inflammation of the urethra. The fourth sacral nerve is distributed to the viscera of the pelvis, notably the neck of the bladder, and joins the hypogastric plexus of the sympathetic; it also supplies the levator ani, coccygeus, sphincter ani, and skin between the anus and the coccyx. This nerve is the one chiefly affected in cases of "fissure of the anus," more especially its branch to the sphincter ani, which also gives twigs to the skin about the anus. The **Inferior or Long Pudendal Branch** of the small sciatic curves forwards below the tuber ischii, pierces the fascia lata, supplies the skin of the scrotum, and communicates with the superficial perineal and the inferior hæmorrhoidal nerves; other branches of the small sciatic supply the skin at the upper and inner sides of the thigh, towards its posterior aspect. It will be observed, therefore, that the anus and urethra, with their muscles, are practically supplied by the same nerve, and this explains why they are so frequently involved together, and why disease of the one reacts on the other—*e.g.*, operations on the

rectum causing retention of urine. Mr HUTCHINSON relates a case where permanent incontinence, both of fæces and urine, with entire loss of sensation in the passages concerned, followed the crushing operation for piles.

The **depth** of the perineum varies with the amount of fat present. It is deeper towards the posterior part, and more shallow towards the front. Posteriorly it varies from two to three inches, while in front it may be less than an inch.

CHAPTER XLI.

THE PELVIS.

LITHOTOMY.

The Lateral Operation.—The instruments required are as follows:—

1. **Sounds** of various kinds. The usual sound is a solid steel instrument, shaped like a catheter, but with a shorter curve, so that it may readily examine all parts of the bladder, especially the part behind the prostate; the handle is flattened, and the point slightly bulbous. Sir HENRY THOMSON'S sound is hollow, and has a round handle; it is thus more easily managed during rotation, and may be used either to inject or draw off the contents of the bladder. In some cases the sound is so constructed that a "sounding-board" can be attached to its end, in order to intensify the sound when a stone is struck.

2. An eight-ounce, or HIGGINSON'S, **Syringe**, with a catheter for injecting the bladder (unless the hollow sound be used), and a tube for washing out the bladder through the wound, after the operation, by a reversed current.

3. **Staffs**, as large as the urethra will admit, with as deep and wide grooves as possible on the left hand side; the groove must stop half-an-inch from the point, and must not extend too far up the handle, lest urine escape during the operation. It may be straight (KEY), or curved (CHESELDEN), or rectangular with a sharp angle (BUCHANAN), or a rounded angle (CHIENE). In cases of enlarged prostate, CHESELDEN'S staff is better than BUCHANAN'S, because, when the angle is in the membranous urethra, the point may not be in the bladder, and if the horizontal limb be too long, it is very difficult to introduce. Professor CHIENE'S staff, with a specially long horizontal limb, however, can readily be introduced

and used, as the angle is rounded. The broad part of the handle should be roughened, especially the side towards the concavity of the staff.

4. **Knife**, with a large handle—for the adult, say about four and a half inches. The blade is about three inches long, and does not cut to the heel, the cutting edge only extending about an inch and a quarter from the point. The blunt part is to allow the finger to be placed below the blade, to press and keep the knife in the groove of the staff during the second part of the incision. It should be bevelled off at the back near the point, so as to enable it to glide easily along the groove of the staff. A probe-pointed knife, with blunt heel, is sometimes used to enlarge the deeper part of the wound before the stone is extracted. ASTON KEY uses a straight staff at the latter part of the operation. BUCHANAN uses a rectangular staff; the angle is felt in the perineum, and the knife cuts straight down upon it, and then along the *straight* groove into the bladder. In Professor CHIENE'S staff (Fig. 215), the two parts are almost at right angles to each other; but the angle is not sharp but rounded, so that it possesses the advantages of both the ordinary and the rectangular staff—ease of introduction and less risk of the knife slipping out of the groove. For the ordinary CHESELDEN staff, probably FERGUSSON'S knife is the best; but for PROFESSOR CHIENE'S or BUCHANAN'S staff, LISTON'S knife is better. For the first part of the operation, the knife is held under the hand; in the second part, LISTON held it above his hand.

5. **Blunt Gorget**, probe-pointed, with blade about four or five inches long. This is sometimes useful as a director and safe guide for the forceps, and for dilating the already cut wound, and may be used in cases where the finger cannot reach the bladder, as in enlarged prostate, and in a fat person with a very deep perineum. Sharp gorgets, formerly much used for cutting the deeper part of the wound, are now discarded.

6. **Forceps** of various sizes, straight or curved, to suit the axis of the pelvis; the blades, when closed, should be about an eighth of an inch from each other. The curved pair may be required in cases where the prostate is enlarged, and the stone in the pouch behind it. The handles have a ring on one side, and a hook on the other; the ring is for the thumb, the hook for the fingers.

Fig. 215.

PROFESSOR CHIENE'S STAFF.

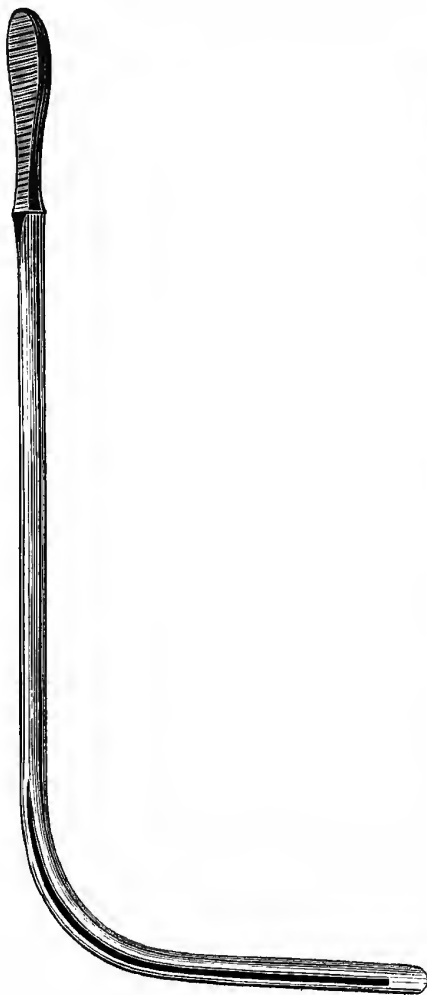


Fig. 216.

LITHOTOMY TUBE.



7. Scoops.

8. **Searcher**, specially made for such, or else use an ordinary sound.

9. It may be sometimes necessary to have some means present for crushing the stone.

10. A pair of **Lithotomy Tapes**, of worsted or coarse flannel, three yards long, and three inches broad; or leather anklets and wrist-bands may be used.

11. A silver or gum elastic **Rigid Tube**, well rounded at the end, and provided with rings, whereby it can be tied into the bladder, with or without "petticoats." There are also specially made "air tampon" tubes for the same purpose. The tube with the petticoat or air-bag is specially adapted for plugging the wound in cases of deep venous hæmorrhage; and being *rigid*, the walls of the tube are not squeezed together, so that the urine and discharges can still pass freely through. This tube is not to drain the wound, and must therefore only have holes at its ends; and besides, lateral holes would allow the urine to flow out and soak the raw surface of the wound (Fig. 216).

12. **Catch forceps**, tenacula, ligatures, sponges, lint, morphia suppository (half-grain), towels, etc.

In all forms of perineal lithotomy, the object in view is to make an opening into the bladder, large enough to admit of easy extraction of the stone without opening up the visceral pelvic fascia, with the least risk to the pudic artery or its branches, and without injury to the rectum.

Assistants.—Three special assistants are required—**one** to steady and abduct each knee, and a **third** to hold the staff and pull the scrotum up out of the way. This assistant stands on the left side of the patient, close behind the assistant holding the left knee; he is also to grasp both scrotum and penis with his left hand, and pull them up, for by so doing he not only holds the scrotum out of the operator's way, but by stretching the penis, he also draws up the bulb, which is thus less likely to be wounded, and increases the space between the urethra and rectum. The **Surgeon** is seated on a low stool facing the patient's buttocks, so that when operating his fore-arms are almost on a level with the patient's perineum, which should be perpendicular. The instruments are arranged in

a convenient manner on a tray within easy reach, or else committed to the charge of an assistant.

Before operating, the patient should be kept quiet for a week or ten days, and his general health and secretions carefully attended to. The bowels must be opened the previous day by means of an aperient. The left side of the perineum may also be shaved, as this will save trouble on the morning of the operation, or this can be done with less unpleasantness to the patient after he is under chloroform and tied up. On the morning of the operation, the rectum must be emptied by an enema of warm water, administered two hours or so before the operation; it is necessary to see that it acts properly before the operation, lest it act when the patient is on the table, and besides, a distended rectum adds greatly to the risk of the operation. A loose circle of bandage may also be fastened round the pelvis, to which the tapes of the tube are fastened after the operation is finished. The urine is allowed to collect for an hour or so before the operation, or else five or six ounces of tepid carbolised water must be injected after the urine is drawn off, as one can then know exactly how much fluid is in the bladder. The patient being now placed on the table, an anæsthetic is administered, the sound passed, and the *stone struck*, the "click" being heard both by the operator and his assistants. If the stone is detected, he proceeds with the operation, but if he cannot detect it, the operation *must* be abandoned for that day at least; for the law is, that this operation must never be performed unless the stone can be felt when the patient is on the table, and this law, like the laws of the Medes and Persians, altereth not.

In *sounding*, the patient lies on his back upon a hard mattress or table, with his buttocks raised by means of a pillow, so as to displace the stone from the pouch behind the prostate, and the bladder moderately distended with urine, or, better, draw off all the urine and inject a measured quantity of warm boracic lotion. The Surgeon at first stands on the patient's left side till the sound has entered the bladder; after this he may change to the right side, as he can then more easily work the sound with the right hand, while the left hand is free for the rectum. A full-sized sound, well warmed and oiled, is then allowed to enter the bladder by its own weight. In *sounding*, the bladder should at first be moderately full, and then,

if no stone be found, the water should be drawn off and the viscus examined empty; for this reason a hollow sound should be used in preference to a solid one. When it has entered the bladder, the point is first directed to the deepest part of the bladder where the stone usually lies, and made to move gently from side to side, then from before backwards; it is next rotated slightly with the beak downwards, and the handle gently depressed between the patient's thighs, so as to examine the floor and sides of the bladder and the part immediately behind the prostate; the sound is moved slowly along the floor and sides, and gently twirled from side to side in the meantime, so as to examine every part in a regular methodical manner. The handle may be depressed still further, and the beak turned upwards, so as to examine the pubic portion of the bladder wall. The usual positions of the stone are—(a) At the right side of the neck of the bladder; (b) at the fundus, near one or other ureter; (c) in the pouch behind the prostate, especially in old men; and (d) more rarely, in a pouch under the pubes, or in the posterior and upper wall: in the child, as the bladder is an abdominal organ, it may be caught above the pubes. If the sound alone cannot detect the stone, then try with the finger in the rectum; and if still unsuccessful, draw off the water and try the empty bladder. The stone may be missed if it lies in the pouch behind the prostate or above the pubes in the child, or if it lies in one of the recesses of a sacculated bladder. A lithotrite makes an excellent sound, as one is better able to measure the stone or judge of its hardness by the bite of the lithotrite, and also of the number present. Other points to be noted in sounding are—the expulsive power of the bladder as the water is drawn off, and the capacity of the bladder when the boracic acid is injected; and the state of the prostate, by the direction and distance the sound travels, aided by the finger in the rectum; and also, of course, the presence or absence of stricture of the urethra. I ought to mention that some Surgeons use a flat piece of wood, stuck on to the end of the sound, to act as a sounding-board and intensify the “click” of the stone. A stone may be thought to be present when it is not, by the sound clicking against a ring on the operator's finger, or its point rubbing against a projecting third lobe, or projecting rugæ, coated with phosphatic deposit.

The stone having been felt by the staff, the patient must then be firmly tied up in the usual lithotomy position, and during the manipulations necessary for this purpose, the staff must not be allowed to slip out of the bladder. He is tied up by making a clove hitch in the tape and passing it round the wrist with the knot in front, so that the arteries of the fore-arm are not pressed upon, after which the palm of the hand is laid against the under and outer surface of the patient's foot, and fastened there by the ends of the tape being passed in a figure-of-eight round the ankle, instep, and hand, and firmly tied. The patient is then moved downwards to the end of the table, so that his buttocks project slightly over its edge, and a sheet of Mackintosh placed under his buttocks, and at the upper end pushed *between his skin and shirt*. Each leg is firmly held by an assistant, who faces the operator, placing one hand on the inner side of the patient's knee, which is placed under his arm, while with the other the foot is grasped and drawn backwards and outwards, the sole of the foot resting on the palm, and the fingers passing round its inner side. The staff assistant stands on the left side, behind the other assistant; the staff must be held very steadily, exactly in the middle line, and at right angles to the long axis of the patient's trunk, and hooked vertically upwards against the under surface of the pubes, for reasons already stated. This steadies the staff; the surface of the staff nearest the operator rests against the palmar surface of the assistant's fingers, while the palmar surface of his thumb presses against the broad roughened part of the handle. It will further contribute to greater steadiness if the elbow of that arm be allowed to rest *lightly* on the patient's thorax; this must not be done to such an extent as to impede the respiratory movements of the patient. The staff must on no account be allowed to tilt either towards or from the abdomen. If it is tilted towards the abdomen, then its point leaves the bladder, and, of course, the knife cannot enter it; especially is this the case in children, and in old men with enlarged prostates. It should always be kept *in contact* with the stone, if possible. If it be tilted towards the perineum, it enters the bladder too far, and there is a risk of the knife entering the posterior wall, and dividing the prostate too extensively.

The Surgeon now passes his finger into the rectum to ascertain the depth of the perineum, by feeling the apex of the prostate and membranous portion of the urethra, to see that the rectum is empty, and also to make it contract to its fullest possible extent, which will keep it out of the way. The fingers of the left hand are then laid on the left side of the perineum, to steady it while the first incision is being made. The knife is entered one-third of an inch to the left of the median raphé, an inch and a quarter in front of the anus, so as not to cut the artery to the bulb, and is carried downwards and outwards for about three inches to a point between the anus and the tuberosity of the ischium, but rather nearer to the tuberosity than it is to the anus. The deepest part of this incision should be towards the upper part, near the base of the triangular ligament, just between the erector penis covering the crus, and the accelerator urinæ covering the bulb, or fully a quarter of an inch from the upper end of the incision, and must become shallower and shallower as it passes downwards into the ischio-rectal fossa. The point of the knife should strike the staff as it lies between the "two layers" of the triangular ligament, in the membranous portion of the urethra.

In making this incision, Professor CHIENE keeps his finger in the rectum, all the time resting on the apex of the prostate, while he steadies the tissues outside with his thumb; there is no doubt but that by this means the depth of the perineum and the situation of the staff in the membranous urethra can be more easily kept in the mind's eye, and that, therefore, the first incision is more safely and correctly made.

By the first incision we divide—(1) The skin; (2) superficial fascia, opening into the pouch formed by the fascia of COLLES; (3) the inferior hæmorrhoidal vessels and nerves; (4) probably some of the branches of the long scrotal nerves; (5) the transversus perinæi muscle; (6) the lower border of the anterior layer of the triangular ligament; and (7) the membranous urethra surrounded by the compressores urethræ muscles. The left forefinger is then to be passed into the wound, to see that the staff is reached, and to protect the rectum if it is found necessary to enlarge or clear the incision to reach the staff; then the nail of that finger is placed in the groove in such a way that the dorsal surface of the finger

is turned towards the operator's right hand. The knife is then slipped along the upper surface rather of the finger, and its point pushed through the membranous urethra into the groove of the staff, while the finger protects and pushes aside the rectum. The blade of the knife is then inclined till it lies parallel with the rami of the pubes and ischium, the point being slightly above the level of the handle, and is then pushed steadily along the groove into the bladder, taking care not to depress the handle too much, lest the opening in the prostate may be made too large, nor elevating it, lest it slip from the groove altogether, *till its point is arrested by the termination of the groove*; when the ordinary staff is used, the angle between the knife and staff should be about forty-five degrees all through this second incision. The knife must be kept firmly pressed against the side and upper part of the groove, lest it slip out. Just as in ligature of arteries, the principle here is to make a free superficial incision, but a limited deep incision. The opening in the prostate may be enlarged as far as necessary when withdrawing the knife, by depressing the handle, only be careful to keep the back of the knife against the staff all the time. In the enlarged and indurated prostates of old men, a larger incision will be necessary than in young adults, as it will not dilate so easily. As the knife is withdrawn, the operator pushes his finger along the groove in the staff into the bladder—(a) to plug up the wound, and prevent the escape of fluid; (b) to feel the stone and judge its size, and turn it in the proper axis for the forceps; (c) to dilate the prostatic incision; and (d) to judge what size of forceps is most suitable.

The Structures divided in the second incision are—(1) The rest of the membranous urethra and the compressores urethræ muscles; (2) a few fibres of the levator ani (*levator prostatae*); (3) the left lobe of the prostate, and the prostatic portion of the urethra; (4) a dense ring which surrounds the prostatic urethra; and (5) the internal sphincter of the urethra (*sphincter vesicæ*). As soon as the finger feels the stone, the Surgeon asks the assistant to withdraw the staff. The forceps are then introduced, the finger already in the bladder acting as a guide; the blades are separated a little, so as to embrace the finger, upon the *dorsal* surface of which they are pushed through the prostate into the bladder as

the finger is withdrawn. SIR HENRY THOMSON directs that they should be passed along the palmar aspect of the finger, till they are fairly in the bladder. The blades are then opened, and the stone is usually caught, being carried between the blades by the first gush of urine. The method adopted by Mr CHIENE is extremely simple and effective:—The forceps being introduced, open the blades widely in the horizontal direction, turn them one-quarter of a circle, so that the handles now lie in the vertical direction, then close the forceps by lifting the *lower handle*, as this corresponds to the upper blade; by this means, if there be a stone present, it will be caught. The *lower blade* must not be moved.

If the stone be faceted, there will almost certainly be others present. Lastly, the searcher must be used to explore the whole cavity, and make sure that they are all removed. Small ones may be removed by the scoop, being grasped between the blade of the scoop and the point of the operator's finger. All bleeding arteries are then secured, the venous hæmorrhage usually soon stops of itself, but if not, the wound must be plugged. The wound is then washed out, the rigid gum-elastic tube tied in, the patient loosened and carried to bed. He is placed on a firm mattress, guarded by waterproof cloth, with the body so inclined as to favour the flow of urine from the wound; a warm draw-sheet is placed beneath his buttocks, which are to be smeared with vaseline, to prevent excoriation. Each knee, slightly flexed and abducted, should lie on a pillow. A special attendant must watch the wound and the discharges, and see that the tube does not become blocked up by blood clots. A dose of opium may be given if necessary. When the patient makes plenty of urine, this is always to be regarded as a very good sign. The diet should at first be non-stimulating, consisting chiefly of milk, with plenty of barley-water to drink. The urine passes, in the first instance, entirely through the wound, but after the first day it may pass several times by the urethra, because the inflammatory swelling closes up the hole in the prostate. After forty-eight hours it again passes entirely through the wound; about this time in the adult, and sooner in the child, the rigid tube is to be removed, as the sides of the wound will be glazed, so that there is no danger of urinary infiltration, and besides, if left longer, it is likely to become coated

with phosphatic deposit. The great use of the tube is to allow the wound to be plugged in cases of hæmorrhage; Mr BRYANT does not think a tube necessary, and does not use it at all. After eight or ten days it again begins to pass by the urethra, and in about three weeks after the operation it ceases to pass by the wound altogether. There is no risk of stricture following this wound of the urethra, because the incision is longitudinal, or in the long axis of the tube, and not transverse (DUNCAN).

In Boys, the operation differs somewhat from the same operation in adults. In the adult the bladder is easily opened into, but the difficulty is the removal of the stone; in boys, on the other hand, the stone is easily extracted, but the difficulty is to open into the bladder (CHIENE). It is rarely fatal in children, except from violence on the Surgeon's part, tearing through the membranous portion of the urethra. An objection urged against this method in boys is that it means emasculation. This is very doubtful; in any case, Nature provides him with two seminal ducts and vesicles, as well as two testicles. This difference depends upon the relative position of the bladder, and the size of the prostate gland in the child and in the adult. In the child the bladder is chiefly an abdominal organ, and is more movable than in the adult, and the prostate gland is not yet developed. See that the groove does not pass too far up the staff, or else the contents of the bladder escape along the groove, leaving the Surgeon to cut down upon an empty bladder, which is very dangerous, as one may readily pass between the bladder and the rectum. The staff, further, should be strongly curved. In making the second part of the incision, direct the knife a little upwards; and in introducing the finger carry it along the concave side of the staff, against the roof of the urethra, which is *fixed and rigid*. Mr HEATH introduces a strong director before the staff is removed, and then passes his finger along the director. It is not necessary to tie up a child in the usual manner, as the limbs can easily be held in position by the assistants. The staff must be *kept in contact with the stone from first to last*, till the Surgeon feels it with his finger. The cutting operation is usually preferred in boys under ten or fifteen years of age, though it has been shown that the crushing operation may be performed safely at a much earlier age.

When the patient is on the table, the order of events is the following:—

1. Administer chloroform.
2. Draw off all the urine in the bladder.
3. Inject four to six ounces of a warm boracic solution.
4. Introduce the staff, and strike the stone; and if felt—
5. Tie up the patient.
6. Shave the left side of the perineum.
7. Cut—
 - (a) *First incision*, down to the staff in the membranous urethra.
 - (b) *Second incision*, from this point into the bladder.
8. Remove the stone or stones.
9. Fix a lithotomy tube into the bladder.

The following Facts are worthy of Special Note:—In making the deeper incisions, the side of the knife should be kept parallel with the ramus of the ischium, because, if the edge be turned too much towards the mesial line, (1) the rectum may be wounded; and if the edge be turned too much outwards, (2) the internal pudic artery may be cut, which is bound down in a strong sheath of obturator fascia, under cover of the ramus and tuberosity of the ischium. It lies about three-quarters of an inch above the margin of the tuberosity. (3) The artery to the bulb, instead of coming off from the internal pudic, between the two layers of the triangular ligament, and running transversely inwards to the bulb, sometimes arises further back, and sometimes even in the ischio-rectal fossa. In this case it is almost certain to be wounded, and the accident is attended with considerable danger to life, from hæmorrhage, for three reasons—(a) From its size, and from the fact that it is cut (usually) near its origin from the parent trunk; (b) it is so deeply placed that it is almost impossible to apply a ligature; and (c) the fibrous nature of the tissues in which it lies at this point tends to prevent its contraction, and the consequent natural arrest of the hæmorrhage. The proper course is to enlarge the wound, and tie both ends of the bleeding vessel. (4) The incision into the prostate should be as limited as possible, lest the knife pass beyond it and cut through the reflection of the pelvic fascia from its sides and front (the point of reflection, however, is close

to the *upper* part of the prostate), forming the lateral and anterior true ligaments of the bladder, and thus open into the pelvic cavity, which accident is almost certain to be followed by infiltration of urine and diffuse cellulitis. (5) The bulb must be avoided. (6) If the knife be thrust too deeply in the last stage of the incision, the posterior wall of the bladder might be wounded.

In performing lithotomy in children, there are certain differences in the size and position of the parts concerned—(1) The urethra is proportionately larger; (2) the perineum is more vascular usually; (3) the rudimentary state of the prostate gland; (4) the bladder in children is situated much higher, being rather an abdominal than a pelvic viscus; and (5) if the point of the knife is not raised sufficiently in making the deep part of the incision, the bladder may not be entered at all, but the knife may pass between the bladder and the rectum, and in attempting to dilate the supposed wound, the neck of the bladder may be torn from the urethra. With these differences in mind, the operation is performed in the same way as in the adult.

In **Stone** in the bladder, pain is felt at the *end* of micturition, because the bladder contracts on the stone and forces it against the sensitive trigone; hence, when some urine collects again, the pain is relieved, because the bladder is raised off the stone.

In **Cystitis**, the pain is produced in a different manner—viz., by the contact of the urine with the inflamed mucous membrane, and is therefore relieved immediately after the act, as the irritant is removed, but begins again as soon as the urine begins to collect.

The pain felt at the end of the penis in stone, is because the prostatic plexus of nerves end just behind the glans penis. Many **kidney affections** simulate stone in the bladder, notably scrofulous kidney; but other conditions—either in the pelvis of the kidney, in its substance, or in the tissue around it—may give rise to similar symptoms. The pain in stone is increased by movement, showing that it is most likely due to a movable body. The student should remember that, in boys, all the signs of stone may be due to adherent prepuce. When the urethra is **inflamed**, the pain is worst *during* micturition. Simple inflammation of the neck of the bladder and prostate, abscess of the prostate, and tubercular disease of the prostate, may all closely simulate stone in the bladder, as

the *neck* of the bladder is inflamed; so also in hypertrophy of the prostate in old men, especially of the "middle" lobe. As the first part of the urethra lies in the prostate, it is very often inflamed in affections of that gland, so that there will also be pain during micturition to a certain extent.

THE MEDIAN OPERATION.

(THE OLD "MARIAN," OR THE "OPERATION OF THE APPARATUS MAJOR.")

In this case the incision is made in the middle line, in the space between the rectum behind and the bulb in front. A staff with a median groove is passed into the bladder, and the left index finger passed into the rectum, and made to touch and rest on the apex of the prostate gland. The knife is then entered with its edge *directed upwards*, half-an-inch in front of the anus, and its point so directed that it cuts a small part of the apex of the prostate and the membranous urethra; it is next made to cut upwards for a little way, opening the membranous urethra a little more fully. A ball-pointed probe is then passed along the staff into the bladder and the staff withdrawn. The finger is now introduced and the prostate gland dilated sufficiently, if this be possible. This operation has been characterised as, "small incision, much dilatation;" but it is doubtful whether it is altogether "dilatation." After dilatation is completed, the stone is extracted by the forceps.

The **Structures divided** are—(1) Skin and superficial fascia; (2) sphincter ani; (3) the central point of the perineum and the structures meeting there; (4) the lower edge of the triangular ligament; (5) apex of the prostate; and (6) membranous urethra, surrounded by (7) the compressores urethræ muscles.

Advantages—(1) It is said to be more easily performed. (2) There is less bleeding, as it is in the median raphé, and there is no risk of cutting the artery to the bulb. (3) It is said to be *impossible* to open up the visceral layer of the pelvic fascia, as it is dilatation, not cutting; there is less injury to the lateral ligaments of the bladder.

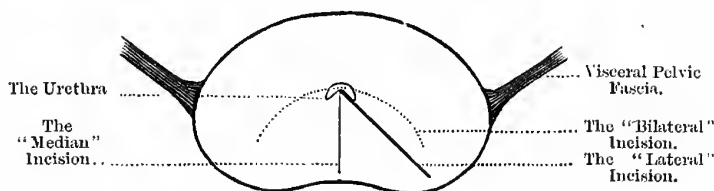
Disadvantages.—(1) Danger of wounding the bulb, and (2) danger of wounding the rectum—both greater than in lateral. (3) The

space is small, and it cannot be used for large stones; the dense ring which surrounds the urethra prevents great dilatation, both in the prostate and at the neck of the bladder, and laceration of this ring is very dangerous. (4) It cannot be used in the child, as probably the neck of the bladder would be torn from the urethra during the "dilatation;" and besides, there is practically no prostate in the child. (5) The incision is not made in the longest diameter of the prostate (Fig. 217).

It is recommended—(1) In cases of foreign bodies in the bladder; (2) in cases of small stone, less than one inch in diameter, where "crushing" cannot be used—*e.g.*, as for cystitis; (3) in cases of numerous small stones, or after lithotripsy, where fragments are left; and (4) in cases where loss of blood is a

Fig. 217.

THE PROSTATE IN LITHOTOMY.



serious matter to the patient. An almost similar operation may be used for prostatic calculi or prostatic abscess.

The Bilateral Operation (DUPUYTREN).—In this operation a curved transverse incision is made half-an-inch above the anus, towards which its concavity looks, the extremities of the incision extending for about two-thirds of the distance between the anus and tuber ischii on each side. By this incision there are divided—(1) Skin, (2) superficial fascia, (3) superficial nerves of the perineum, (4) superficial vessels of the perineum, (5) the superficial muscles of the perineum (see "Dissection of the Perineum"), and (6) membranous portion of the urethra and the compressor urethræ muscle. Into this opening the double *lithotome cachée* is introduced and passed into the bladder along a grooved median staff, with its concavity upwards; but when once in the bladder, the concavity is turned downwards, the spring in the handle is pressed, and the

blades, previously "set," are made to cut their way out in withdrawing the instrument. Through the opening thus made in the prostate the stone is extracted.

Irregularities of the Vessels met with in Lateral Lithotomy.*

I. Internal Pudic.—(1) It may come directly from the internal iliac, pierce the visceral layer of the pelvic fascia, run along the *lateral* lobe of the prostate, and there divide into three branches—(a) the dorsal artery of the penis, (b) one to the crus, and (c) one to the bulb, which runs along the *membranous part of the urethra*, and is pretty certain therefore to be divided in the operation, if it is found on the *left* side.† (2) A case somewhat similar is described by Dr ALLEN THOMSON. The vessel at first lies between the bladder and the rectum, then on the side of the prostate, and crosses the *membranous portion* of the urethra obliquely, below the visceral fascia, to gain the sub-pubic arch; were this present on the left side, it would be cut in the lateral operation. (3) Mr SPENCE also describes a case where a vessel arose from the internal iliac in common with the obturator, and reached the sub-pubic arch by passing along the *upper* surface of the prostate; this variety would be in no danger of injury during the operation. A similar course is sometimes pursued by the dorsal artery of the penis; it passes along the lower and lateral wall of the bladder, then across its neck, *above* the visceral layer of fascia, over the *upper* surface of the prostate, and leaves the pelvis by passing between the anterior true ligaments of the bladder; this vessel would also be quite safe, as it is above the visceral layer of fascia, unless the incision divides this layer and opens up the upper surface of the capsule of the prostate, which it should never do.

II. The Inferior Hæmorrhoidal.—This vessel leaves the pudic opposite the tuber ischii, and divides into several branches, which pass across the base of the ischio-rectal fossa; sometimes it does not divide thus, and then the *trunk* is cut in making the first incision, and bleeds profusely, both from its size and also because

* See article by the late Professor SPENCE, in the "Edinburgh Monthly Medical Journal," for March 1841.

† This specimen is preserved in the Anatomical Museum of the University of Edinburgh.

it is divided near the parent trunk and may retract within the fascia; in old people, too, the coats are often so diseased that they will not hold a ligature. Mr LISTON mentions a fatal case due to this cause.

III. The Superficial Perineal Artery.—This vessel arises from the pudic, a little anterior to the last, and, after giving off the transversus perinei, passes to the scrotum along the erector penis. Sometimes the vessel lies directly in the line of the incision and is necessarily divided; it is not likely to give rise to trouble, however, unless it is divided close to the parent trunk.

IV. Artery to the Bulb.—This artery usually arises from the pudic, about fourteen lines* in front of the anus, passes across the perineum between the two layers of the triangular ligament to the bulb. The incision is begun as far forward as this (*an inch and a quarter, or an inch and a half in front of the anus*), and one would think, therefore, that it should be cut during the ordinary operation. Mr SPENCE believed that it was frequently cut, but that it did not give rise to trouble because it was divided so far from its origin—provided that it was really *cut*, not merely *wounded*. (1) The vessel has been known to arise as usual from the pudic, pass directly backwards to near the anus, and then curve up to gain the bulb (SPENCE). (2) It may also come off from the pudic, posterior to its usual origin, and pass across the triangular ligament to the bulb. (3) It may also arise from an irregular pudic, and run along the membranous part of the urethra to the bulb (see previous page). Should such irregularities exist on the left side, the vessel will probably be divided, but from no fault on the part of the Surgeon. (4) Mr SPENCE mentions another case, where the pudic gave off no artery to the bulb, and where this vessel came from the anterior division of the internal iliac, passed along the side of the bladder, and upon the upper surface of the prostate, pierced the *left* true ligament of the bladder, crossed the membranous part of the urethra obliquely, and then entered the bulb.

V. Prostatic Artery.—This artery may come directly from the internal iliac, arise in common with the vesical, or come from the

* 12 lines = one inch.

pelvic portion of the pudic; it usually pierces the visceral layer of fascia, and lies on the side of the prostate, there dividing into branches which supply this gland and the neighbouring part of the rectum; in this case, it is not likely to cause trouble. Sometimes, however, the vessel gains the perineal aspect of the prostate *without dividing into branches*, and may be fully as large as the artery to the bulb, and would give rise to great trouble if divided. This irregularity is nearly three times as common as the dangerous forms of irregular artery to the bulb. It would be well, in *all* cases of perineal lithotomy, to make a careful examination of the prostate and membranous part of the urethra from the rectum, especially on the *left* side, as it might be possible to detect the pulsation of the dangerous forms of irregular arteries to the prostate and bulb.

VI. Serious bleeding occasionally occurs from the **plexus of veins** (or rather venous sinuses) on the perineal aspect of the prostate gland in old men (SPENCE).

THE HIGH OR SUPRA-PUBIC OPERATION.

It may be necessary to perform this operation—(1) On account of the large size of the stone, (2) rigid hip joint, and (3) contracted pelvic outlet. It is also advocated for boys, as it avoids the risk of a large wound in the perineum, rupture of the membranous urethra, and injury to the vesiculæ seminales and ducts. The bladder *must* be distended with twelve or sixteen ounces of some warm antiseptic, so that it can be felt above the pubes; if it cannot hold water, then this operation cannot be performed. An elastic ring may be passed round the penis to prevent the escape of the fluid. The injection may be accomplished through a silver catheter, the opening of which is securely plugged, and the instrument left in the bladder to serve as a guide during the latter part of the operation; or it may be taken out, and a staff introduced for the same purpose. This operation should only be used in cases where the urine is healthy; it is not likely to suit in cases of long-standing stricture, or enlarged prostate. In septic cases, a free drain is essential for the patient's safety.

The patient rests flat on his back on a table, with his shoulders slightly raised. His legs are not allowed to hang over the end

of the table, as this would make the recti tense. The preliminary preparations are the same as in the lateral operation, but a distensible bag should be introduced into the rectum to push the bladder forwards and upwards, and also to steady it. The Surgeon stands on the side he deems most convenient, and makes an incision two and a half or three inches long in the median line, immediately above, and partly over the pubes, so as to reach that part of the bladder which is uncovered by peritoneum.

In cutting down to the bladder at this point, the **Structures divided** are—(1) The skin; (2) the superficial fascia; (3) the sheath of the recti. Next, the adjoining edges of the recti and pyramidales are separated; and then, with the finger or the handle of the knife, separate the loose cellular and fatty tissue, and divide (4) the transversalis fascia, and the anterior surface of the bladder is exposed. Make out, if possible, the reflection of the peritoneum, and then depress the handle of the staff which is in the bladder so as to project its point above the pubes, and open the bladder by cutting down upon this as guide. The opening is then enlarged downwards, the forceps introduced, and the stone extracted. The wound may then be closed, both in the abdomen and in the bladder, provided the urine be healthy, and the urine drained off by a siphon, per urethram; but both must be left open if the urine be septic, and a drainage tube passed into the fundus of the bladder, and left there for a week or ten days; the patient meanwhile resting as much as possible on his side, to favour drainage, and he should change from side to side every six hours. When the bladder wound is stitched up, the **LEMBERT** suture should be employed, taking care to go beyond the angles of the incision at each end, in order to prevent leakage.

In the case of male children, Professor **ANNANDALE** introduces a lithotrite to grasp the stone and project it against the anterior abdominal wall. A small incision is then made over it, and the blades forced through the wound, and the stone removed. A No. 7 india-rubber catheter is next seized by the lithotrite and drawn into the bladder, along the urethra, and left there. The abdominal wound is then stitched up, and a drainage tube introduced. In forty-eight hours both drainage tube and catheter are removed. Before beginning the operation, four ounces of a warm

solution of mercuric chloride—1 in 4000—is injected into the bladder, and during the operation the wound is irrigated with a solution of 1 in 2000. The **advantages** of this method are—(1) The urethra, prostate, and neck of bladder are left uninjured; and (2) its simplicity does away with the risks of lateral lithotomy in children. This plan is best adapted for children, where the bladder is an abdominal organ.

The great trouble of this operation is the difficulty about easy and free drainage. Many plans are adopted—(1) An ordinary tube, aided by the position of the patient. (2) Drainage has been attempted, by adopting the principle of SPRENGEL'S air-pump. (3) Professor CHIENE uses a glass tube, with a bundle of worsted threads inside, so as to suck the urine up, in the same way as the wick of a lamp sucks up the oil. A dry antiseptic sponge is placed over the upper end of the tube and worsted threads, and this in turn absorbs the urine, and is then squeezed dry from time to time, either by the patient himself or his attendant. The threads might be elongated, encased in an india-rubber tube, and allowed to hang over the side of the bed, and drip into a vessel placed there. (4) A tube may be passed by the urethra, and the urine drawn off by siphon action.

The chief dangers of this operation are—(1) The risk of infiltration of urine into the cellular tissue of the wound; (2) the risk of wounding the peritoneum; and (3) the chance of setting up kidney mischief, such as suppurative pyelonephritis.

RÉSUMÉ of this operation:—

1. The patient is placed on his back on the table, his shoulders slightly raised, the pubes shaved, and the parts carefully washed with 1 in 20.
2. A catheter is then passed, the urine drawn off, the bladder washed out with warm boracic, if thought necessary, and then fully distended with the same fluid; the penis is then secured by an india-rubber band, or tape, to prevent the escape of the fluid. If a silver catheter be used, it may be plugged and left in to act as a guide. When the rectal bag is used, ten or twelve ounces will probably be enough.

3. Oil and introduce the rectal elastic bag, and fill it with warm boracic lotion; do not use too great force, lest the wall of the rectum be ruptured; eight to twelve ounces in the adult, and three to four ounces in the child, is the quantity usually required. This bag raises the *floor of the bladder* almost to the level of the upper edge of the pubes, so that it comes well within the reach of the operator.
4. Make an incision two and a half or three inches long in the linea alba, *and partly over the pubes*; this divides skin and fat, and exposes the linea alba.
5. Open the linea alba near the pubes, between the pyramidales, and, if thought necessary, divide the rest of the linea on SPENCE'S hernia director; next divide the fascia transversalis in a similar manner.
6. Hold the sides of the wound apart by broad copper spatulæ, and then, with the handle of the knife and finger, tease through the loose connective tissue and fat, and define the posterior surface of the pubes, the wall of the bladder, and the peritoneal reflection, which should be pushed up.
7. Having recognised the bladder by its muscular fibres, pass two silk stitches, one on each side of the middle line, through its muscular coat only, so as to hold it forwards and prevent its collapse and retraction behind the pubes when opened: two sharp hooks may be used instead of stitches.
8. Having thus secured the bladder, plunge a scalpel into it, with its edge towards the pubic bone, about an inch and a half above the pubes, quickly withdraw the knife, and insert a finger to plug the opening and ascertain the size of the stone.
9. The opening is then to be dilated sufficiently with the finger, the forceps introduced, and the stone withdrawn.

LITHOTRITY.

In this operation the stone is crushed in the bladder, and the pulverised fragments expelled or extracted through the urethra.

The instrument used for this purpose is called a *lithotrite*. The operation was formerly performed at several sittings, and the shorter these sittings were the better, because the long continued contact of instruments with the mucous membrane of the bladder is apt to produce cystitis, leading to pyæmia, or even death. At the first sitting the stone was simply crushed and the fragments were left to be pulverised and extracted at subsequent sittings. But the crushed stone thus left is apt to produce great irritation in the mucous membrane of the bladder, and, unless care be taken in the treatment of the patient between the sittings, small fragments of the stone are apt to be driven into the neck of the bladder, or even into the urethra, causing great pain and injury to the tissues; and, even with the greatest care in the *final exploration*, small fragments were apt to be left, which formed the nuclei of subsequent calculi.

About the year 1882 a new operation was introduced, called *Litholapaxy*, by BIGELOW, who was the first to plan and carry out the operation. For its performance the following **special instruments** are required—(1) A lithotrite, (2) a large evacuation catheter, and (3) an aspirating siphon.

The following **advantages** were claimed by BIGELOW for this operation—(1) The stone is crushed and removed at a *single sitting*, so that the bladder is thus freed from the irritation caused by small fragments of stone retained in its interior for a lengthened period, and the urethra is also freed from the irritation of their possible passage between the sittings (as in lithotrity); and further, the fragments are completely removed, so that none are left to form the nuclei of subsequent calculi; (2) the lock of the *lithotrite* which he used was more easily closed than in the ordinary lithotrite, being shut by a simple turn of the wrist without displacing the hands, and the blades are so formed that they allow of the easy escape of detritus, so that laceration of the neck of the bladder is prevented in the withdrawal of the instrument; and (3) the stone need not be *pulverised*, because (4) the catheter used is very large, its inventor taking advantage of the fact that the urethra admits of great dilatation.

This is the operation that is always performed now, under the name of **Lithotrity at a single sitting**—the old lithotrity

is a thing of the past. In the great majority of cases of stone, lithotripsy is the operation performed for their cure; according to Sir HENRY THOMSON, it is *the* operation for nine-tenths of adult cases of stone, and may even be used for children as well. The **special instruments** required are—(1) A set of large evacuating catheters, (2) an exhausting syringe, and (3) a lithotrite.

Conditions Necessary for Crushing.—(1) A bladder not too irritable; it must be able to retain at least three or four ounces of urine. (2) The kidneys, prostate, and urethra healthy; there must be no stricture of the urethra present. (3) The patient must not be too young; under ten or fifteen years, lithotomy is usually to be preferred. (4) The stone must not be too large or too hard; the size, however, is not of so much moment, but a very hard stone is a serious objection. (5) Several calculi are rather against crushing, especially if they are hard. The patient is placed on his back on a firm mattress or table, with his pelvis raised above the level of the shoulders by a firm pad, three or four inches thick, so that the stone may roll to the posterior surface of the bladder from its pouch behind the prostate; a pillow is placed under his head, and his thighs are separated so that his knees are about a foot apart. In children, and in cases of enlarged prostate, it may be necessary to raise the pelvis a couple of inches more. The Surgeon stands on the right side of the patient, as he holds the lithotrite with his left hand and works the screw with the right. An anæsthetic should be administered. The urine is first drawn off by a hollow sound or catheter, and then four or five ounces of tepid carbolic water is slowly injected; the urine is drawn off to enable the Surgeon to tell how much fluid there is in the bladder. Too much is bad, because the stone readily moves about and “dodges” the lithotrite; yet it must contain a fair amount to prevent the mucous membrane from being grasped by the lithotrite, or being injured by splinters of the stone.

To pass the Lithotrite.—The Surgeon may stand in the usual catheter position (the left side) till it has passed, then he must come to the right side; or, if he so prefer, he can stand on the right side all the time. The lithotrite is warmed and oiled and the blades closed and pointed downwards; the penis is then raised

by the left hand and drawn over the lithotrite, which is held almost parallel with the abdomen at this stage. It thus descends to the bulb, the shaft becoming gradually perpendicular; it is *not* to be depressed at this stage, as is usual when passing a catheter, as this would make the blades impinge upon the upper wall of the urethra in front of the triangular ligament, and probably rupture the urethra. It is kept perpendicular and allowed almost to pass by its own weight till the point reaches the prostatic urethra, and *then* the handle is depressed and the instrument enters the bladder.

To catch the Stone two plans may be adopted—(1) To make the lithotrite hunt for the stone (CIVIALE'S, or the Continental plan). The stone is first felt by the closed lithotrite, which is then opened and the blades turned down upon the stone, just as a bird picks up a stone with its beak; this method may be necessary occasionally in picking up stones behind an enlarged prostate, but is not so good as the next method. (2) To make the stone come to the lithotrite (BRODIE'S, or the English method). The lithotrite is never shifted from the mesial plane; it rests in the middle line, the blades are then opened wide, the under one depressed when the stone rolls into its grasp. The stone must not be crushed in this position, but the lithotrite must first be raised, to make sure that no mucous membrane is grasped; it is then screwed home gradually and completely. The instrument must never be withdrawn till the blades are screwed completely home, otherwise fragments are left between the blades which lacerate the neck of the bladder and urethra. The fragments are then removed by means of the large evacuating catheters and aspirating siphon.

Calculus in the Female.—Stone is of rare occurrence in women. When it does occur, it may be removed—(1) By **Lithectasy**, *i.e.*, through the dilated urethra, dilated either—(a) by a sponge tent, or special dilator, or (b) by incising the mucous membrane. (2) By **Lithotomy**—(a) the supra-pubic operation, as in the male; (b) the urethral operation, by introducing a grooved staff and cutting along it into the bladder; or (c) the *vaginal* operation, by cutting through the anterior wall of the vagina and the base of the bladder. (3) By **Lithotrity**, or **Litholapaxy**.

CHAPTER XLII.

THE PELVIS—(*Continued*).

THE URETHRA.

Length.—The length of this canal in the male is from eight to nine inches; in the female it is only about an inch and a half in length, and corresponds, as we have seen, to the prostatic portion of the male urethra.

Divisions.—In the male it is divided into three parts. (*a*) **The prostatic portion.** This part is about an inch and a quarter in length, and passes almost directly downwards, but slightly forwards. It is situated about the middle of the prostate gland, but rather nearer its anterior surface, and is in front of the middle lobe. In connection with it we notice the following parts:—(1) As it opens into the bladder there is a transverse fold of mucous membrane, called the “*uvula vesicæ*.” (2) Continuous with this, there is a median ridge, called the *crest* of the urethra, *caput gallinaginis* or *verumontanum*. (3) On either side of this crest there is a depression called the *prostatic sinus*, and in it may be seen the openings of numerous prostatic ducts. (4) At the summit of the crest there is a median opening called the *sinus pocularis*; and (5) at each side in the walls of the sinus are seen the openings of the *common ejaculatory ducts*. (*b*) **The membranous portion.**—The length of this part is—anterior wall, three-quarters of an inch; posterior wall, half-an-inch. It is directed forwards and downwards, but more downwards than forwards, extending from the apex of the prostate gland to the bulbous portion of the urethra, and is contained between the two layers of the triangular ligament, the anterior layer of which it pierces, and is about an inch below the symphysis pubis. It is surrounded by the compressor

urethra muscle, and is the most frequent seat of *spasmodic* stricture. Spasmodic stricture, however, may occur at any part of the membranous or penile portion of the urethra, for the urethra is as truly a muscular tube as the œsophagus, and, like it, has a complete muscular coat. (c) **The spongy portion.**—The posterior part of this portion is sometimes called the *bulbous portion*, from the fact that it is surrounded by the bulb of the urethra (which is simply the dilated posterior part of the corpus spongiosum, just as the glans penis is the dilated anterior part). The length of the spongy portion is from five to six inches (the bulbous part occupies about an inch of this). The direction of this part necessarily varies with the state of the penis; the bulb, however, is the lowest part of the whole canal, and into it the ducts of COWPER'S glands open. The bulb is, further, the most frequent seat of *organic* stricture, probably because, being the lowest part, the inflammatory products tend to accumulate at this point. Along the floor of the spongy portion proper numerous mucous follicles open, their orifices being directed towards the meatus; there is also a large one in the roof of that part of the urethra situated in the glans penis, called the *lacuna magna*, and this one must be avoided in passing small catheters. When these lacunæ inflame and suppurate, the abscess thus formed will be in the middle line, thus differing from abscesses due to inflammation of COWPER'S glands.

Size and Shape of the Urethra.—The urethra, as we have already pointed out, admits of considerable dilatation, so that no exact measurement is obtainable of its absolute size; we can, however, compare the size of one part with another. The most distensible part is the prostatic urethra. When closed, it is simply a slit—at the anterior part, the slit is *vertical*; further back, the slit is *transverse*; while in the prostatic portion, the slit is *curved*, with its concavity downwards, as seen on transverse section. It is narrowest at the meatus, and the next narrowest part is at the junction of the membranous with the spongy portion—*i.e.*, as it pierces the triangular ligament (anterior layer). If the *prostatic* part be distended it is seen to be fusiform in shape, being widest in the middle and a little contracted at each end; the *membranous* portion is the narrowest. The *bulbous* part of the spongy portion is dilated; it then grows somewhat smaller, but expands again in

the glans penis to form the fossa navicularis, and then contracts to form the meatus. The widest parts of the tube are (*a*) the centre of the prostatic portion, (*b*) the bulbous portion, and (*c*) the fossa navicularis—in this order from behind forwards.

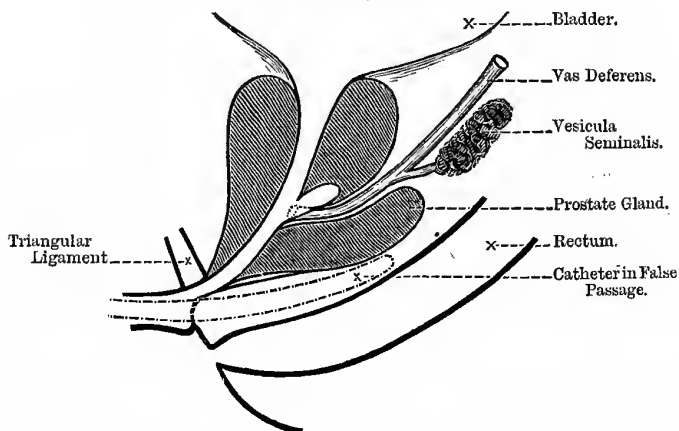
Curves of the Urethra.—In the flaccid condition of the penis, the general course of the urethra somewhat resembles the letter **S** lying on its side; but when the penis is erect the anterior curve is obliterated, and hence this is called the *temporary* curve. The *permanent* curve, however, remains under all circumstances, and we have thus two curves—(1) the temporary, and (2) the permanent; and to this latter the curve of the catheter corresponds. The permanent curve is maintained by—(*a*) The pelvic fascia, fixing the neck of the bladder and the prostate gland; (*b*) the connection of the root of the penis with the pubes by means of the suspensory ligament of the penis; (*c*) the two layers of the triangular ligament fixing the membranous part; and (*d*) the connection of the base of the triangular ligament with the superficial fascia of the perineum, and through it to the “central point of the perineum.” It is of importance to remember that, with the finger in the rectum, the anterior layer of the triangular ligament, the membranous part of the urethra, prostate gland, and even the base of the bladder beyond, may be felt. These parts are more easily distinguished if a catheter be previously introduced; and in this way the fact of having made a false passage may be detected, the catheter not being found in the bladder, nor bearing the proper relation to the parts in question. To be right, the catheter should be felt exactly in the middle line, with the prostate gland and the rectal wall between it and the finger; in false passages it will probably not be in the middle line, and the finger will recognise only a *thin* layer of tissue between it and the catheter. The mucous membrane of the urethra is supplied by the pudic nerve.

To pass a Catheter in the Male.—The patient is placed on his back in bed, lying perfectly straight, with the upper and lower parts of his body well covered; the Surgeon stands on the patient's left side. See first that the catheter is well cleaned, by forcing a stream of carbolic lotion through it by means of a syringe, being specially careful of the eye of the instrument, about which dirt is apt to lodge; it must next be slightly warmed and

oiled. It is now held between the thumb and two fingers of the right hand, and directed obliquely across the patient's left groin, a little above and parallel with the skin, and also parallel with *POUPART'S* ligament; the penis is then steadied with the left hand, and the point of the catheter passed four or five inches down the urethra, the handle being gradually brought up to the middle line till it lies parallel with the *linea alba*, and also with the surface of the abdomen. The handle is next to be brought gradually downwards from the *linea alba* towards the interval between the patient's thighs, and when the point is in the bladder it will

Fig. 218.

A FALSE PASSAGE.



almost lie parallel with the thighs. When the bulbous portion is approached, be specially careful to keep the point of the instrument against the upper wall of the urethra; and should any difficulty be experienced, gently pull forward the root of the scrotum, which will steady the bulbous portion. If it still sticks, after it has entered the membranous portion, oil the left index finger and pass it into the rectum, while the thumb is placed against the perineum, to steady and direct the catheter. In this way, the point can be held against the upper wall; as long as the catheter is in the middle line, and the pad of prostatic

tissue felt between it and the finger, all is well. It is only when the point of the catheter is allowed to press against the lower wall that false passages are made (Fig. 218). Above all, force must not be used, and there must be no "milking" of the penis. When the operation is completed, give the patient a warm drink, and make him comfortable in bed for a little.

To pass a Catheter in the Female.—The patient should not, if possible, be exposed. She is to be laid on her back, and the operator stands on her right side; her right leg is to be flexed, the sole resting on the bed or couch. A tube, five feet in length, should be attached to the catheter, so that the urine may flow directly into a receptacle placed on the floor; the end of this tube should be passed beneath the patient's flexed leg. The operator then passes his right hand under the patient's right leg, and places the index finger in the fold between the labia, a little in front of the anus, and glides it forwards gently till he feels it entering the orifice of the vagina, and in bringing it a little further forward, always in the middle line, the point of the finger comes into contact with the urethra, which is thus gently steadied between it and the pubic arch. The other hand is then passed over the patient's thigh with the catheter, the point of which is slid along the palmar surface of the index finger placed against the urethra, till it enters that orifice, when it can easily be pushed on to the bladder, as the canal is so short and straight. The only difficulty is to strike the meatus by touch alone. The operation may be performed from the left side, if preferred. Some use the clitoris as the guide for the orifice, but I believe that the way described is much better in every way.

Stricture of the Urethra :—

1. **Spasmodic**, either alone, as from reflex irritation, or complicating congestive or organic stricture.
2. **Inflammatory** or **Congestive**, from swelling of mucous membrane, as in the retention of acute gonorrhœa.
3. **Organic**.—This *alone* will not cause complete retention; either spasm or acute inflammation, or both, must be superadded. For this reason, therefore, the first thing is, *not* to pass a catheter, but to give the patient a hot

sitz bath to get rid of the spasm, just as steam is used in croup; and if that is not enough, use a morphia suppository, or some preparation of morphia and belladonna, and a dose of bromide of potassium, put him in a warm bed, and apply fomentations to his perineum. Lastly, if all fail, try to pass a No. 9, or even larger, rigid catheter in the way already described; if you fail in the ordinary way, then put the patient under chloroform and try again. It is usual to use the French olivary catheters to start with, and should they fail, to use silver instruments. Should this also fail, three courses are open—(1) To aspirate above the pubes, (2) tap per rectum, or (3) open the membranous urethra by Mr SPENCE'S method. As a rule, the first is to be preferred.

Organic Stricture is due to the organisation of a plastic exudation thrown out into the *submucous* tissue; this is transformed into fibrous tissue, which gradually contracts and closes the canal. The usual causes are—(1) **Inflammation** (usually gonorrhœal, but may occasionally follow non-specific urethritis). (2) **Traumatism**, as rupture of the urethra from falling across a spar with the legs apart, when the urethra is snapped across between the pubic arch and the spar; in this case it is the bulbous part of the urethra that is injured. The urethra is also frequently injured in fractures of the pelvis, but in this case it is the membranous part that suffers. The traumatic stricture is the worst of all forms, and is very frequently situated in the membranous part of the urethra; probably 99 per cent. arise from gonorrhœa.

Locality.—According to Sir HENRY THOMSON—(a) 67 per cent. are found near the junction of the bulbous with the membranous portion; (b) at or near the external orifice, 17 per cent.; (c) 16 per cent. between these two points. It is well to note that stricture is not found in the prostatic part of the urethra; examiners find some difficulty in believing in the existence of prostatic stricture, notwithstanding they are told of it so repeatedly. In fact, it is a physical impossibility, because the inflammatory process round the urethra in the substance of the prostate produces fibrous tissue, which as usual tends to contract; but as the capsule of the prostate

is more resistant than the mucous membrane, it contracts *towards* the capsule as the fixed point, and will therefore actually dilate the urethra, just as cirrhosis of the lung produces bronchiectatic cavities for the same reason.

Signs.—One of the earliest signs of stricture is frequency of micturition, especially at night; this may be accompanied with a gleet discharge and dribbling at the end of micturition. Sometimes also there is a difficulty in beginning to pass water. There are also changes in the size, shape, and direction of the stream—it may be forked or spiral, or go suddenly to one side. This is because the presence of the stricture does not allow a stream to pass, large enough to distend the meatus, on which its size and shape depend. Then from some slight cause, as cold, whisky, etc., comes complete retention, from the superadded inflammation and spasm.

Retention of Urine.—In children, retention is usually due to the impaction of a calculus at either of the narrow parts of the urethra, or malignant disease of the prostate, sometimes to a string tied round the penis. In newly-born children, it may depend on a contracted orifice of the prepuce.

In young men, it is usually due to urethritis, simple prostatitis, or abscess.

In middle-aged men, usually to organic stricture, *plus* congestion or spasm.

In elderly men, it is usually from congestion of an enlarged prostate, or from atony due to an enlarged prostate, or to old organic stricture.

True Atony must be distinguished from paralysis: in atony, it is the *muscle* that is primarily at fault, not the *nerves*. It will also depend on the vitality of the person, for the obstruction that would hypertrophy a healthy bladder will dilate and render a weakly one atonic. When the bladder is much distended, we may get oedema of the legs, from pressure on the iliac veins.

In retention from atony, the catheter enters easily, and the urine flows out in a slow, uniform stream, and is not projected by the contraction of the *detrusor*, the only variations being due to the respiratory movements and to the abdominal muscles. A very important caution is necessary here. In pressing over the bladder

with the hand to expel the urine, the Surgeon *must on no account relax his pressure in the slightest degree till the catheter is withdrawn from the urethra completely*, otherwise the abdominal muscles spring back, the intra-abdominal pressure is lessened, and air is driven up the catheter into the bladder, probably carrying septic micro-organisms with it.

In **retention from obstruction**, the catheter enters with difficulty, but when once in, the urine is projected with considerable force, and is not influenced by the respiratory movements. A *very full* bladder should not be emptied all at once, lest it cause shock and fatal depression; draw off forty ounces, let the patient rest an hour, and then draw off the rest.

Incontinence of Urine.—True incontinence is of very rare occurrence, and is only found when the nerves of the bladder are injured. It is found in cases where a segment of the spinal cord is destroyed by disease or injury, usually about two weeks after the injury. The urine dribbles passively away as fast as it is secreted; **active incontinence** often occurs in boys at night during sleep, and in these cases always examine the penis for congenital phimosis, adhesions of the prepuce to the glans, or accumulation of secretions under the prepuce about the corona glandis. Active incontinence in a child by day indicates great irritability of the bladder, by night it rather shows atony of the sphincter—for the first, remove sources of irritation and try belladonna; but for the second, strychnia. The so-called “incontinence” of enlarged prostate, is not incontinence at all, but is simply the dribbling from an over-distended bladder, as the great pressure within opens up the neck of the viscus, and allows the urine to dribble through. Persistent dribbling in boys is also caused by stone, especially when coupled with a long prepuce, and by very tight traumatic strictures. In examining an unknown urethra to ascertain the existence, or otherwise, of stricture, always begin with a good-sized instrument—say, No. 8.

I will only but very briefly indicate the **Treatment**. In most cases **dilatation** by the ordinary method will be found sufficient—in ninety-nine cases out of every hundred. An instrument as large as the patient can comfortably bear is passed the first day; then at intervals of from three to four days larger sizes are passed, till the

meatus will admit of no larger size—perhaps from 14 to 16, English size, or even larger. The instruments are taken out as soon as passed, and after getting a warm drink, and half-an-hour to an hour's horizontal rest, the patient may be allowed to depart; it is well to warn him, on the first occasion, that he will find the stricture worse the following day (from the inflammatory effusion), but by the third day he will be all right. In passing catheters the rule is—to pass the size below the largest one passed on the patient's previous visit, and never to miss a size. During the passage of instruments the patient must be covered as far as possible—a blanket over his chest and abdomen, and another over his legs and feet—only leaving the upper part of the thighs exposed. After their passage he should then get a warm drink, and be allowed to rest in bed. He ought also to be told to keep his water as long as possible after they have been passed, lest there should be an abrasion about the urethra. With these precautions, the risk of "urinary fever" is much lessened. For the same reason, some Surgeons give a dose of quinine a short time before the passage of instruments.

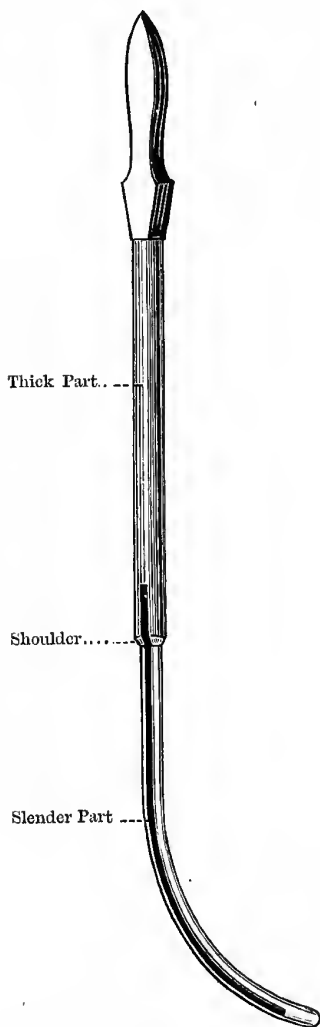
Resilient Stricture.—By this is meant strictures that very readily dilate up to the full size, but very speedily return again to the contracted condition. In this case it is impossible and useless to treat them by the above method. It was for such as these that Mr HOLT introduced his method of "splitting" the stricture by a special wedge-shaped instrument. The risk is that the mucous membrane of the urethra will also be split, and leave a surface for septic absorption, and it may be followed by serious or even fatal effects. Relapse after this treatment is very speedy and common, as the new cicatrix contracts faster than the original fibrous stricture.

Syme's Operation of External Urethrotomy—sometimes called "**Perineal Section.**"—This method of external urethrotomy is employed in obstinate cases of stricture, where there are at the same time large and numerous fistulæ, and great induration of the perineum, and the condition refuses to improve after a fair trial of rest, and drawing off the urine by the catheter. Strictly speaking, the name of "perineal section" should be applied to cases where the urethra is cut down upon without a guide passed into the bladder—*e.g.*, WHEELHOUSE'S operation.

The instruments required are—A sharp-pointed bistoury; No. 10 catheters, silver and gum-elastic, and red rubber tubing to fit the catheter; probes, straight and curved; SYME'S grooved and shouldered staff (Fig. 219), lithotomy tapes, a large number of WELLS'S forceps, ligatures, sponges, etc. The thick part of the staff is about the thickness of a No. 11 catheter; the slender part, No. 3, or less.

The patient is tied up in the lithotomy position, and the perineum shaved. The staff is passed before tying up, making sure that it is in the bladder by passing the finger into the rectum and feeling. The assistants required are the same as in lithotomy. The lower half of the staff is slender and grooved, but the upper part is of full size, and the shoulder, where the two parts meet, rests firmly against the face of the stricture, while the slender part passes through it into the bladder. The groove extends over the shoulder, and on to the thick part of the staff for a little way. An assistant holds the staff in his right hand, and draws up the scrotum with his left; and the operator, seated on a low stool facing the patient's buttocks, satisfies himself that the staff is in the bladder, and then makes an incision in the median raphé, from above downwards, about two inches long, and continues the dissection till he can distinguish the shoulder of the staff, which is the guide to the stricture. He then takes a sharp, straight bistoury in his right hand, and holds the staff with his left, enters the point of the knife into the groove in the staff, with its edge upwards, at the posterior part of the wound, about one inch below the shoulder, and cuts *upwards* through the stricture; he next withdraws the staff about a quarter of an inch and extends the incision that much further forwards. If the stricture has been completely divided the thick part of the staff may now be passed through it; the staff is then withdrawn, and a large gum-elastic catheter (10 or 12) passed and tied into the bladder, and a siphon arrangement attached to it, by which the urine is continuously drained off. It will be noticed that the point of the knife is guided to the groove by the index finger of the hand holding the knife, and not as in lithotomy. The knife rests against the finger, while the finger tip rests against the groove on the staff, and the knife is slid forwards by a movement

Fig. 219.
SYME'S STAFF.



Observe the exact extent of the Groove.

of the thumb and second finger. A morphia suppository is then introduced, and the patient made comfortable in bed. At the end of forty-eight hours the catheter is withdrawn, and about three days later a full-sized bougie is passed—I believe Mr SYME himself passed a specially-constructed catheter through the *perineal wound*, and not an ordinary catheter through the penis. Later, a bougie is passed once a week or once every two weeks, as circumstances may require. This operation may also be used instead of HOLZ's plan, in resilient stricture; the great advantage is that it gives the dilatation a good start, a full-sized instrument being passed at once, and all that is to do is to keep it from contracting again.

Wheelhouse's Operation, or "Perineal Section:"—

Definition.—Opening the urethra at a healthy part about one quarter of an inch in *front* of the stricture, passing a probe through the stricture, and then dividing it from *before* backwards.

Instruments.—Lithotomy tapes, special grooved staff with a button-like end, scalpel, two pairs of forceps, nibbed at the point, artery forceps, director, probe, gorget, silver catheter (No. 10) with elastic tube attached. The patient is tied up in the lithotomy position, the staff is passed and made to rest against the stricture, and the urethra opened a quarter of an inch in front of this through *healthy urethra*. Then grasp the edges of the divided urethra with the nibbed forceps, and hold apart; and next withdraw the staff a little, turn round, and hook the button-like end against the upper angle of the wound. Now pass the probe through the urethra into the bladder, divide the stricture, and pass the blunt gorget through the groove on the director, and on this the catheter is guided into the bladder. The catheter is passed from the meatus down to the wound, and then the gorget guides it into the bladder.

Note these three operations—(1) **Syme's**, where a grooved staff is passed through the stricture, the urethra opened behind, and the stricture divided from behind forwards. (2) **Wheelhouse's**, where the urethra is opened in front, a grooved probe passed, and the stricture divided from before backwards. (3) **Spence's or Cock's** (see vol. ii., page 467), where the urethra is opened behind the stricture, the stricture itself being left untouched, hoping that the induration and the swelling will disappear and the stricture

relax. The first two operations may be used in cases of stricture, complicated with urinary abscess and extravasation, etc.—**SYME'S**, when a staff can be introduced; and **WHEELHOUSE'S** when no staff can be passed through the stricture. In both be careful to keep exactly in the middle line. Observe that neither **SPENCE'S** nor **COCK'S** operation *can* be used in cases of extravasation of urine, since in performing these operations it is *imperative* that the membranous urethra should be fully distended with urine.

To Tie in a Catheter.—1. **A Silver Catheter.**—The catheter must be tied *to the pelvis*. (1) Tie a single turn of broad bandage round the pelvis. (2) Then take two pieces of narrower bandage and pass them round the thigh at the groin, under the perineum, loop them round the waist band, and fasten them before and behind. (3) Through each eye of the catheter pass a piece of tape, and fasten them in the middle, so as to have two equal tails on each side. (4) Fasten these, one in front and one behind, to the perineal loops, taking great care that they are all equally tight. (5) Plug the opening of the catheter. Take care that the catheter does not project into the bladder, lest, as the bladder is empty, the mucous coat be pressed against the instrument and ulcerate; the catheter should have a very short point, and the eye should *just enter* the bladder.

There are many modifications of the above plan: thus, by splitting a bandage properly, the waist band and the perineal bands may be made of one piece; or the perineal bands may be passed through the rings of the catheter and then fastened to the waist band, the anterior end being tied to the waist band by a single knot leaving a free tail, while the other end is brought round the thigh and tied to this tail.

2. **A Soft Catheter.**—The soft catheter is to be fastened *to the penis*, and should be used in preference to the silver instrument. (1) Encircle the point of the penis with a strip of boracic lint. (2) Tie a cord round the catheter a little beyond the end of the penis, and carry the two ends backwards, one on each side of the glans penis. (3) Cut a strip of adhesive plaster, about an inch and a half broad, and long enough to encircle the penis two or three times, and apply it lightly, but firmly, over the ends of the cords behind the glans, carrying the cords forwards after the first

turn is applied, to prevent it slipping. (4) Plug the catheter. In some cases it may be possible to tie the ends of the string to a bundle of pubic hairs on each side. In passing a gum-elastic catheter, it is better to make it rigid for the time being, as the Surgeon then possesses greater control over the instrument. To do so, the plan used by Professor CHIENE is to pass a cylindrical metal bougie, a size or two smaller than the gum-elastic instrument, into its interior, till it is passed, when the metal bougie is withdrawn. The ordinary stylet, sold with the gum-elastic catheters, is useless for this purpose.

RÉSUMÉ of the treatment of organic stricture:—

1. In the usual form of simple non-irritable stricture, where the patient cannot conveniently be confined to the house, use the usual method of dilatation by wedge-shaped bougies (LISTER'S). This method can usually be adopted in ninety-nine cases out of every hundred (see vol. ii., page 437).
2. If the patient can lie up in bed, and is in a hurry to get well, or in cases where the instruments can only be passed with difficulty, tie in a soft gum-elastic instrument; fix it to the penis, and see that it does not project too far into the bladder, the eye alone should just enter the bladder. As soon as one instrument becomes loose introduce another.
3. For severe, irritable, indurated, and resilient strictures, HOLT'S method of "splitting" is usually advised; if this plan be used it is better to pass a catheter into the bladder for twenty-four hours and draw off the water, lest the mucous membrane be torn, or tie in a flexible instrument. HOLT'S method, I believe, should be avoided as far as possible, and SYME'S method substituted for it.
4. In tight cartilaginous and in irritable stricture, with induration in the perineum, along with abscesses and fistulæ, use SYME'S method of external urethrotomy; and if an instrument cannot be introduced, operate on WHEELHOUSE'S principle—"perineal section."

5. In certain forms of *penile strictures*, internal urethrotomy, cutting from behind forwards, may be adopted; after this tie in a catheter to keep the cut surface free from urine, and lessen the risk of "urinary fever."
6. In many cases Professor ANNANDALE prefers the method of combined external and internal division. A No. 2 catheter is passed through the stricture into the bladder, and then a free incision is made in the middle line, behind the most posterior stricture. The catheter is next removed, and the grooved staff of a urethrotome is passed along the urethra; the urethrotome used closely resembles MAISSONNEUVE'S instrument. The knife of the urethrotome is now passed along the groove of the staff, and all the strictures divided. After this, pass a No. 12 catheter, and keep it in for twenty-four hours. The advantages of this method are—(1) The complete and accurate division of all the strictured parts; and (2) the ease with which the operation can be accomplished.

In treating stricture cases for the first time, it is important to avoid, as far as possible, the risks from "urinary fever":—

1. The patient should rest in bed for a week or ten days if possible, and have his diet restricted to milk and soda-water.
2. In passing the bougie, all unnecessary exposure should be avoided, and his legs and chest covered with blankets to keep him warm.
3. See that the instruments passed are perfectly clean, as many Surgeons are inclined to say, and with truth, that "urinary fever" is often nothing more than "dirty catheter fever."
4. As soon as the instruments are passed, the patient is carefully covered up in bed, and should at once get a warm drink.
5. He should be directed to keep his water as long as possible after this, lest the catheter may have caused some slight abrasion of the mucous membrane.

After the Surgeon knows the urethra, if there be great pain in passing instruments, a cocaine bougie should be introduced five or ten minutes before they are to be passed.

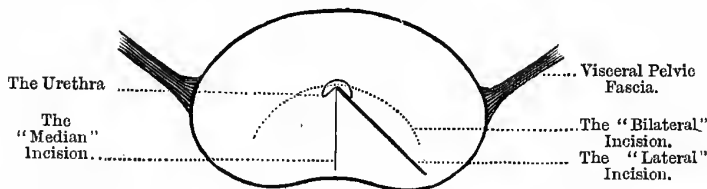
Hæmorrhage is one of the chief dangers of **internal urethrotomy**, at any part of the canal, but especially if the section involve the upper wall of the membranous urethra; here the dorsal vein of the penis may be wounded, or the plexus of **SANTORINI**, into which it empties (**FENWICK**). When this happens the blood pours from the prostatic and vesical venous plexuses, as well as from the internal iliac veins, as the valves are very often incompetent.

THE PROSTATE GLAND.

This gland is situated behind and below the pubes, embracing the neck of the bladder, and *lying against* the anterior wall of the rectum, the recto-vesical layer of pelvic fascia being the only

Fig. 220.

THE PROSTATE.



structure that is interposed between the two. In size and shape it resembles a chestnut. It is closely connected with the anterior and lateral true ligaments of the bladder (pelvic fascia), which join it at its *upper part*, and for this reason the anterior ligament is called, at this point, the "pubo-prostatic" ligament. It is this fascial layer that we must on no account pass beyond in making the incision in lateral lithotomy, otherwise the operation will be followed by infiltration of urine into the sub-peritoneal cellular tissue of the pelvis. Between the two pubo-prostatic ligaments is the dorsal vein of the penis. It has also attached to it the anterior fibres of the levator ani muscle, these fibres being called, for this reason, the "levator prostatai." It consists of three lobes—a median

and two lateral. The middle lobe is the smallest of the three, and lies immediately below the prostatic portion of the urethra; it is pyriform in shape, and when prominent the base projects into the bladder, forming the *uvula vesicæ*. From base to apex the prostate measures twelve to fourteen lines in the adult, and from the apex at the membranous portion of the urethra downwards and outwards it measures three or four lines more; it is in this latter direction that the incision is made in lateral lithotomy—both because we get more room, and also because the incision is not likely to injure the visceral layer of the pelvic fascia. Its usual size is an inch and a half in the transverse diameter at the base, an inch and a quarter in its antero-posterior, and nearly an inch in thickness.

In elderly men the prostate frequently becomes enlarged, and it is the middle lobe in some cases that seems to enlarge most, or the enlargement of which gives rise to the most serious consequences. This is probably partly from its position, as it will tend to grow in the direction of least resistance, that is, up into the base of the bladder. According to Sir HENRY THOMSON, a **measurement** of two inches from side to side, and a **weight** of one ounce, means hypertrophy: the usual weight is about six drachms.

The **results of the enlargement** are:—(1) A pouch is formed behind the projection, so that the urine tends to dribble away after it has passed in a full stream; in many cases, also, the urine lies in the pouch, and cannot be entirely expelled, and the unexpelled portion soon becomes decomposed and ammoniacal, and irritates the mucous membrane of the bladder, leading to chronic cystitis. (2) The projecting part may overlap the orifice of the urethra (which is normally the *lowest* point of the bladder), and act like a valve, preventing the passage of the urine through the urethral orifice, and the more the patient strains the tighter it becomes. (3) It alters the direction of the urethral tube, forming a little recess, and this must be kept in mind in passing a catheter, and special care taken to pass none but perfectly purified instruments; otherwise this well of “residual urine” is inoculated with septic matters, the probable result being the rapid onset of septicæmia. The patient consults a medical man, not for retention, but for what he calls too frequent making of water, especially at *night*; this is really “dribbling,” or overflow from an already over-full

bladder. When a catheter is passed after the patient has just made water, very likely twelve or fourteen ounces, or more, will be drawn off. In passing the catheter, it will be obstructed at a point *more* than six inches from the meatus, which will probably be overcome by depressing the shaft of the catheter. In stricture the usual seat of obstruction is about six inches from the meatus, or in the bulbous portion.

When the lateral lobes of the prostate are enlarged, the prostatic urethra becomes dilated and elongated, and its axis altered to one or other side, according to the lobe specially affected; the bladder is also raised out of the pelvis, to a certain extent, into the abdomen.

In **Structure**, the gland consists of **glandular, fibrous, and muscular** elements, in variable proportion; the "hypertrophy" is probably in many cases due to an increase in the muscular tissue (non-stripped)—hence, perhaps, the value of ergot in this condition. Near the opening of the bladder there is a dense fibro-elastic ring, about three lines in breadth, which it is impossible to dilate beyond a certain limited extent. When this ring is cut, as in the operation of lateral lithotomy, however, the gland texture splits up easily in the direction of the cut. It is enclosed in a dense fibrous *capsule*, derived from the pelvic fascia—from the vesical, recto-vesical parts, and from the parietal layer as well. Beneath the capsule, chiefly on the lateral aspects, lies a dense network of veins—the prostatic plexus—into which the dorsal vein of the penis empties itself. It is important to note that septic thrombosis sometimes follows operations in this region.

The **Lymphatics of the Prostate** pass to the internal iliac group of pelvic glands, and thence to the lumbar group. These glands therefore enlarge in cancerous affections of this structure.

The **Nerves of the Prostate** are derived from the *prostatic plexus* of the sympathetic, and this in turn is derived from the *hypogastric plexus*, which has communications with the epigastric or solar plexus, through the aortic plexus. The prostatic plexus also supplies the erectile tissue of the penis, and ends about the corona glandis; it also supplies the vesiculæ seminales and neck of the bladder, and in this region communicates with the fourth sacral—which, it will be remembered, supplies the levator and

sphincter ani and skin between the anus and coccyx (see vol. ii., page 403). It will be easily understood, therefore, how anal and prostatic or bladder affections act and react on each other: as bladder and prostatic affections, causing tenderness and pain in the rectum and about the anus; and anal troubles, causing frequency of micturition, pain at the point of the penis, or even retention, as seen sometimes after operations for fissure and piles. **Inflammatory affections** of the prostate, simple and tubercular, give rise to symptoms like those of stone in the bladder, as the neck of that viscus is affected in these conditions. The abscess very frequently opens into the urethra, and the pus may pass back into the bladder, and set up cystitis; next in frequency, it opens into the rectum, and lastly, it may make its way towards the perineum. **Tubercular abscesses** of this gland are very troublesome, and the tension caused by the dense capsule may cause absorption and generalisation of the tubercular material, and carry off the patient by tubercular meningitis; the best treatment is to open into the gland by a free median perineal incision, and scrape away the diseased matter. Prostatic affections are very apt to cause orchitis, or first rather, epididymitis; the inflammation spreads into the ejaculatory ducts, then along the vas to the epididymis and testicle. This is seen in acute gonorrhœa or gleet, in prostatic calculus, prostatic abscess, irritation from the frequent passage of catheters during "catheter life," and sometimes after lateral lithotomy; it also explains, probably, why tubercular disease of the prostate and epididymis are so frequently found together. The curious thing is, why *one* testicle only should be affected, *e.g.*, in gonorrhœa, since the two ejaculatory ducts are so close together.

Management of Prostatic Cases.—(1) By care as to diet and clothing, keeping the bowels and other functions regular, emptying the bladder at once when nature calls, the patient may get along pretty comfortably. (2) Should these means fail, then the patient must begin his "catheter life." He must be provided with a suitable instrument, and be taught how to draw off his water.

In **retention due to enlarged prostate**, the bladder does not hold so much as appearances at first sight would indicate, as the enlarged prostate fills up the pelvis, encroaches upon the bladder,

and pushes it up into the abdomen. To relieve the retention try the following instruments, in order:—(1) A soft red rubber catheter, which is not grasped by the meatus, and twirl it in; (2) an *à coudée* or *bi-coudée* catheter. From the presence of the elbow, or elbows, on this catheter, its nose is kept against the upper wall of the urethra, and consequently passes along that tube much more easily. (3) The silver catheter, ordinary or “prostatic,” with the long curve; and (4) the gum-elastic, with stilet: pass this up to the obstruction, then withdraw it a little, pull out the stilet for a short distance, holding the catheter steady—the withdrawing of the stilet makes the end of the catheter curl up, and mount through the curved urethra. (5) If it is impossible to introduce an instrument, then aspirate above the pubes.

Means adopted to Diminish the Size of an Enlarged Prostate.

—(1) The administration of ergot; (2) the occasional passage of very large bougies; (3) the continuous electric current, on account of the power it has of affecting nutrition—trophic effect—the so-called “electrolysis;” and (4) **Prostatectomy**—open into the bladder, as in the operation of supra-pubic lithotomy, and excise the enlarged and projecting “third lobe.” The mucous membrane is incised, and the growth enucleated in one or several portions. There is often free hæmorrhage in this operation.

Perineal Cystotomy.—In certain cases Professor ANNANDALE performs a median perineal cystotomy. It is done in cases of enlarged prostate with persistent and aggravated irritability of the bladder, where there is a constant desire to pass water, with cystitis. He prefers the perineal route, because (1) the bladder drains better, and (2) the incision through the prostate seems to have a good effect on the enlarged organ. A staff is passed into the bladder with a median groove, and the patient is tied up, or held, in the usual lithotomy position. The left index finger is then passed into the rectum and placed upon the apex of the prostate. The knife is entered about three-quarters of an inch in front of the rectum, with its edge directed upwards, and the staff struck. The knife is then turned, and the wound enlarged a little downwards. A beaked director is then passed along the groove of the staff into the bladder—as it is impossible to reach the bladder with the finger, on account of the enlarged prostate—and the staff

withdrawn. The knife is then passed along this director, and the prostatic urethra nicked. A large-sized tube is next passed along the director into the bladder. The tube may either be an ordinary lithotomy tube, or WATSON'S (Boston) tube may be used. This tube is specially long and curved, so as to suit itself to the curve of the prostate. The tube is fastened into the bladder in the usual manner, and must be kept in for two or three weeks. At the end of this time PROFESSOR ANNANDALE introduces a soft red rubber catheter, of full size, with velvet eye, cut short, so that its rounded end will just lie in the bladder, and its cut extremity project from the perineal wound. This end is fitted with a vulcanite tube of half-an-inch long, with bulbous ends; this allows of the soft tube being tied in by two loops, without interfering with the canal of the catheter. To the other end of this vulcanite tube a convenient length of india-rubber tubing is fixed, with a tap at the distal end. By this means the bladder may be emptied at any time by turning on the tap. The red rubber catheter is used, because it is soft and pliable, and the patient can walk about with it. The only objection is that, being a foreign body, it may cause cystitis. Perhaps a better plan would be to make a permanent perineal fistula, and not wear a tube at all. The operation, as performed by PROFESSOR ANNANDALE, is not followed by permanent incontinence, the patient still having control over the sphincter. The only difference is that his mode of urinating approximates the female type.

Supra-Pubic Cystotomy.—The above operation may also be performed above the pubes, although, for reasons already stated, the perineal route is probably the best. It is, however, impossible to say with certainty which is the better, as neither operation has as yet been performed a sufficient number of times to enable one to judge. In fat patients, or where more room is needed, it has been advised to use a transverse incision, instead of the usual vertical one.

CHAPTER XLIII.

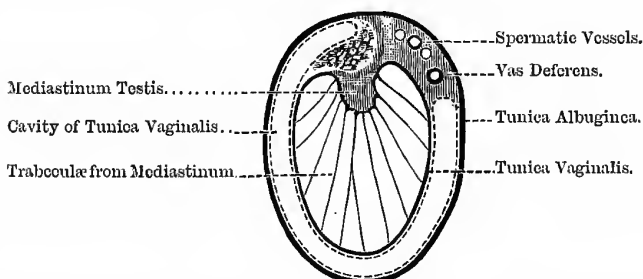
THE PELVIS—(Continued).

THE TESTICLE.

The Testicle: its Coverings.—The testicle lies obliquely in the scrotum, suspended by the spermatic cord and its coverings. It is oval in shape, and its front, sides, upper and lower ends, are smooth; but the *posterior* part, where the spermatic cord is attached, and where the vessels enter and leave, is not smooth, and it is not covered by the serous membrane (*visceral layer* of the

Fig. 221.

SECTION OF TESTICLE.



tunica vaginalis). The gland itself is enclosed in a strong capsule—the *tunica albuginea*—which is a dense, fibrous membrane. At the posterior part this membrane is reflected into the interior of the gland, forming an incomplete vertical septum, called the *mediastinum testis*, or *corpus Highmorianum*. From the front and sides of this septum, trabeculae are given off, which pass to be attached to the inner surface of the tunica albuginea. In the

spaces thus formed the seminal ducts begin (Fig. 221). Covering the inner surface of the tunica albuginea is the *tunica vasculosa*, or the *pia mater* of the testicle. It consists chiefly of a delicate plexus of blood-vessels. Towards the posterior part we find the epididymis. This is an elongated crescent-shaped mass adapted to the upper end and the outer side of the posterior border of the testicle; its upper end is larger than the rest and is called the *globus major*, its lower end the *globus minor*, and the part between the *body* of the epididymis.

Seminal Tubules.—The tubules begin in the lobules of the gland; the lobules lie in the spaces formed by the septa from the mediastinum testis. Passing from the lobules we have—(1) The *vasa recta*; these enter the fibrous tissue of the mediastinum, and form a network called (2) the *rete testis*; (3) from this spring a number of ducts, called the *vasa efferentia*; (4) these in turn form the *coni vasculosi*, which, together, form the (5) *globus major* of the epididymis. Next comes (6) the *body* of the epididymis, and then (7) the *globus minor*, or tail; from which (8) the *vas deferens* springs. About the junction of the *globus minor* and *vas deferens*, the *vas aberrans* of HALLER is occasionally found.

The Development of the Testicle.—The testicles arise in the abdominal region, in close relation to the Wolffian body, and from the same cell mass. The Wolffian bodies are often called the *primordial kidneys*. The permanent kidneys arise in relation to the dorsal aspect of the Wolffian duct. This duct is converted into the *body* and *globus minor* of the epididymis, the *vas deferens*, and the common ejaculatory duct. The *vas aberrans* is probably a persistent portion of the original tubules of the Wolffian body. The *vasa efferentia*, *coni vasculosi*, and the *globus major* of the epididymis are produced from a special cell mass, distinct from, though close to, the Wolffian body. Its tubules then become continuous, on the one hand with the *rete testis*, and on the other with the *body* of the epididymis. In the female this mass of cells become converted into the *par-ovarium* of KOBELT (= the organ of ROSENMÜLLER, or the *epiöphoron* of WALDEYER). The *vasa efferentia* of the male would in this way correspond to the *par-ovarian tubules*, KOBELT'S tubes, and also GAERTNER'S duct of the female. KOBELT'S tubes are attached, by one end only—to

GAERTNER'S duct—the other end being free and closed. GAERTNER'S duct is the remains, in the female, of the duct of the Wolffian body, the middle part only of this duct being persistent in that sex. The tubes of the par-ovarium and KOBELT'S tubes open into it. It lies at first in the broad ligament of the uterus, and then becomes incorporated with the wall of the uterus and vagina, upon which last it is lost. It is important to keep these points in mind as they explain the origin of cysts of the epididymis.

The scattered remains of the Wolffian body constitutes the organ of GIRALDÈS or the paradidymis of WALDEYER, and forms perhaps the commonest source of tumours and cysts of the epididymis and testicle. The same also is true of the kidney; for it is easy to see how parts of the Wolffian body might become incorporated with the permanent kidney, or with the testicle, since both are developed close to the original Wolffian body. In connection with this, compare, and observe, the similarity in appearance between "cystic degeneration" of the kidney and the same condition of the testicle, probably in both cases due to the incorporated remains of the Wolffian body.

Coverings of the Testicle as it lies in the Scrotum.—(1) The skin, which is thin and dark-coloured, and usually in rugæ; (2) the superficial fascia, which in this region is peculiar in the fact that it contains no fat, but has a layer of non-striped muscular fibres—the *dartos muscle*; (3) the inter-columnar or external spermatic fascia; (4) the cremasteric muscle or fascia; (5) the infundibuliform fascia; and (6) the *tunica vaginalis*, the special serous membrane of the testicle, which under normal conditions is entirely cut off from the peritoneal cavity. It consists of a visceral and a parietal layer; the *visceral* layer covers the front, sides, upper and lower ends of the testicle; but towards the posterior part it is reflected from the testicle, and becomes continuous with the parietal layer. The *parietal* layer is attached to the infundibuliform fascia by loose areolar tissue, and is more extensive than the visceral part, extending higher up and lower down than the testicle. The *tunica vaginalis*, like other serous membranes, is a closed cavity, and it is of importance to remember that it is towards the *front* and *sides* of the testicle, so that the testicle seems suspended at the back of this serous sac; in the normal condition, however, its two layers

are in contact. In the condition of **inversion**, the testicle occupies the front of the scrotum, the whole organ being turned round, so that the vas, instead of being behind the cord, is in front of it. The testicle is sometimes found in the perineum attached to the tuber ischii. The processus vaginalis usually accompanies it. When this is the case, it communicates with the peritoneal cavity; and it is important to remember this in excision of the gland, lest fatal peritonitis be set up.

Lymphatics of the Testicle.—The lymphatics from the testicle proper pass to the lumbar glands, those from the integuments of the scrotum pass to the horizontal set of the superficial glands in the groin. In encephaloid cancer, therefore, the lumbar glands will be first enlarged; but when the integuments become involved the glands in the groin will also enlarge. In chondro-sarcoma the secondary growths will be found in the internal organs—as the lungs and liver; but it should be noted that this form of sarcoma of the testicle is also very usually readily diffused by the *lymphatics*. In superficial affections, therefore, of the scrotum, as eczema, syphilitic skin affections, soot wart (“**chimney-sweep's cancer**”), paraffin wart, etc., the glands in the groin will be affected; but in affections of the testicle, the *lumbar glands* enlarge.

Nerves of the Testicle.—The testicle is supplied by the *spermatic plexus* of the sympathetic; this is derived from the *renal plexus*, which is in turn immediately derived from the solar plexus. This brings the testicle into a very close relationship with the kidney and solar plexus, and hence probably the pain in the testicle so frequently found in kidney affections, and pain in the kidney in some affections of the testicle. The reason why the testicle is thus supplied is because it is developed in the abdomen, just under the kidney, but afterwards descends to the scrotum (see vol. ii., page 342).

VARIETIES OF HYDROCELE.

1. Hydrocele of the Tunica Vaginalis consists of a collection of serous fluid *within the cavity* of this sac; as the fluid accumulates it forms a swelling at the front and sides of the testicle, and also passes up in front of the spermatic cord towards the external

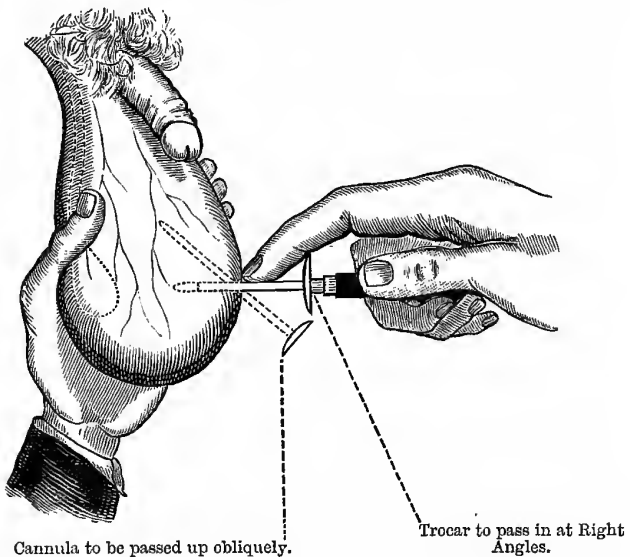
abdominal ring; it also passes down below the testicle, so that if well marked, the testicle cannot be felt at the bottom of the scrotum. The **fluid** is pale yellow or amber coloured, sometimes a little greenish, and without smell. It is neutral in reaction, and the specific gravity is about 1024, and it contains about 6 per cent. of albumen, as shown by heat and nitric acid, and further contains fibrinogen. This fluid contains more albumen and fibrinogen than the fluid of ordinary dropsy. In old chronic cases, it may have a glistening or sparkling appearance, from the presence of cholesterine crystals, the result of fatty changes. There is an **acute form** of hydrocele which is associated with acute epididymitis; it is painful and tender, and the skin over it is red. The fluid in this case may coagulate spontaneously. Acute hydrocele is not so common with acute *orchitis*, as the strong tunica albuginea lies between the inflamed structure and the serous covering; but in epididymitis the inflamed tubules are just outside the tunica vaginalis. It is very probable that the usual chronic hydrocele is associated with some inflammation of the testicle proper, evident or obscure. In hydrocele the fluctuation is free and uniform all over and in all directions, and this distinguishes it from cystic tumours of the testicle. In tapping this distended sac, grasp the tumour with the left hand, so that the testicle lies in the centre of the palm, and hold the trocar in the right hand, with the index finger about three-quarters of an inch from its tip, to prevent it going too far, and with the thumb on the flange to press the cannula home, and then plunge it with a sudden thrust into the most prominent part of the *front* of the scrotum, so as to avoid injury to the testicle, which is usually at the posterior part; it is first plunged in perpendicularly, and then made to pass obliquely upwards (Fig. 222).

In tapping for vaginal hydrocele, carefully avoid large veins, and make sure that the case is not one of **inversion of the Testicle**—*i.e.*, the testicle lying in front, instead of at the back, of the scrotum, or that it is not fixed there by previous inflammatory adhesions; further, make sure that the condition is chronic. The **position** of the testicle may be made out by the aid of a candle and stethoscope, as well as by the “testicular sensation” produced when the place where the testicle is situated is squeezed. When

the sac is emptied, a solution of iodine is injected, to set up inflammatory action, to coat the serous surfaces with a layer of non-secreting lymph, and prevent the re-accumulation of the fluid. It may also cause adhesion of the serous surfaces, but this is not an essential part of the cure, which is the destruction of the serous surfaces and deposition of non-secreting lymph. The most convenient preparation of iodine to use is *Tinctura Iodini* of the

Fig. 222.

TAPPING VAGINAL HYDROCELE.



The Surgeon's thumb ought to have been placed on the flange of the Cannula.

old Edinburgh Pharmacopœia; of this solution inject about two drachms, taking care that it *all* gets in, and taking care also to keep it all in—*e.g.*, if the piston of the syringe fits badly, it might pass behind it; and further, unless the cannula is in the cavity of the tunica, it may be injected into the cellular tissue of the scrotum. This tincture is stronger than the *Tinctura Iodi* of the British Pharmacopœia, but not so strong as the liniment. By firmly squeezing the cord, the sudden intense pain may be lessened

somewhat, or a solution of cocaine may be first injected; some use carbolic, as it is less painful—a drachm, liquified in glycerine. After the solution is injected, *the scrotum must be well shaken*, so as to bring it in contact with every part of the secreting surface. If, however, a communication exists between the cavity of the tunica vaginalis and the general peritoneal cavity, irritating fluids, like tincture of iodine should not be injected lest they set up fatal peritonitis.

In the passage of the trocar, the following are the Structures pierced—(1) The skin, (2) the superficial fascia and dartos, (3) the inter-columnar fascia, (4) cremasteric fascia, (5) the infundibuliform fascia, and (6) the parietal layer of the tunica vaginalis.

The method of injection must not be used in **children** nor in **feeble old men**. In the child, hydrocele is often congenital, when the iodine would pass into the abdomen and set up peritonitis; in these cases, treat by discutient lotions (such as hydrochlorate of ammonia), acupuncture or simple withdrawal of the fluid, or lastly, incision and drainage. A somewhat similar method may be used in the old and debilitated—simple withdrawal or acupuncture may cure the condition, especially in cases where the patient has previously lived in a warm climate, as the West Indies.

Differential Diagnosis between Hernia and Hydrocele of Tunica Vaginalis:—

Scrotal Hernia.

1. Tumour oblique in shape and direction.
2. The protrusion lies in front of and covers the spermatic cord, and testicle can be felt at the bottom of the scrotum. Scrotum cannot be folded up on the abdomen as in hydrocele (CHIENE).
3. An impulse is imparted to the tumour if the patient coughs: gurgling sound at attempts at reduction: percussion note clear (if intestine), but dull if omentum.
4. No transparency on examination by the transmitted light of a candle.

Hydrocele.

1. Tumour; oval or pyriform and *began at bottom of scrotum*.
2. The constituents of the cord can be felt free in the inguinal canal at the external ring, but the testicle cannot be felt easily at the bottom of the scrotum, but is situated behind, and in large collections at the upper part.
3. No impulse on coughing: no gurgling at attempts at reduction: percussion note dull. It is possible to feel the rounded *upper end* of the tumour.
4. Is usually transparent when thus examined.

The "translucent" appearance can be very well imitated, by holding up one's thumb in front of a candle flame and looking through it.

Double Hydro-Sarcocele, in a young man, is most probably due to secondary syphilis, but it might be tubercular; the history, personal and family, together with the appearance of the patient, will help one to decide. An ordinary vaginal hydrocele and an encysted hydrocele may be found on the same side of the scrotum. Occasionally a **fatty tumour** is found in the scrotum, developed from the extra-peritoneal fat. The mass of fat travels down under the spermatic coverings, and may completely envelop the testicle, simulating an ordinary vaginal hydrocele. Another curious fact is that it may become detached from the extra-peritoneal fat, and be grafted on to the tissues of the scrotum, and continue to grow there, although entirely cut off from its original source of blood supply.

2. **Congenital Hydrocele**.—In this case, the *processus vaginalis* has remained open, so that a communication exists between the tunica vaginalis and the peritoneal cavity (see Fig. 201). It is dull on percussion, never tense, disappears on even, steady pressure, gradually and without slip or gurgle; it descends slowly, even though the finger be kept on the external abdominal ring. It feels soft and even, and no irregularity or gurgling when handled. To treat—(1) Discutient lotions; (2) withdrawal of the fluid; or (3) a truss to close up the aperture.

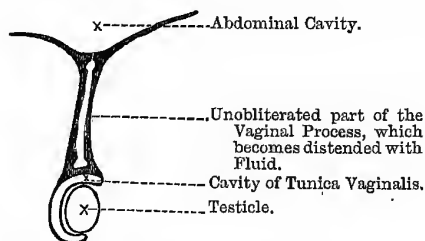
3. **Infantile Hydrocele**.—In this form the *processus* has only closed at the internal abdominal ring (see Fig. 202). It does not disappear on pressure, or when the patient lies on his back, and there is no gurgling on handling. It is probably due to inclusion of the fluid, when the obliteration occurred, at the internal ring. Note that, in infants, a hernia may be translucent as well as a hydrocele, but will be tympanitic on percussion. Treat as last; one may also inject iodine, if *sure that the communication with the abdomen is closed up*.

4. **Encysted Hydrocele of the Cord**.—A dropsy of small unobliterated portions of the *processus*; it is obliterated at different parts of its course, leaving one or more closed sacs, which become distended with serum (Fig. 223). Or the *processus* may be closed

at the upper and lower parts only, leaving the central part unobliterated; this condition is simply an arrest of a natural process. Normally, the processus first closes at its upper part, and next at its lower part, and finally in the intervening portion. Encysted hydrocele of the cord may also be a dilated portion of the tube of the "organ of GIRALDES," or sometimes a cyst formed by effusion into the cellular tissue. The proper form is usually found in the child and on the *right* side, as this side is the last to close, and hence all congenital defects of this nature are more common on this side. The fluid often contains spermatozoa; the swelling is cylindrical, its upper end being as large as the lower, and the testicle is readily felt below, and is quite distinct from the swelling.

Fig. 223.

ENCYSTED HYDROCELE OF CORD.



To show the condition of the Processus Vaginalis in Encysted Hydrocele of the Cord.

5. Encysted Hydrocele of the Epididymis.—It may contain pure serum, but is more usually serum with a mixture of seminal fluid. The cyst is usually attached to the head of the epididymis; it may be pedunculated and form a "loose body" in the tunica vaginalis. This form does not surround the testicle, nor has it the shape of the tunica vaginalis; it is tense and globular, and the testicle is in front, or to one or other side, or below. Its origin is doubtful: it may be (1) from the vasa efferentia; (2) an enlargement of the "Hydatid of MORGAGNI," which is the remains, in the male, of the duct of MÜLLER; (3) the organ of GIRALDES—the remains of the Wolffian body, or its duct, the *vas aberrans*; and (4) from KOBELT'S tubes. This condition corresponds to the parovarian cysts in the female. At first the fluid may not contain

spermatozoa; but later, when a communication is formed between the cyst and the vasa efferentia, spermatozoa are found. Of course, if the cyst arise primarily in one of the tubules of the vasa efferentia, spermatozoa will be found from the very first. The **fluid** contains only a trace of albumen, and effervesces on adding an acid, from the presence of alkaline carbonates. In some cases it is opalescent, the opalescence being due to the presence of seminal fluid, and the spermatozoa may be recognised under the microscope. When this is the case, it is called a **spermatocele**.

In diagnosing **Scrotal Tumours** the first thing is to ask one's self two questions—(1) Does it belong to the scrotum? or (2) Does it come from the abdomen? In **pure Scrotal Tumours** the swelling has *no neck*, as shown by grasping the tissues near the external abdominal ring between the finger and thumb, on both sides of the body, for the sake of comparison; by doing so we get above the upper end of the tumour, and feel the constituents of the cord healthy and free, *e.g.*, in hydrocele, hæmatocele, and simple forms of sarcocele; but in malignant tumours of the testicle and tubercular testicle, the *vas deferens* is often thickened to the size of a goose quill, instead of being the usual size and feel of whip cord. Tumours of the **Testicle** itself, with the exception of cystic sarcoma, are solid; swellings of the **Tunica Vaginalis**, are practically always *fluid*. Tumours that come from the **Abdomen** have a *neck*, which can easily be felt when the tissues near the external ring are grasped between the finger and thumb. **Hydrocele of the Cord** is cylindrical and sausage-shaped, the testicle is quite free below, and the upper end can usually be felt in the abdomen at the internal ring, and there is no gurgle on manipulation, as in a reducible hernia.

I shall now give a short **RÉSUMÉ** of the chief ways of treating **Hydrocele**:—

I. In the Child. — (a) In the **Congenital** form a *truss* is the proper treatment, after returning the fluid, so as to obliterate the communication into the abdomen. Should anything further be required, use cold evaporating lotions or simple tapping with a fine trocar, but never inject iodine, as it would pass up into the abdomen and probably cause peritonitis. When once it becomes

“*infantile*” treat as below. (b) In the **Infantile** variety, which is probably due to inclusion of fluid, use cold, evaporating, discutient lotions, as—

℞	Ammoniaë Chloridi,	gr. xxx.
	Aceti Destillati,	ʒj.
	Spiritûs Rectificati,	ʒj.
	Aquam ad,	ʒj. Miscæ.

Acupuncture may be employed, using a needle to puncture the sac of the tunica vaginalis; or simple tapping and support afterwards. In very obstinate cases you may inject iodine, if you are quite sure that the opening into the abdomen is completely shut off.

II. In the Young and in Middle-Aged Adults.—The cause may have to be treated—usually some chronic inflammation of the testicle. *After* the condition has become *chronic*, then use palliative measures at first, *i.e.*, simple tapping, and the wearing of a suspensory bandage afterwards. If this does not cure, then resort to the radical cure—tapping, followed by the injection of iodine; where this fails, from the great thickness and non-collapsible nature of the wall of the sac, then use simple antiseptic incision and drainage, carefully stitching the tunica vaginalis to the skin, in order that the sac may granulate from the bottom.

III. In the Old and Debilitated.—Do not interfere, unless it is causing trouble and increasing. If interference is necessary, then adopt palliative measures, as repeated simple tapping, and the wearing of a suspensory bandage between times; where it is small, one may use acupuncture. In the form of hydrocele, so frequent in warm countries, simple tapping seems to cure. It is only in exceptional cases that the radical cure by free incision and drainage, or the injection of iodine, should be attempted in old men (BRYANT).

In Hæmatocele (that is, a collection of blood in the tunica vaginalis), the shape is usually globular; it is *heavier* than hydrocele, and hard or doughy to the touch, with obscure fluctuation, as the wall is very thick and rigid, opaque to transmitted light, and dull on percussion. If tapped, a coffee-coloured fluid is drawn off, consisting of altered blood. It may arise from a traumatism, when there will be marks of bruising in the tissues of the scrotum; or it

may arise from a puncture of a vein during tapping for hydrocele, or from the bursting of a varicose vein.

Treatment.—(1) Rest, general and local, with elevation of the scrotum, and gentle elastic pressure to stop the bleeding point; the application of cold may also be tried, if necessary, but elastic pressure is the chief point. (2) Later, it may be tapped, and the serum and broken-down clot drawn off. (3) In obstinate cases, it may be necessary to lay open the tunica vaginalis, under very rigid antiseptic precautions, turn out the blood clots, secure any bleeding points, stuff the wound, and make it heal from the bottom by granulation. (4) In *very* bad, old-standing cases, excision of the testicle has been practised.

Cirsocele or Varicocele is a varicose enlargement of the spermatic veins (the *plexus pampiniformis*). The pampiniform plexus is formed by the remains of the veins of the Wolffian body, and passes out at the hilus or posterior border of the testicle. This would correspond to the hilus of the ovary, or, as it is called, the paroöphoron, which represents the remains of the Wolffian body. In women who have born children, this plexus often reaches an immense size. The left side is most frequently affected—(1) Because the vein of that side is longer, (2) it is apt to be pressed upon by fæculent accumulations in the sigmoid flexure of the colon, and (3) it enters the left renal vein at right angles. Mr HOWSE believes that in cases of varicocele there is an actual development of new veins, and that this probably accounts for the condition in many cases; in fact, that it is not a mere dilatation of pre-existing veins. It is usually found in young adults up to twenty-five years of age. The mass is pyramidal in shape, with the base below; it feels like a “bag of worms,” and it may be possible sometimes to see the dilated and tortuous veins. Occasionally the veins rupture and may cause death from great extravasation. When the patient lies on his back, and the scrotum is elevated, the swelling disappears; if then the finger be pressed on the external ring, and the patient made to stand up, it will return in spite of the pressure, without the sensation of anything slipping past the finger. This distinguishes it from hernia. The affected testicle is often a little smaller than the other, but it will not cause impotence, as long as the other testicle is sound. Professor CHIENE classifies varicoceles *clinically*

into—(1) Those that give rise to mental trouble, and (2) those that do not: in the former only, under ordinary circumstances, should any operation be performed. The degree of mental trouble produced has no relation to the *size* of the varicocele.

Treatment.—1. **Palliative.**—A well-fitting suspensory bandage, with the removal, if possible, of the conditions that tend to keep up undue pressure in the veins—*e.g.*, constipation. Cold bathing of the genitals morning and evening is also valuable. In some *special* cases, where the cause was chiefly obstruction to the venous circulation in the abdomen, Mr SPENCE recommended a light truss—the truss was not to interrupt the circulation, but to act like a valve and support the column of blood above: in ordinary cases a truss would be hurtful. 2. **Radical.**—In cases (1) where there is much mental trouble on account of the varicocele, (2) for admission to public services, and (3) where there is great pain, frequent seminal emissions, and atrophy of the testicle.

Operations.—Open Methods.—With strict antiseptic precautions, make a short incision over the cord, towards the outer aspect, or behind. When the veins are exposed, separate them carefully from the other constituents of the cord, especially the vas deferens and the spermatic artery, free them for some distance, pull them out at the wound, and tie them above and below in one or more bundles with strong catgut, and cut off the part between the ligatures. At the same time, do not be afraid to cut off a good large piece of the loose and pendulous scrotum; this will brace it up afterwards, and act as a suspensory bandage. Insert a small drainage tube, stitch the skin, and dress. PROFESSOR ANNANDALE was the first to advise and perform the operation of *excision of the veins, combined with removal of a portion of the skin of the scrotum.*

Bennett's Operation.—W. H. BENNETT believes that to cure varicocele it is necessary to *shorten the cord.* An incision is made exposing the thin fascia surrounding the varicocele, which fascia must not be divided. The veins are then tied *en masse* at the lower part, the ends of the ligature being left long. A second ligature is next passed round the veins at the upper part and tied with a *single knot*, which is kept tight by an assistant. The portion of the veins between the ligatures is then excised, and the upper ligature tightened, the ends being left long. After the

bleeding has ceased the ligatured stumps of the varicocele are brought together, and retained thus, by knotting the ends of the upper ligature to those of the lower. The ligatures are now cut short and the operation completed.

Subcutaneous Method.—Another plan is by **multiple subcutaneous Catgut Ligatures**, with or without division between the ligatures. VELPEAU'S method of obliteration, by means of a hare-lip pins and twisted suture, cannot be recommended; and the same remark applies to VIDAL'S method of twisting by means of specially-constructed needles and silver wire.

Structures divided in the open method are—Skin and dartos, inter-columnar fascia, cremasteric fascia, and infundibuliform fascia. **Vessels and Nerves.**—Twigs of the ilio-inguinal and genito-crural nerves; branches of superficial external pudic and cremasteric arteries.

Sarcocele.—By this is meant merely a solid enlargement of the testicle. This may be—(a) **Simple**, usually a form of chronic inflammation following acute orchitis, and affecting all parts of the testicle equally; it is smooth and uniform, and may be painful and tender. (b) **Tubercular**, affecting the epididymis and the vas deferens in the first instance, which become craggy and nodular, with perhaps soft spots here and there. (c) **Syphilitic**, a tertiary phenomenon appearing two or three years, or longer, after infection; the cord is healthy, the body of the testicle alone being affected, and is very often accompanied by hydrocele (*hydro-sarcocele*). There are two forms—(1) It may be a diffuse orchitis, or (2) it may be in the form of a localised gummatous tumour. (d) **Tumours of the Testicle, simple or malignant**—as encephaloid cancer, cystic sarcoma, and chondro-sarcoma. Cancerous tumours are usually of a soft and rapidly-growing form, and begin in the body of one testicle, from proliferation of the epithelium of the seminiferous tubules, and very rapidly infect the lumbar glands. Sarcomata begin in the connective tissue of the gland or the tunica albuginea; it is most common in children under ten years. The so-called enchondroma of the testicle is a sarcoma which develops cartilage (*chondrifying sarcoma*), and the secondary growths in the internal organs retain the characters of the primary. In adults the sarcoma is often *cystic*. Cartilaginous tumours of the testicle spread by means of the *lymphatics*, as well as by the veins. The rapid

growth, the great size often, the lobulation, the presence of cysts, and unequal consistence of the tumour, as well as the absence of all inflammatory symptoms are suspicious. Double primary malignant disease of the testicle is always *lympho-sarcoma*. When there is marked lumbar pain, it probably indicates infection of the lymphatic glands in that region. Simple forms of sarcocele are rarely larger than a goose's egg. Gout and malaria may also cause enlargement of the testicle.

The following Table (after ERICHSEN) may assist the memory:—

Simple Sarcocele.	Tubercular Sarcocele.	Syphilitic Sarcocele.
1. In the acute stage the cord is thick and tender; in chronic, may be enlarged from dilated vessels. It is a chronic inflammation following acute orchitis, and all parts are affected.	1. Vas deferens affected and cord thickened.	1. Cord healthy, but vessels dilated.
2. Epididymis may be swollen, but body chiefly affected; it is hard, smooth, and uniform, and rarely fluctuates.	2. Epididymis chiefly affected: it is craggy and nodular with spots of softening, and may be adherent to tissues of the scrotum. Body rarely affected.	2. Body alone principally affected in both forms; hard, nodular, and irregular. Softening and abscess rare.
3. Painful and tender.	3. Sometimes tender, but rarely painful. Tubercle in other parts.	3. No pain or tenderness; the testicular sensation soon lost.
4. History of injury or gonorrhœa.	4. History of struma or phthisis.	4. History of syphilis two or three years before.
5. Hydrocele sometimes.	5. Rare.	5. Common.
6. Scrotum healthy, and usually only one testicle affected.	6. In early manhood: both often affected; adheres to scrotal tissues and bursts externally.	6. Scrotum healthy.

Note the two forms of syphilitic disease—(1) A diffuse interstitial orchitis. In this case the outline is uniform, smooth, and even; both are affected. It is apt to occur in the young and the middle-aged, and soon after the infection. (2) As a localised gummy tumour. In this case the outline is irregular, nodular, or craggy; it occurs later in life, and longer after the infection.

THE BLADDER.

This is one of the pelvic viscera. When *empty* it lies entirely within that cavity behind the pubic bones, and is of a *triangular* form; when *moderately distended* it is of a *rounded* form, and when *fully distended* it is *ovoid* in shape and rises above the pubes and enters the hypogastric, or even the umbilical, region. Its relations to the prostate and rectum are given elsewhere. The Nerves of the bladder are derived from the vesical and prostatic plexuses sent off by the *hypogastric plexus*, which supplies its upper part, and the *fourth sacral* nerve; in this way the neck of the bladder is brought into very close relation with the anus, the importance of which has been already pointed out (see vol. ii., page 446). The vesical plexus contains a large proportion of *spinal* nerve fibres.

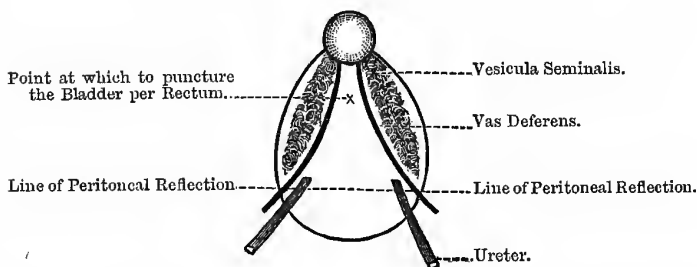
Puncture of the Bladder.—This operation may be performed either from the rectum or above the pubes; and in doing so, advantage is taken of the anatomical facts that there is no peritoneum on the base of the bladder (that is, the part towards the rectum) nor on the antero-inferior surface. The part left uncovered varies with the amount of distension of the organ. In tapping above the pubes, the bladder must be distended, so as to raise the reflection of the peritoneum well above the pubes; in tapping from the rectum, it must be done exactly in the middle line, and close to prostate. The part which may be punctured with safety is triangular in shape, each side of the triangle being about an inch-and-a-half in length (the external trigone), and has the following boundaries:—On **either side** are the vasa deferentia (a vas on each side), and immediately beyond these, the vesiculæ seminales; the **base** of the triangle is formed by the line of reflection of the peritoneum on to the rectum, and is about an

inch and a quarter from the base of the prostate; at the **apex** of this triangle the prostate gland is situated (Fig. 224). If the puncture be not in the middle line, the vasa deferentia or vesiculæ seminales may be injured; and unless well forwards towards the apex of the triangle, the peritoneum might be punctured. This operation may be rendered necessary for the retention of urine in cases of stricture of the urethra, or in cases of rupture of the same structure where it is impossible to pass a catheter.

The **objections to puncture per rectum** are—(1) That it is inconvenient to keep a tube in the rectum; (2) that it may cause abscess between the bladder and rectum, and leave a permanent fistula; (3) the vesiculæ seminales or peritoneum may be injured, causing peritonitis; and (4) that it may set up pelvic cellulitis.

Fig. 224.

BASE OF BLADDER SHOWING THE TRIGONE.



Unless the finger can be passed well beyond the prostate, and feel the fluctuating base of the bladder, do not attempt it. The cannula, too, can only be kept in for a limited period per rectum; and further, it cannot be done at all in cases of enlarged prostate, nor in the Negro races (BELL). It may be done in cases of impermeable stricture in the young adult, or in complete rupture of the urethra. During an extensive experience of nearly half-a-century, Mr SPENCE only performed the operation twice.

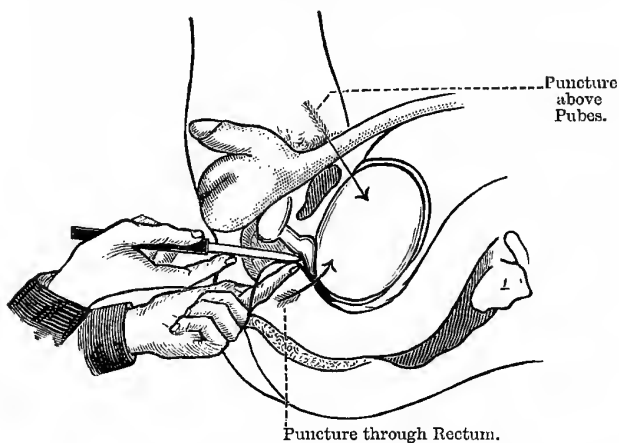
In performing this simple operation, pass two fingers into the rectum till the base of the prostate and the bladder beyond is distinctly felt; the point of puncture must be in the middle line, and as near the base of the prostate as possible. Next, take a

curved trocar and cannula, the point of the trocar being *drawn well back within the cannula*, and press the point of the cannula against the bulging base of the bladder, then make the trocar enter the bladder, and after that push the cannula also into the bladder, withdraw the trocar and let the urine flow out. The cannula is then tied into the bladder for forty-eight hours, after which a catheter may be passed by the urethra, as the rest has probably diminished the swelling and inflammation of that canal. A similar instrument may also be used to puncture above the pubes,

Fig. 225.

SPENCE'S OPERATION.

(After SPENCE.)



in which case it is better to make a small incision first, partly through the abdominal wall, and afterwards insert the trocar through the incision. A much better instrument, however, to use is the pneumatic aspirator.

Mr Spence's Method of Puncture from the Perineum.—The part opened is the membranous portion of the urethra, and the guide is the apex of the prostate, felt per rectum. The left index finger is passed into the rectum and made to rest on the apex of the prostate, and its pulp against the distended membranous

urethra; an ordinary straight bistoury is then plunged into the perineum in front of the anus, with its back towards the rectum and the point directed obliquely upwards, as if to cut into the apex of the prostate, which guides to the membranous part of the urethra (Fig. 225). When this is opened the urine escapes; the Surgeon may then tie in an ordinary lithotomy tube, or pass a bougie down to the obstruction and divide the stricture on its point. In this way not only is the retention relieved, but the obstruction is divided at the same time. Mr COCK'S operation closely resembles Mr SPENCE'S.

Cock's Operation—or opening the urethra behind the stricture, at a point where it is healthy, and in front of the prostate—in the membranous portion, as the stricture is usually in front of this point. The patient is tied up as for lithotomy. The operator then passes his left forefinger into the rectum, and places it upon the apex of the prostate, and then passes a broad, sharp-pointed, double-edged knife straight down to the apex, *exactly* in the middle line of the perineum. The external wound is then enlarged somewhat, the knife withdrawn, and a probe-pointed director with a handle passed into the wound through the urethra, and into the bladder; along this, as a guide, a tube—SYME'S perineal catheter or a female catheter—is passed, fitted with rings, whereby it can be tied into the bladder. The object of this operation is that it does not presumably cure the stricture.

Rupture of the Bladder usually occurs when it is full, and the patient receives some form of injury. It may rupture in two situations—(1) At the parts not covered by peritoneum, and (2) at the parts covered by peritoneum. In the first case the urine is effused into the cellular tissue round the viscus, but *outside* the abdomen; in the other, the urine passes into the peritoneum. In **treating** rupture of the bladder, various plans are open to the Surgeon—(1) Keep the bladder empty by siphonage, and give the patient plenty of opium, in case of peritonitis; (2) a catheter may be passed through the rent of the bladder, and the abdomen washed out with a warm antiseptic; (3) drain the bladder by perineal cystotomy; and (4) abdominal section. In cases of intra-peritoneal rupture, the wound should be stitched with LEMBERT'S suture. The sutures must only go through the peritoneal and muscular coats,

and one should be inserted just beyond each end of the wound. Try if it is water-tight before closing the abdominal wound. In all abdominal sections the bladder must be first emptied lest it be cut by the Surgeon, as occasionally happens.

Clinical Points.—(1) The internal trigone is the most sensitive and the most vascular part of the bladder, and it is always smooth, as there is no submucous coat, the mucous membrane being attached to the muscular coat directly; it is also the lowest part of the bladder, and as the bladder contracts, a calculus, if present, is pressed against this very sensitive part. (2) Bladder affections react on the rectum, through the pelvic portion of the sympathetic and the fourth sacral nerve. (3) When obstructions exist to the outflow of urine, if the obstruction is not too complete and the patient not debilitated, the wall of the bladder hypertrophies, and the bundles of muscular fibres stand out like the columnæ carneæ of the heart, forming "**fasciculated bladder**;" these fasciculi may become coated with phosphates, and lead the Surgeon to think that the bladder contains a stone. (4) But if the obstruction is too complete or the patient debilitated, the wall of the bladder dilates and thins, and may rupture. (5) In cases of hypertrophy, the mucous membrane is sometimes forced through between the bundles of muscular fibres, forming sacculi—"sacculated bladder;" the walls of the sacculi contain no muscular fibres. (6) The sacculi lodge residual urine, which is apt to decompose and deposit phosphates; in this way encysted calculi are formed.

HÆMATURIA.

Blood in the Urine may be derived from the Urethra, Bladder, or Kidney:—

1. **From the Urethra.**—In this case it may pass independently of urine or micturition; it may pass with the first few drops, with or without the passage first of a long clot, the size and shape of the urethra. It may also pass with the last few drops of urine, when it comes from the prostate or neck of bladder; it will be impossible to distinguish profuse prostatic from vesical hæmorrhage by mere examination of the urine, as the blood flows into the bladder from the prostate.

2. **From the Bladder.**—The blood in this case is not diffused through the urine, and often comes almost pure at the end of micturition, or just after the urine; further, it is often accompanied by flat or irregular shaped clots, and the blood retains more or less its red colour. The reason of this is evidently the higher specific gravity of the blood: average specific gravity of the urine is 1020; of the blood as a whole, 1055; of the red corpuscles alone, 1088—hence, of course, they sink to the bottom of the bladder.

3. **From the Kidney.**—The blood is intimately mixed or diffused through the urine, producing, when copious, a dark porter-like colour; when scanty, a uniform “smoky” tint; it is often accompanied with long narrow blood clots or “casts” of the ureters. The dark colour of the blood is due to the hæmoglobin being changed to methæmoglobin, by the action of the acid in the urine.

Tests for Blood.—(1) Perhaps the best and most delicate test is the microscope. (2) Tincture of guaiacum and an ethereal solution of peroxide of hydrogen (= “ozonised ether”) develops a beautiful light blue colour. **NOTE.**—Urine containing blood does not always give this reaction; and if iodide of potassium be present, a blue colour will be produced, even though no blood be present. (3) **Hæmin crystal test.**—Treat the blood with hydrochloric acid, or else use glacial acetic acid and common salt, when rhomboidal, yellowish-red crystals are formed. (4) **HELLER’S test.**—Heat the urine, and then add a solution of caustic potash, and heat again; the clot first formed is redissolved, and the solution thus obtained is dirty green by transmitted, but blood-red, by reflected light.

Tumours of the Bladder.—Observe the differences between the hæmaturia caused by sarcoma and that due to cancer. In **Sarcoma** the hæmorrhage usually *precedes* the other symptoms, such as pain and frequency of micturition. As in **Papilloma**, at first it occurs in attacks, the urine between times being quite clear; the attacks gradually become more frequent and last longer, until at last the urine is never quite free from blood. In **Cancer** the pain and frequency of micturition usually precede the appearance of blood in the urine. The bleeding from papilloma is more abundant than from stone; there is pain in stone, but very seldom in papilloma. If in doubt about the presence of a tumour, and if no tufts of

papilloma are found in the urine, then perform perineal cystotomy, and use digital exploration. If the presence of a tumour is certain, then open the bladder supra-pubically and remove it, as the perineal incision is too small, except for a small, single tumour. If the tumour be large, or if they are multiple, they cannot be removed by the perineal incision. If in doubt between tumours and foreign bodies, use the endoscope; to do this the urine must be clear, and free from pus or blood.

PYURIA.

Pus in the Urine may also be derived from the Urethra, Bladder, or Kidney:—

1. **From the Urethra.**—Here it is passed before the urine, or escapes independently of micturition. If it come with a gush, it is probably due to the bursting of a prostatic abscess into the urethra, but the pus in this case may also flow back into the bladder.

2. **From the Bladder.**—The pus is equally diffused through the urine, which is foul-smelling and *alkaline*; the alkali present renders the pus “ropy,” and holds it in suspension. It is usually mixed with mucus, and the pus is always present.

3. **From the Kidney.**—When first passed it may be diffused through the fluid, but it soon settles down into a layer at the bottom of the glass, which is sharply marked off from the supernatant fluid; the urine is *acid*, not decomposed, and does not contain mucus. In cases where the cause is calculous pyelitis, the appearance of pus will be intermittent—present at one time but absent the next.

Note the differences between blood and pus, from the bladder and kidney respectively. Speaking generally—

- (1) Blood from the bladder is not diffused through the urine, whereas pus is.
- (2) Blood from the kidney is diffused through the urine, whereas pus is not.
- (3) Pus in alkaline urine = bladder. Pus in acid urine = kidney.
- (4) Pus constantly present = bladder. Pus at times only = kidney.

Tests for Pus.—(1) *Liquor potassæ* makes it ropy and gelatinous, so that it cannot be poured out drop by drop. (2) The microscope and acetic acid. The acid clears up the pus cells and shows the tri-partite nucleus. Acetic acid coagulates mucus.

Calculi.—The common forms of stone are—

1. **Urates**, probably with some **Uric Acid** as well—it is flattened and ovoid, the colour varies from dark brown to light fawn, the surface is fairly smooth or slightly warty, and it is of medium hardness. Not only is this the most common form of stone, but it also forms the commonest nucleus for other stones, as the oxalic; it usually comes from the kidney. In children the nucleus, or the entire calculus, may consist of urate of ammonium, forming a grey-fawn or pipe-clay coloured stone.

2. **Phosphates**: white and chalk-like, very soft and brittle, and egg-shaped. It usually consists of phosphate of lime (*“stellar phosphate”*) and triple phosphate (*“ammonio-magnesian phosphate”*), and is known as the *“fusible calculus.”* Pure triple phosphate is rare except as a coating on instruments tied into the bladder, or on foreign bodies, and round other stones that have been in the bladder long enough to set up cystitis. The phosphatic nucleus is vesical from the first, and the urine is alkaline and stinking; it may be deposited in one of the sacculi of a sacculated bladder, as the urine there tends to decompose.

3. **Oxalate of Lime.**—This forms a round, densely hard stone, with a vitreous fracture, rough and tuberculated on the surface, and very dark in colour from the hæmatin of the blood, as it is apt to cause bleeding. It may come from the kidney in the first instance, or be formed round a uric acid nucleus; like the uric acid, it is found in clear acid urine. It is known as the *“mulberry calculus.”*

Chemical Characters of Calculi:—

1. **Uric Acid**—

(a) Exposed to the blow-pipe, it grows black and slowly burns away, leaving only a slight ash, which is alkaline to test paper.

(b) Add nitric acid and evaporate to dryness, when a red

residue is left. Cool, and add ammonia, when we get a magnificent purple (*murexide test*).

(c) Dissolve in caustic potash and heat. No smell of ammonia.

2. **Urate of Ammonia**—

(a) Like urates generally, is soluble in hot water, but deposited on cooling.

(b) Dissolve in caustic potash and heat. Smell of ammonia.

(c) Apply the murexide test to demonstrate the presence of uric acid, or—

(d) Add hydrochloric acid, and you get a precipitate of uric acid.

3. **Phosphate of Lime**—

(a) Add hydrochloric acid. Dissolves without effervescence. To this solution add ammonia, which will produce a white gelatinous precipitate. To a part of this—

(b) Add a drop of neutral ferric chloride. A yellowish-white precipitate of ferric phosphate is thrown down. To another part—

(c) Add ammonium oxalate. White precipitate of oxalate of lime.

4. **Triple Phosphate**—Ammonio-magnesian phosphate—

(a) Heat in blow-pipe. Chars and gives off a smell of ammonia, and finally fuses.

(b) Heat with caustic potash, when ammonia is set free and the magnesia falls as a white flocculent precipitate.

(c) Soluble in hydrochloric acid, but is thrown down, when this solution is neutralised with ammonia, as a crystalline precipitate.

5. **The "Fusible Calculus"**—mixture of phosphate of lime and "triple phosphate"—

(a) In the blow-pipe, fuses very easily without being consumed; at the same time ammonia and water are driven off.

(b) Dissolve in hydrochloric acid, and add ammonia in slight excess. White precipitate of the mixed phosphates thrown down.

6. Oxalate of Lime—

(a) Dissolve in hydrochloric or nitric acid, and add ammonia. White precipitate, insoluble in acetic acid.

(b) It is insoluble in acetic acid.

(c) Ignite a portion. Carbonic oxide is given off, and carbonate of lime left behind. To this add hydrochloric acid, which will produce copious effervescence.

(d) Dissolve in hydrochloric acid, neutralise with ammonia, and add ammonium oxalate. White precipitate of calcium oxalate.

Coccygeal Body.—This is a body about the size of a small pea, in close connection with the terminal twigs of the middle sacral artery. LUSCHKA named it the **coccygeal gland**; but ARNOLD has shown that it is not a gland, but that it simply consists of the dilated and tortuous twigs of the middle sacral artery. The muscular coat of the artery is much thickened, and there are also layers of peculiar cells. The body is invested by connective tissue, in which nerve cells are embedded. Branches of the **ganglion impar** of the sympathetic pass to the coccygeal body. A body of similar structure, called the **inter-carotic body**, is situated in the angle of the bifurcation of the common carotid artery in the neck. LUSCHKA termed this body the *ganglion caroticum*.

It has been thought that many of the **congenital sacro-coccygeal tumours** may originate in this body. These tumours are fibro-cystic in nature, and are often attached to the bone or to the pelvic viscera; they have no relation to spina bifida, as they originate between the coccyx, or sacrum, and the rectum, and below the levator ani. On account of their deep connections they are very difficult to remove, and should not be interfered with rashly. They consist of closed round vesicles, simple, branched, or varicose, lined by round or polygonal cells, resting on a basement membrane; in the foetus the cells are columnar and ciliated.

The matrix consists of much delicate connective tissue, through which many thin-walled, cavernous-like vessels run. Occasionally, the remains of a belated foetus may be found in it. The cysts vary in size from a pea to a chestnut, and contain a glairy transparent fluid, like ropy mucus. These tumours are also known as "thyroid-dermoids," or congenital adenomata. They probably arise in connection with the post-anal gut and neurenteric passage (SUTTON).

It is possible that some of the **congenital cysts in the neck** may be due to a cystic degeneration of the inter-carotic body; to such LUSCHKA gave the name of *hygroma colli*. Others have supposed that many of the *branchial cysts* develop from this body, while others again believe that the congenital fibro-cystic tumour of the neck may have a similar origin. It is more likely, however, that this latter condition may rather result from an intra-uterine transformation of a subcutaneous naevus. This growth must be distinguished from the true *hydrocele colli*, which is beneath the deep fascia, and often passes from the neck into the thorax or axilla.

CHAPTER XLIV.

THE PELVIS—(Continued).

THE RECTUM.

THE rectum extends from the left sacro-iliac synchondrosis, obliquely downwards and to the right, to the middle of the sacrum, and then curves forwards and inwards in front of the sacrum and coccyx. From the tip of the coccyx it continues its course downwards and forwards for about an inch and a half to the prostate in the male, and back of the cervix, vagina, and perineal body in the female. Opposite the prostate it makes another turn, passing downwards and slightly backwards to the orifice of the anus; the anus is situated about an inch and a half in front of the tip of the coccyx.

It will be observed, therefore, that although it is called the "rectum," it is anything but *straight* in the human subject, although it is so in the lower animals. It should be further noted that the rectum does not pass downwards and backwards from the *tip of the coccyx* to the anus, but from the *back of the prostate*—an inch and a half from the tip of the coccyx.*

The rectum is divided into three parts—the **first part** extends from its commencement to the second or third sacral vertebra; the **second part**, from the second or third sacral vertebra to the tip of the coccyx; the **third part**, from the tip of the coccyx to the anal orifice—this part being about an inch and a half in length. The length of the entire rectum is about eight inches.

* As the anus is about an inch and a half *in front* of the tip of the coccyx, it is evident that the usual description is, to say the least, misleading.

Relations.—The **first part** is surrounded by peritoneum, which also binds it to the front of the sacrum as far down as the second or third sacral vertebra—this fold being known as the *meso-rectum*; in front of this part is the recto-vesical pouch of peritoneum and a part of the bladder in the male, but in the female the pouch of DOUGLAS, the uterus, and the upper part of the posterior wall of the vagina. The **second part** is only partially surrounded by the peritoneum, the front and upper part of its sides alone being in relation to it; at its lower part the peritoneum is reflected, in the male, on to the back of the bladder, but in the female on to the posterior wall of the vagina. On the *anterior* surface of the rectum the peritoneum is about three and a half or four inches from the anus; on the *posterior* surface it is fully an inch higher up. In the male, the base of the bladder (*trigone*) lies immediately over this part, and between the two are the vesiculæ seminales and the vasa deferentia; but in the female the posterior vaginal wall is in relation to it. This part is attached by loose areolar tissue to the front of the sacrum and coccyx, and is also in relation to the visceral layer of the pelvic fascia. The **third part** has no relation to the peritoneum, but is in close relation to the pelvic fascia and the levatores ani muscles, which support this part of the rectum; the rectal layer of the pelvic fascia joins the rectum about four inches from its lower end, and at the same time ensheaths the levatores ani; further, the recto-vesical layer of the pelvic fascia (or the recto-vaginal layer in the female), is also in relation to the rectum. The prostate gland in the male is close to the commencement of this part, while in the female the perineal body is in relation to its anterior surface throughout its whole extent, because at this point the rectum and the vagina diverge. The anal part of the rectum, or the part in the region of the sphincters, may be said to begin at the back of the prostate and pass downwards and slightly backwards to the external orifice; this part is invested by the internal sphincter, the levatores ani, and the external sphincter. This last part of the rectum is of great Surgical importance (see vol. ii., page 482).

The Arteries of the Rectum are five in number—(1) The superior hæmorrhoidal, the continuation of the inferior mesenteric into the pelvis; it soon divides into two branches, which pass down,

one on each side of the rectum. (2) The two middle hæmorrhoidal arteries, from the anterior division of the internal iliac, or from the inferior vesical. (3) The two inferior hæmorrhoidal, from the internal pudic. At the upper part of the rectum the arterial branches pass transversely round the gut, outside or between the muscular coats, but at the lower part they pierce the muscular coat and pass downwards *longitudinally* in the sub-mucous cellular tissue. This fact is of importance in WHITEHEAD'S operation for piles. At the external orifice both arteries and veins form anastomosing *loops*.

The Veins of the Lower End of the Rectum, in common with those of the prostate, bladder, and uterus, form a dense plexus just under the mucous membrane; this plexus is peculiar, as it forms the connecting link between the systemic and the portal system of veins—part of the blood reaching the inferior vena cava and part the portal vein. It will be seen, therefore, that there must be a considerable pressure on the feebly-supported hæmorrhoidal plexus of veins, as the portal vein and its radicles have no valves; this fact is looked upon as a predisposing cause of hæmorrhoids, or piles.

Lymphatics of the Rectum.—Those from the integument surrounding the orifice of the anus pass to the horizontal set of inguinal glands; this set will, therefore, be enlarged in squamous-celled epithelioma affecting the verge of the anus. The vessels of the gut itself, above this point, pass first to the pelvic glands around the internal iliac artery, and thence to the lumbar glands. The **Nerves** of the rectum are derived from the hypogastric plexuses of the sympathetic, in common with the other pelvic viscera.

Hæmorrhoids.—These consist of a varicose dilatation of the inferior hæmorrhoidal veins, with thrombosis, and subsequent inflammation. At first it is a mere dilatation, but by-and-by the blood clots, and the connective tissue around hypertrophies.

1. **External Piles** are a dilatation of the subcutaneous veins around the anal orifice; their walls are thickened, and the connective tissue around is also thickened. There are various subdivisions—(a) The anal tab, a solid, flaccid fold of skin; (b) external piles proper, a soft, blue, compressible swelling, covered by skin—this is a dilated vein; and (c) the same structure inflamed and œdematous.

2. **Internal Piles.**—It should be remembered that piles are purely anal growths, being usually situated just opposite the sphincter. Internal piles are also dilated veins, but very often arteries and capillaries are developed in them, as a secondary result to fibrous change. They have been divided into two chief groups—(a) The *longitudinal* or *fleshy pile*.—It is “blind” usually, *i.e.*, non-bleeding, sessile, and of a dusky brown tint. (b) The *globular pile*.—This very often forms the bleeding pile, because it is much more vascular, and may be blue or red, according to the relative proportion of capillaries and veins, and may be pedunculated. When ulcerated it forms a deep red sessile projection, like a strawberry, covered with granulation tissue, from which the blood comes. There is no *arterial pile* proper, though fibrous tissue nodules, with arteries passing into them, are frequently enough developed as a secondary result. The blood is often arterial, as the arteries and capillaries may give way, from the great back pressure. The blood may come from the bursting of a small vein, or from the granulations covering the “granular” or “strawberry pile.” Some persons have “fits of the piles;” by this is meant that the piles are inflamed, as from cold and wet, and protrude through the sphincter. Others, again, tend chiefly to bleed, and thus escape attacks of inflammation.

To Treat.—No operation of any kind is to be undertaken for the cure of internal or external piles, when the piles in question are inflamed. Always treat them, in the first instance, as a physician. The patient should keep his bowels comfortably easy, with senna, sulphur, or castor oil, or glycerine enemata. A favourite preparation is a mixture of confection of pepper and liquorice powder. He should also wash the parts with cold water after every motion, and night and morning as well. An ointment, say, of hamamelis, should also be used to smear the parts to prevent irritation, and at the same time to exert an astringent effect.

External Piles are usually simply snipped off with the scissors; if the raw surface is large, a stitch may be introduced. There is no danger of hæmorrhage, as the inflammation around has condensed the tissue, and the veins are thrombosed and blocked off from the circulation. Internal piles are rarely so occluded,

and, therefore, they could not be simply snipped off with safety, as the risk of hæmorrhage is great—just as in a burst varicose vein of the leg.

Internal Piles must always be treated by constitutional management first. If this fails, then (1) the clamp and cautery may be used, or (2) they may be crushed, or (3) they may be ligatured—well adapted for cases of solitary prominent piles. (4) The piles, with the mucous membrane from which they spring, may be removed, after the manner introduced by WHITEHEAD. There is less pain after the clamp and cautery than after ligature; there is also less tendency to reflex retention of urine. Further, there is no large mass left to slough off. The risks of hæmorrhage, septicæmia, and pyæmia are about equal in both cases. It is said that in ligature, a vein may be punctured, and lead to hæmorrhage and septic absorption. In ligaturing, many Surgeons cut through the mucous membrane over the *lower half* of the pile. In this way the ligature cannot slip, the mass tied is smaller, and consequently the slough separates sooner. The mucous membrane of the upper half of the circumference is not cut, as the arteries enter at that point. The crushing operation is rarely performed. In making the first visit to the patient after the operation, take a catheter with you, and inquire if he has passed water since the operation. If not, draw it off.

Whitehead's Operation.—This method may be used where the piles are very diffuse, ill-defined, and all round the gut. The patient is anæsthetised and placed in the lithotomy position, and the sphincters are paralysed by stretching; and then, by the use of scissors and forceps, an incision is made through the mucous membrane, just within the verge of the anus (Fig. 226), the membrane separated all round for a little way up, till healthy membrane is reached above the piles, and then this cuff of mucous membrane is split at one side and excised, and the gut above brought down and stitched to the mucous membrane left at the verge of the anus (Fig. 227). The gut must not be cut off transversely all at once, but simply snip by snip, securing the vessels and introducing the sutures as you proceed. The sutures are of carbolised silk, or of horse-hair; the wound is dressed with iodoform, and a dose of castor oil is given on the morning of the fourth day—probably

the most disagreeable part of the operation. The objection to this operation is the absence of drainage, as the wound is entirely covered over; and it is a septic region, so that the chances of septicæmia are probably greater than in other operations. In case adhesions form later, it is better to pass a bougie a week or so after the operation.

Fig. 226.

WHITEHEAD'S OPERATION—FIRST STAGE.

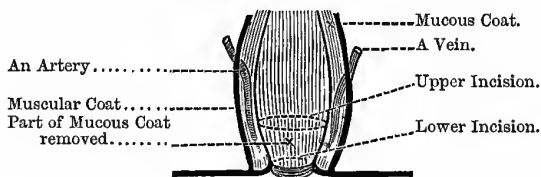
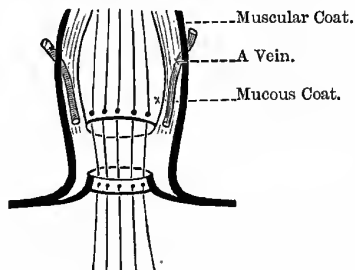


Fig. 227.

WHITEHEAD'S OPERATION—SECOND STAGE.



Sutures passed ready for tying.

Treatment by Injection.—By this method, it is said, the pain and confinement attendant upon the other methods of treatment are obviated. Various fluids may be used, though carbolic acid is probably the best, the usual strength being 1 in 10, though stronger solutions may be used. For the 1 in 10 solution, take of carbolic acid twelve grains, and glycerine and water of each one drachm. The patient is made to strain the piles down, and is then placed on a couch in the knee-elbow position; after this, by means

of a hypodermic syringe, an injection is slowly made into the centre of each pile, of from two to five minims. After the injections the piles are returned, and must be *at once returned* should they come down afterwards.

The advantages of this method are said to be that the patient is not laid up, suffers practically no pain, and runs no risk to life from hæmorrhage, tetanus, erysipelas, or pyæmia.

Region of the Sphincters of the Rectum.*—The **External Sphincter** is a thin layer of fibres immediately beneath the skin and surrounding the anus. It is elliptical in form, and half-an-inch in breadth on each side, and is attached behind to the coccyx, and in front blends with the other muscles at the central point of the perineum. The **Internal Sphincter** is a muscular belt surrounding the lower part of the rectum, an inch above the anus; it is half-an-inch in depth and two lines thick, and is simply a thickened part of the circular muscular fibres of the rectum. About a couple of inches or so above this point there is a circular fold of mucous membrane containing muscular fibres, which is sometimes called the *sphincter tertius*.

The diseased conditions met with in the neighbourhood of the external and internal sphincters and levatores ani, and kept up and aggravated by their action, are numerous and important. Among these we may specially mention—(1) **Fistula in ano**, which is chiefly prevented from healing by the unrest produced by the sphincters. (2) **Anal Ulcer or Fissure**—the nearer this condition approaches the sphincters the greater the pain, and the less tendency it shows to heal. (3) **Piles**, which are purely anal growths, being situated in the region of the sphincters. It should be noted that the “region of the sphincters” is not a mere circle, but is a canal of some depth, from half-an-inch to an inch in length. The external sphincter is supplied by the fourth sacral nerve principally. This same nerve, it will be remembered, also supplies the skin between the coccyx and the anus, the levator ani, and the neck of the bladder. The communications explain very clearly the effect of anal affections on the bladder, *e.g.*, retention of urine after ligature of piles; it also explains the symptoms of

* This corresponds to Dr SYMINGTON'S “Anal Canal.”

Fissure of the Anus. In this condition the anus is very much contracted, from spasm of the sphincter; towards the *posterior* part, where the fissure is usually placed and where it gives rise to most trouble, is often seen a *single* pile, and at the base of this, as a rule, we find the fissure. The fissure runs longitudinally, and very often a little ulcer is found at its upper end; the floor of the fissure is formed by the sphincter, and a twig of the fourth sacral nerve is believed to be exposed and irritated, causing the intense pain. The pain is two-fold—(1) That caused directly by the passage of fæces over the raw surface of the fissure; and (2) the reflex pain lasting some *hours* after defecation, because, as the anus closes, the fissure is squeezed, the nerve irritated, and causes sudden action of the levators. This action and reaction goes on for hours, like the swinging of a pendulum, until the sphincter gradually calms down. To the finger the fissure feels soft and velvety, and shaped like the button-hole of a shirt.

Treatment.—Local applications are of little use, but the most useful is an ointment of one part or more of the subacetate of copper to four parts of zinc ointment, to be used as a suppository at night after the bowels have acted. **Operative.**—(1) Give the patient chloroform *deeply*, and, with the two thumbs, forcibly over-stretch the anal aperture. (2) Another plan is to paint the surface of the ulcer with cocaine, then inject a few drops of the same solution just under its base, and introduce the index finger into the rectum with a straight probe-pointed knife, cutting to the point (see Fig. 121, page 36), and draw the edge of the knife along the fissure, so as to divide its base for one-eighth of an inch in depth. If the Surgeon chooses he may also forcibly stretch the anus at the same time. The plan of transfixing the base of the ulcer with a *sharp-pointed* curved bistoury, with the finger in the rectum to protect its walls from the point of the knife, must be avoided, as the finger might be pricked and the Surgeon inoculated with syphilis, to say nothing of other poisons in this neighbourhood.

Prolapsus Recti.—This condition is most common in children, from the fact that the mucous coat is much looser than in the adult; the rectum is nearly straight, more vertically placed, and partly an abdominal organ in the child; and lastly, worms and

polypi are more common in childhood. In the child, too, a narrow meatus, phimosis, adhesions between the prepuce and the glans, and stone in the bladder, are also common causes of prolapse; as a rule the mucous membrane alone is prolapsed, forming a red limpet-shell-shaped mass with an opening at the apex. Sometimes, in the child, the whole thickness of the gut may be prolapsed, when a cylindrical, sausage-shaped florid mass is formed; the part prolapsed is the part just *above* the region of the sphincters, the very lower end being too firmly fixed to allow of prolapse. It is more apt to happen in the child, because the gut is straighter and its attachments looser than in the adult. The projecting mass may be stragulated by the sphincter, and become gangrenous.

Stricture of the Rectum.—This may be (1) Simple, or it may be (2) Malignant.

Simple.—May be caused by syphilitic, dysenteric, or other ulceration of the rectum, or after operations on the lower end of the gut. Simple fibrous is usually about the junction of the rectum with the sigmoid flexure. In syphilitic cases, the finger usually easily reaches the stricture. In tubercular ulceration, distinct induration is rare.

Malignant.—Usually squamous-celled epithelioma, when it occurs at the verge of the anus, but columnar-celled when higher up. Observe, that if there be a healthy piece of bowel between the stricture and the anus, the stricture or ulceration is probably cancerous; but if the bowel between the anus and the stricture is not healthy, but scarred or seamed, the stricture or ulceration is probably syphilitic. Mr BRYANT has pointed out, that when the stricture is quite low down, and easily within reach of the finger, the anus is often patulous; but when the stricture is high up, beyond the reach of the finger, the rectal wall is expanded or “**ballooned.**” This, he states, is present in all cases of *chronic* stricture. It is probably due to atrophy of the walls of the gut from disuse, and the retention of flatus.

Symptoms of Stricture.—(1) Constipation, alternating with diarrhœa, persisting over a long period, in an elderly person, is always ominous. (2) Burning pain and tenesmus, due to attempts to get rid of the foreign mass in the rectum. There are also

colic-like pains in the abdomen. (3) Blood and mucus in the stools. (4) Patulous anus, or "ballooned" rectum. (5) Tape-like motions. (6) Pain down the thigh, probably from the fact that the malignant mass has involved the branches of the sacral plexus. (7) Detection of the stricture by digital examination.

To Treat malignant stricture we may either perform colotomy or excise the rectum. Colotomy may also be necessary in some forms of non-malignant stricture.

The Finger in the Rectum may feel the following—(1) The temperature of the part, as indicating the existence or otherwise of inflammation of the rectum itself, or the parts near, such as the prostate. (2) The trigone of the bladder separated from the finger by the wall of the rectum, with the rectal and recto-vesical layers of pelvic fascia, with a packing of cellular tissue between. (3) The vesiculæ seminales and vasa deferentia, especially if enlarged, as in tubercular disease. (4) The prostate gland, about an inch and a half within the anus. (5) The membranous part of the urethra passing from the apex of the prostate. (6) The triangular ligament proper, as a tight band stretching between the rami of the pubes and ischium. (7) State of the sphincters and anal reflexes, the contraction of the anus on the finger is slower and feebler than in health, in crushes of the spinal cord. (8) Diagnosis between prostatitis and inflammation of the neck of the bladder; if of the prostate, there will be swelling, tenderness, and heat felt per rectum.

Other things that may be felt are — fissure or ulcer of the anus, the internal opening of a fistula, a catheter in the membranous urethra, folds of HOUSTON, fæcal accumulations, stricture, piles (in the anal region), polypi (higher up); in the child we may feel the sound in the bladder, or a stone by the bimanual method; and lastly, ovarian, uterine, and pelvic tumours. In relation to the prostate gland, it is important to note whether it is hypertrophied; also note the nodular feel, with soft spots here and there, characteristic of tubercular disease, and the large size and pulpy feel of encephaloid cancer sometimes met with in young boys. In regard to the vesiculæ seminales and vasa deferentia, the chief point to note is the existence or not of tubercular disease. It is also possible to feel the obturator foramen, and

of importance, therefore, in the obturator form of hernia. The sacrum, coccyx, spines, and tuberosities of the ischium.

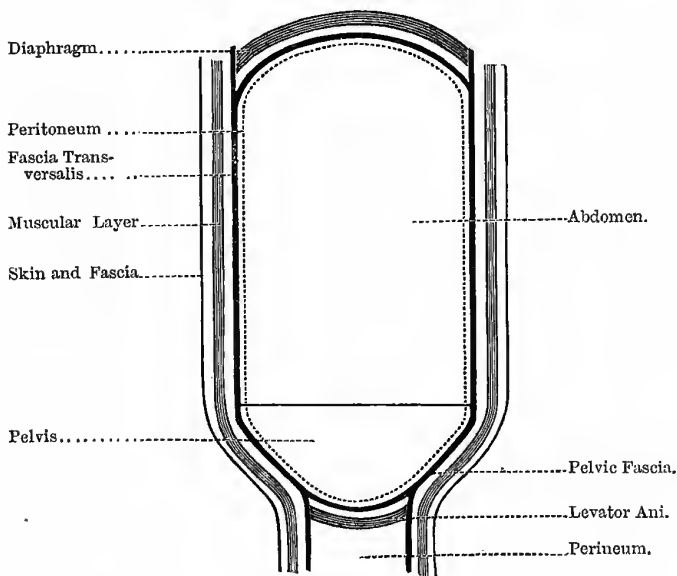
Excision of the Rectum.—This operation may be performed for malignant disease, provided the patient is not too old or exhausted, if the finger can be passed beyond the disease, and if the diseased mass is freely movable, showing that it has not infiltrated neighbouring parts, especially towards the base of the bladder; it should be remembered, however, that the prostate itself is mobile, and thus is apt to deceive the Surgeon. Probably the best way would be, first to pass a bougie into the urethra, and then note if the finger in the rectum moved the handle of the bougie while trying to move the rectum from side to side. The patient must get a purgative the day before the operation, and the bowel must be thoroughly emptied by an enema on the morning of the operation. The patient is placed in the ordinary lithotomy position, the anus dilated, and a sharp-pointed bistoury is passed into the rectum, the point being brought out at the tip of the coccyx, and the parts between the anus and the coccyx divided by a single cut exactly in the middle line. If necessary the coccyx may be excised to give more room. During the operation all bleeding vessels must be seized at once by WELLS'S forceps. Ligatures are then passed into the two sides of the wound whereby the edges may be held apart during the subsequent steps. An incision is next carried round the anus from the margins of the wound, and the gut then separated from its posterior attachments by means of the finger and scissors. The sides are next dealt with, and then the gut is pulled backwards and carefully separated from its anterior connections, having previously passed a sound into the male bladder, and the finger into the vagina if the patient be a female, to act as guides. The gut itself must now be divided; this may be done by the *écraseur*, scissors, or the thermo-cautery. Two and a half or three inches may be removed without wounding the peritoneum; and if the bladder be full, the peritoneal pouch is less likely to be drawn down than when that viscus is empty. According to HARRISON CRIPPS it is useless to attempt to bring down the mucous membrane of the divided gut to the anus, as the stitches always give way. The vessels are all to be clamped with WELLS'S forceps, which are then to be left on for forty-eight

hours. The wound must be washed with chloride of zinc solution and sprinkled with iodoform; it is left to heal by granulation. The causes of death are chiefly peritonitis, pelvic cellulitis, and hæmorrhage. The bowels must be kept quiet from ten to fourteen days by proper feeding and opium.

The Pelvic Fascia.—This fascia consists of a *parietal* part, covering the walls of the pelvic cavity, and a *visceral* part, which

Fig. 228.

GENERAL STRUCTURE OF ABDOMEN.



connects the various pelvic viscera with each other and with the walls of the pelvis; the whole visceral layer is sometimes known as the recto-vesical fascia. The **parietal part** is attached to the brim of the true pelvis and the posterior surface of the pubic bones, and passes down into the pelvis, covering the obturator internus muscle, and is attached to the spine and tuberosity of the ischium; on the posterior pelvic wall it covers the pyriformis muscle and the sacral plexus of nerves, but is behind the internal

iliac artery, the gluteal, sciatic, and pudic branches of which have to pierce it, in order to escape from the pelvis; but the obturator artery does not pierce it, as it passes over the upper border of the parietal layer. The **visceral part** is given off from the parietal layer, on a line with the spine of the ischium and the back of the pubes, the point where the two diverge being known as the "white line." The most anterior part passes backwards to the *upper* surface of the prostate gland, forming the "pubo-prostatic ligament," and then passes on to the bladder, as the anterior true ligament of that viscus. The latter part divides into three layers; the most superior forms the lateral true ligaments of the bladder, the middle passes between the base of the bladder and the rectum (the recto-vesical layer), while the most inferior—the rectal layer—passes under the second and third parts of the rectum, and ensheathes the levator ani. The relation of that part of the parietal layer of pelvic fascia above the "white line" (the "undivided" pelvic fascia of some) to the visceral layer, has been compared to that of the wall-paper and carpet of a room; and it is this carpet which must on no account be cut in the operation of lithotomy. (Fig. 228).

Pelvic Peritoneum.—In the **Male**, it completely invests the first part of the rectum, also forming the meso-rectum to this part, or the mesentery by which it is connected to the upper part of the sacrum; it next invests the sides and anterior aspect of the second part of the rectum, leaving it about three inches above the anus, and passing on to the lower and posterior surface of the bladder. It then passes forwards upon the posterior surface of the bladder, until it reaches its summit; it now leaves the bladder altogether, enveloping the urachus and lining the anterior abdominal wall. At the sides it covers the bladder as far as the level of the obliterated hypogastric arteries.

In the **Female**, between the rectum and the uterus, the peritoneum forms a pouch called the "Pouch of DOUGLAS." It also covers a small part of the upper end of the vagina, and the cervix, body, and fundus of the uterus, on their posterior aspect; at the sides it forms the broad ligaments of the uterus. In front it passes down to the level of the internal os of the uterus, and from that point is reflected on to the posterior surface of the bladder; the

rest of its course is as in the male. The "Pouch of DOUGLAS" is subdivided into three by means of the two utero-sacral folds, formed by folds of peritoneum passing between the rectum and the uterus; each fold contains the ureter, the obliterated hypogastric artery, the superior vesical artery, and a mass of cellular tissue. The left division of the pouch is deeper than the right.

In the **broad ligament** we find—(1) The round ligament of the uterus; (2) the Fallopian tube; and (3) the ovary with its ligament—this order from before backwards; also (4) parovarium; (5) the nerves, vessels, and lymphatics of the uterus and ovary; and (6) a considerable quantity of loose cellular tissue, which is frequently the seat of pelvic cellulitis.

Inflammation of the pelvic peritoneum in the female is called pelvic peritonitis or **perimetritis**; any part of the peritoneum below the brim of the true pelvis may be affected. Inflammation of the cellular tissue, below the peritoneum but above the levator ani, is called pelvic cellulitis or **parametritis**; the cellular tissue is found in the broad ligaments, in the space between the uterus and the bladder, and in the utero-sacral ligaments, as well as between the rectum and vagina. Both conditions are usually caused by abortion, parturition, or gonorrhœa; it should be remembered that a direct communication exists from the outside into the pelvic peritoneum of the female, along the Fallopian tubes.

THE SPERMATIC CORD.

This structure extends from the internal abdominal ring, through the inguinal canal, to the back part of the testicle.

Its special **Coverings** are—(1) The inter-columnar, or external spermatic fascia; (2) the cremasteric fascia—consisting of fibrous tissue and muscle; and (3) the internal spermatic, or infundibuliform fascia, or fascia propria.

The **component parts** are—(1) The vas deferens or excretory duct of the testicle. (2) Three arteries—(a) The *spermatic*, from the abdominal aorta; (b) the *cremasteric*, from the deep epigastric; and (c) the artery to the *vas*, from the superior vesical. (3) The spermatic plexus of veins (*pampiniform plexus*). This plexus forms the chief mass of the cord, and passes up in front of the

vas; but at the upper part they collect into a single trunk, which enters the abdomen through the internal ring, terminating on the right side in the inferior vena cava, but on the left side in the left renal vein. (4) Lymphatics, which terminate in the lumbar glands. (5) Nerves—(a) The sympathetic plexus (from the *renal* plexus); and (b) the *genital* branch of the genito-crural, which supplies the cremaster muscle. This fact explains the “**cremasteric reflex**,” best seen in boys—that is, on tickling the inner side of the thigh over the distribution of the *crural* branch of the same nerve, the testicle of that side is observed to rise almost or quite up to the external abdominal ring.

The **Vas Deferens** can always be recognised by the hard, firm, whip-cord-like sensation it gives when the cord is held between the finger and thumb. It commences at the lower part of the globus minor, and ascends along the posterior and *inner* side of the testis and epididymis, and then along the *posterior* part of the cord; at the internal abdominal ring it lies to the *inner* side of the spermatic vessels, then hooks round the deep epigastric artery and descends upon the *inner* side of the external iliac vessels into the pelvis. It now passes downwards and backwards upon the side of the bladder, crossing to the outside of the obliterated hypogastric artery; it next passes to the *inner* side of the ureter and reaches the base of the bladder, where it becomes dilated and slightly sacculated, and lies, at the trigone, to the *inner* side of the corresponding seminal vesicle. At the base of the prostate it unites with the duct of the seminal vesicle to form the common ejaculatory duct; this duct runs forwards and upwards in the prostate and along the sides of the sinus pocularis, ending in a slit-like opening at the margin of the sinus in the prostatic urethra. Each vas is about two feet in length; the walls are very thick and dense, but the canal is extremely small. In describing the course of the vas, note the *five* “*inners*.” The vas deferens is sometimes **ruptured**, as the result of a sudden strain; the patient feels as if something had given way, experiences a severe pain in one or other groin, and a little while after bright blood flows from the urethra, but micturition is performed normally. Later, the cord and testicle become painful, tender, and swollen. It is usually followed by atrophy of the testicle.

Special Pelvic Blood-Vessels in Female.—**Arteries**—(1) The uterine artery, which is a branch of the anterior division of the internal iliac, and is found between the two layers of the broad ligament. It takes a very tortuous course, and its branches to the uterine walls are also spiral in direction, and preserve this feature in the substance of the uterus, and are therefore known as the “curling arteries of the uterus.” (2) The vaginal artery, also from the anterior division of the internal iliac; it is distributed to the vagina, rectum, and bladder. (3) The ovarian artery, a branch of the abdominal aorta, resembling the spermatic in the male; it reaches the ovary by passing between the two layers of the broad ligament, and, after a very tortuous course, enters its anterior border. **Veins.**—There is no prostatic plexus in the female, hence the dorsal vein of the clitoris joins the vesical plexus; the vaginal plexus empties into the internal iliac vein; while the uterine plexus is drained chiefly by the ovarian veins; the uterine veins are not tortuous like the arteries. The ovarian veins are analogous to the spermatic in the male, and terminate in like manner—the right entering the inferior vena cava at an acute angle, while the left passes *under the sigmoid flexure*, and enters the left renal vein at a right angle. In the male this fact is said to explain, partly, the frequent occurrence of varicocele on the left side, as the vein is apt to be squeezed by the faecal accumulation in the sigmoid flexure; now, in the female, faecal accumulation is still more common, and this perhaps helps to explain why it is that women so frequently complain of pain in the “left side,” in the region of the ovary—the pressure on the vein leading to chronic venous congestion of the left ovary. From the communications between the pelvic plexuses of veins and the portal system of veins, it is easy to understand why congestion of the liver, or any condition compressing the portal capillaries, should react on the pelvis, producing, as one symptom, menorrhagia.

CASTRATION.

This may be required for malignant disease of the testicle, as cystic sarcoma, chondro-sarcoma (“*enchondroma*”), and the different forms of cancerous disease, usually encephaloid; also in

“simple” conditions that have resisted local and constitutional treatment, as large hernia testis, which is a source of annoyance and discomfort to the patient, some forms of syphilitic testicle, in tubercular disease; to prevent systemic infection, and in some cases of incompletely descended or misplaced testicle.

The pubes is shaved, having first made sure of the absence of hernia on the side to be operated upon; the patient is placed upon his back with his legs and thighs hanging over the end of the table.

The instruments required are—Scalpel or straight bistoury, blunt hooks, sponges, ligatures, silk ligature for cord, aneurism needle, WELLS’s forceps, drainage tube, antiseptic dressings, scissors, chloroform, etc. The Surgeon stands between the patient’s legs and grasps the posterior part of the testicle with his left hand so as to tighten the parts in front, while his assistant looks after the other testicle.

In ordinary cases, the incision should extend from the external abdominal ring to the bottom of the scrotum, in order to ensure free access; if the tumour be large and the skin much stretched, so as to endanger its vitality—also in cases where it is involved by the malignant growth,—two elliptical incisions should be made, wide of the disease, enclosing a part of the skin of the scrotum. The tunica vaginalis should be next opened, lest an old hæmatocele may have been mistaken for a solid tumour of the testicle, and the testicle itself must be examined before attacking the cord, lest the original diagnosis may be at fault, and it is too late to remedy mistakes when the cord is divided. The testicle is then grasped with the left hand, while the coverings are shelled off with the right, and the firm fibrous mesorchium, stretching between the back of the testicle and the scrotum, divided by a touch of the scalpel. The cord is then isolated as high as thought necessary; and, in the case of malignant and tubercular disease, it will be well to open up the inguinal canal upon a director, in order to go if possible above the furthest limits of the disease.

In dividing the cord we are always warned to be careful lest it be pulled up into the inguinal canal before the vessels are tied, and so pass beyond the reach of easy ligature; the cause of this retraction is said to be the cremaster muscle. This muscle arises

from **POUPART'S** ligament, and is inserted into the spine of the pubes by a small tendon, and it is about as difficult to see how it can lift the cord above its insertion, as it is to imagine a man lifting himself off the ground by pulling upon the waistband of his trousers. The cremaster is then divided, and the cord is grasped by two pairs of **WELLS'S** forceps, as it is too slippery to be held by the fingers of an assistant, and an *aneurism* needle, with a double ligature of stout silk, gradually passed through it; the ligature is then divided, and the cord tied in two halves, or the Staffordshire knot may be used. Some tie it *en masse*. A *sharp* needle is not used to transfix the cord, lest it puncture a vein and set up phlebitis; the ligature being passed *through* the cord prevents any risk of slipping. Tie the vessels very carefully to avoid oozing, and by carefully applied pressure obliterate any cavity where the discharges can collect. The veins should be tied as well as the arteries. The spermatic artery is found in front, and the artery to the vas behind. If preferred, the vessels can all be secured separately, instead of tying cord and all in one or two parts.

The cord is then divided half-an-inch below the ligature, and the testicle liberated by the fingers, aided by a touch of the knife. All bleeding vessels are then secured, especially in the septum scroti, a drainage tube is introduced and brought out at the lowest part of the wound, and the incision closed with sutures; the tube may be kept in for forty-eight hours. Should the operation be performed for tubercular disease the vas must be separated and divided as far up as possible, the operator bearing in mind the existence of the deep epigastric artery. The possible existence also of a patent processus vaginalis must be kept in mind, especially in the young, lest the injury set up fatal peritonitis.

The dangers of the operation are—erysipelas, peritonitis, simple or septic, and septic thrombosis.

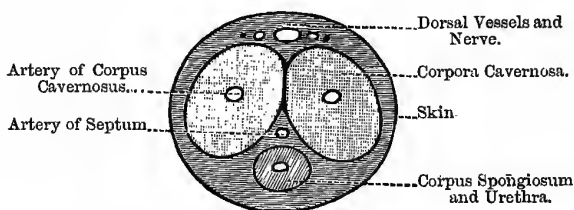
THE PENIS.

The two **corpora cavernosa** form the chief bulk of the organ; they are placed side by side above, and in the groove below is lodged the **corpus spongiosum**, which is pierced throughout its whole extent by the urethra. **CUNNINGHAM** facetiously likens

the relation of the three parts to the two barrels and ramrod of a double-barrelled gun; only in this case it is not the *barrels* that are perforated but the *ramrod* (Fig. 229). The *root* of the penis is formed by the bulb and the two *crura*. The *crura* are formed by the diverging *corpora cavernosa*, and are attached to the sides of the pubic arch; the bulb is formed by an expansion of the *corpus spongiosum*, and rests upon the anterior surface of the triangular ligament. Covering the bulb we find the *accelerator urinae* muscle, while each crus is covered by the *erector penis* muscle of the corresponding side. In front, the *corpora cavernosa* end in rounded extremities, which are overlapped by the *glans penis*—the expanded anterior end of the *corpus spongiosum*.

Fig. 229.

SECTION OF PENIS.



The *prepuce* consists of two layers—an external or cutaneous layer, and an internal or mucous, or more properly, muco-cutaneous; as a matter of fact, the so-called “mucous” layer is really *cutaneous*. The skin passes for a variable distance beyond the *glans*, and is then folded in upon itself, forming the *prepuce*; and the internal layer is attached to the sulcus behind the *corona glandis*, where it blends with the mucous membrane covering the *glans*. Below the *glans* is the *frænum preputii*, stretching from the lower angle of the meatus; in the *frænum* is a small vessel which, if wounded, may give rise to serious hæmorrhage. Over the *glans penis* the mucous membrane is quite adherent to the underlying tissue, as there is no submucous tissue. The free margin of the *prepuce*, just where the thin, red, and moist muco-cutaneous layer joins the cutaneous or outer layer, is the narrowest part of the opening

of the prepuce, and it is this narrow ring that gives rise to the trouble in phimosis and paraphimosis. It is important to note this ring in reference to the operation of circumcision; the contraction is not of great breadth, being merely narrow and ring-like; hence, all that is required is to remove this ring, and if it is not removed, it matters but little what else is taken away, the condition will not be relieved without a second operation. The skin itself is not tight, only the mucous membrane and the part where it joins the skin.

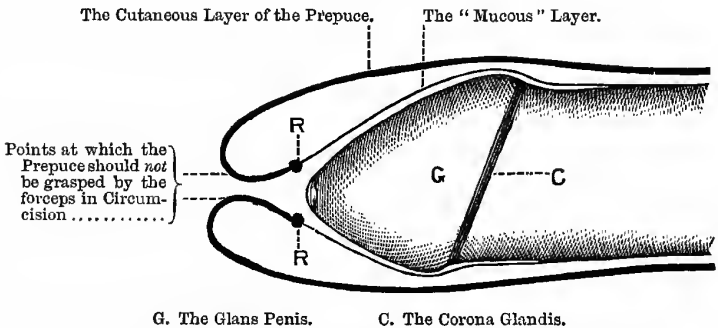
Nerves of the Penis.—The anterior branch of the perineal nerve supplies the under part of the integument of the penis, the rest of the integument—upper surface and sides—being supplied by the dorsal nerve of the penis, from the pudic. The erectile structure is supplied by offshoots from the prostatic plexus of the sympathetic; these offshoots communicate with the dorsal nerve of the penis. Now comes a curious fact: in cases where a segment of the spinal cord is destroyed, either by injury, *e.g.*, as in fracture of the spine or inflammation—*myelitis*—thus cutting off the cord from the sensorium, even though the crush or inflammation be well up into the dorsal region, so that motion and *sensation* are completely destroyed as high as the umbilicus, or even higher, *the point of the penis escapes*, and still retains its sensation. It would seem, therefore, that the *glans penis* has an entirely different sensory supply from the rest of the penis.

Now there are, at least, two possible explanations of this:—The *first* and, I believe, the most likely explanation, is that the point of the penis is supplied by the right pneumogastric; this nerve, we know, joins the solar plexus; and it is probably conducted from this along the aortic plexus to the hypogastric plexus, and from thence through the prostatic to the point of the penis. I believe also that this view receives support both from physiology and psychology. The other explanation is that the supply of the glans comes from the spinal cord through the great splanchnics (which are derived from the thoracic ganglia of the sympathetic, from the sixth to the tenth inclusive), which we know also pass to the solar plexus (*semilunar ganglia*), and could then be conveyed to the penis in the way already mentioned. The first, however is, I believe, the true explanation of this curious phenomenon.

Phimosis.—In this condition there is usually a long foreskin, the orifice of which is so contracted that it prevents exposure of the glans, and leads to the retention of the sebaceous secretion (smegma preputii, secreted by the glands of TYSON), setting up local irritation and inflammation, and may even prevent the patient making water properly. The condition may be congenital, or acquired, usually the result of inflammation or disease. There are two forms—(1) Where the prepuce is redundant—for this circumcise; and (2) where it is not redundant—for this snip the muco-cutaneous junction all round till the prepuce can be retracted, or else dilate the orifice with a glove stretcher.

Fig. 230.

PHIMOSIS.



G. The Glans Penis.

C. The Corona Glandis.

R. R. The Contracted Ring that prevents the Prepuce from being pulled back; it is also the point that should be seized by the forceps in circumcision.

Circumcision is performed for the relief of the above conditions. In performing the operation, bear in mind what has already been stated about the relations of the cutaneous and mucous parts of the prepuce. A tape, or special clamp, or an elastic tourniquet is passed tightly round the root of the penis to control the hæmorrhage during the operation. The prepuce is then pulled *backwards* slightly, till the constricting *ring* is visible, which is to be seized by a pair of catch forceps, and *then* the prepuce pulled forwards over the end of the glans; this ensures the removal of the tight ring which is the cause of the condition, and the redundant prepuce gradually clipped off. Another plan

is, with the penis in its natural position, to apply a pair of long-bladed polypus forceps (or dressing forceps) on the penis, at a level with the corona, the blades pointing forwards and downwards; the glans slipping back is thus protected, and the prepuce is sliced off by a sharp scalpel or scissors close to the forceps. The mucous layer still covering the glans is slit up along the dorsum as far as the corona with probe-pointed scissors; it must then be detached from the glans, to which it is often adherent, by means of the finger and thumb, or by a probe swept round the organ. Take care that you do not introduce the probe or one blade of the scissors into the meatus, thinking it to be between the mucous membrane and the glans. The square corners are then to be trimmed off with the scissors, and the mucous and cutaneous layers stitched together with silk, either by the ordinary interrupted or continuous suture. The patient must rest in bed for a week or ten days. In infants, sutures are unnecessary; all that is required is to wrap a strip of dry lint or iodoform gauze behind the corona to keep back the mucous membrane, and fasten it on by a figure-of-eight bandage, in the form of a cotton thread, the point where the two cones meet being the corona glandis.

Paraphimosis.—In this condition the prepuce has been drawn forcibly back, and the ring before mentioned sinks into the sulcus behind the corona glandis, and effectually prevents the replacement of the parts into their proper position; the constriction speedily causes great swelling from congestion and œdema, forming a large round collar, which is the swollen "*mucous*" layer of the prepuce, and which is placed in *front* of the constricting ring (Fig. 231). Further back the skin and subcutaneous tissue are swollen; hence, we find two swellings, and between the two a deep, narrow sulcus, at the bottom of which is the tight ring of the prepuce. In cases requiring an incision, the large collar is drawn forwards, and the point of a narrow-bladed scalpel passed into the sulcus behind it. It is usually done in the middle of the dorsal surface of the penis; but, as the vessels are there, it would probably be better to go a little to one side.

Amputation of the Penis.—The chief risk of this operation is the production of an impermeable organic stricture of the urethra at the point of section. To avoid this the corpus spongiosum must

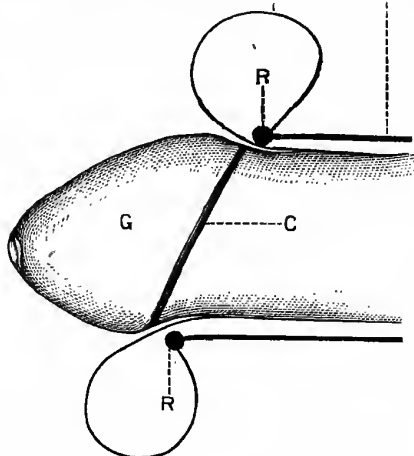
be *cut longer* than the corpora cavernosa. Some means must be adopted to control the hæmorrhage, such as the elastic tourniquet, or CLOVER'S clamp; the skin is then divided circularly, and the corpora cavernosa cut carefully through from the dorsal surface, care being taken not to wound the corpus spongiosum, which is then separated from the cavernosa in front and divided three-quarters of an inch further forwards (Fig. 232). The urethra is then split by a varying number of incisions, and stitched to

Fig. 231.

PARAPHIMOSIS.

The Collar-like Swelling formed by the Swollen and Edematous "Mucous" Layer of the Prepuce....:

The Cutaneous Layer of the Prepuce.



G. The Glans Penis.

C. The Corona Glandis.

R. R. The Contracted Ring, which is held behind the Corona and keeps up the condition.

an aperture in the lower part of the tube of skin; hence, as the skin surface contracts, it tends rather to dilate the urethral canal (Fig. 233). The vessels are then tied, and the capsules of the corpora cavernosa stitched from side to side by two or three sutures, which also include the septum—thus effectually controlling the hæmorrhage from this quarter.

The **Structures divided** are—(1) Skin; (2) just under the skin on the dorsum, the central vein with an artery, and a nerve on each side; (3) the corpora cavernosa with the pectiniform septum, with an artery to each corpus, and one to the septum; and (4) the corpus spongiosum. There are therefore five arteries to ligature—the two dorsal arteries, one for each corpus cavernosum, and one in the septum (see Fig. 229).

Fig. 232.

AMPUTATION OF PENIS.—FIRST STAGE.

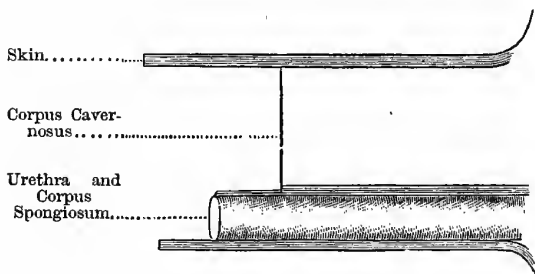
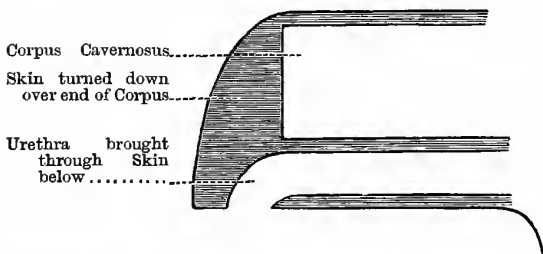


Fig. 233.

AMPUTATION OF PENIS.—SECOND STAGE.



Lymphatics of the Penis.—The lymphatics from the integument and prepuce join the horizontal set of the superficial inguinal glands; in epithelioma, soft chancre, and gonorrhoea, therefore, this group will enlarge. The deep lymphatics pass along the internal pudic vessels and end in the internal iliac group of glands.

Lymphatics of Pelvis and Abdomen.—The Pelvis—In the pelvis we find three groups of glands—(a) The *external iliac*, a chain accompanying the vessels of that name; three are placed at the beginning of the artery, just above **POUPART'S** ligament. This set of glands communicates below with the femoral, and above with the lumbar glands. (b) The *internal iliac* glands surround the vessels of the same name, and communicate with the lumbar glands; these glands receive vessels from the bladder, prostate, uterus, and penis. (c) The *sacral* glands occupy the sides and front of the sacrum; this group receives vessels from the bladder, rectum, and uterus, and also communicates with the lumbar group.

The Abdomen.—The glands of the abdomen are called the lumbar glands. They are placed on the front of the lumbar vertebræ, surrounding the common iliac vessels, the aorta, and inferior vena cava; they receive the lymphatics from the lower extremities, pelvis, testes, and most of the viscera of the lower part of the abdomen. In cases, therefore, of malignant disease of these parts they ought to be examined. If much enlarged, they may cause obstruction of the vena cava inferior or of the common iliac veins. Marked pain in the lumbar region probably indicates that these glands are implicated.

FASCIA OF THE ABDOMEN.

Fascia Transversalis.—This is an extensive sheet that lines the entire abdominal wall, lying between the muscles and the extra-peritoneal fat. Above, it is thin, and becomes continuous with the fascia lining the under surface of the diaphragm; below, it is much thicker, and is attached to the inner lip of the iliac crest, and it is here continuous with the iliac fascia—the fascia covering the psoas and iliacus in the iliac fossa. Towards the front, it is attached to **POUPART'S** ligament, external to the iliac vessels; and internal to these vessels, to the ilio-pectineal line and pubic bone behind the conjoined tendon. About half-an-inch above the middle of **POUPART'S** ligament the spermatic cord passes through it, pushing a funnel-shaped process before it (the *infundibuliform fascia*), and opposite the femoral vessels it is prolonged into the thigh, as the anterior layer of the femoral sheath. Close

to the iliac crest this fascia is pierced by the terminal branches of the deep circumflex iliac artery, ilio-hypogastric, and last dorsal nerves.

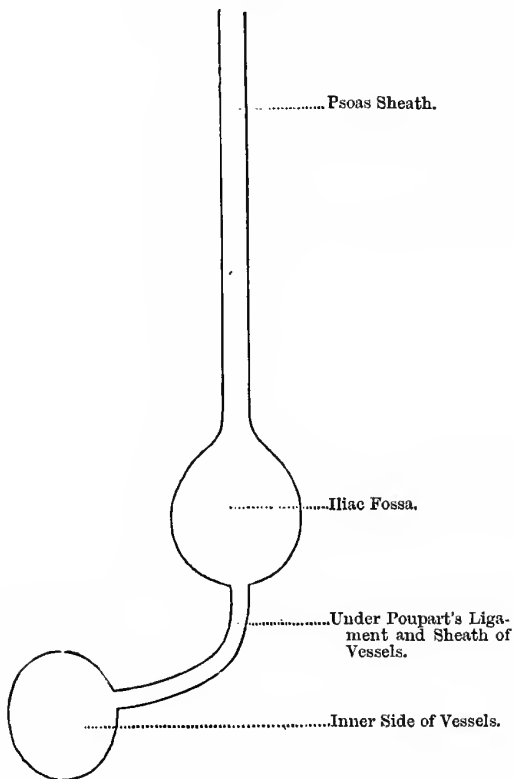
Ilio-psoas Fascia.—This is one continuous sheet also, covering these muscles in the iliac fossa. Above the level of the iliac crests, it is thin and narrow and envelops the psoas muscle, being attached **externally** to the anterior layer of the *fascia lumborum* (that layer arising from the root of the transverse processes and passing in front of the quadratus lumborum), and **internally** to the spinal column by a series of *fibrous arches* that bridge over the lumbar arteries. **Above**, it forms the ligamentum arcuatum internum. **Below**, it is more properly called the iliac fascia, and is attached to the crest of the ilium externally; and internally, after passing over the psoas, it is fixed to the brim of the true pelvis and side of sacrum. On the outer side of the external iliac vessels it is continuous with the fascia transversalis, and is, with it, attached to POUPART'S ligament, and behind the vessels it is carried down into the thigh as the posterior layer of the femoral sheath. It passes with the ilio-psoas muscle to its insertion, and blends with the fascia lata; there is no definite septum between the psoas and iliacus, and it is only loosely attached to both on the upper surface. The external iliac vessels lie upon this fascia, the anterior crural and external cutaneous nerves lie behind it, while the genito-crural nerve pierces it to join the external iliac artery.

A Psoas Abscess passes under the ligamentum arcuatum internum, and enters the psoas sheath, passes down and forms a swelling above the middle of POUPART'S ligament; it does not, as a rule, pass into the pelvis, because of the attachment of the ilio-psoas fascia to the brim, but fills up the iliac fossa. It then passes by a narrow neck under POUPART'S ligament in the line of the anterior crural nerve to the outer side of the femoral vessels; then, guided by the profunda, it passes under the femoral vessels and forms a collection on the inner side of these structures, bounded by the adductor magnus behind, the longus in front, and the gracilis internally. A fully formed psoas abscess, therefore, consists of four parts—(1) A narrow part in the psoas sheath, (2) a well in the iliac fossa, (3) a narrow neck under POUPART'S ligament, and (4) a well in the inner side of the thigh (Fig. 234).

Fluctuation will usually be obtained between the iliac and the thigh collection. The after course of this abscess varies. It may pass backwards along the internal circumflex, and point behind; but usually the psoas fascia adheres to the skin in front, and it

Fig. 234.

PSOAS ABSCESS.



points or is opened. Sometimes this adhesion does not take place, as the thigh collection often appears suddenly, when the pus then bursts through the fascia, and burrows down the limb, even as low as the heel. Sometimes, instead of forming a psoas abscess,

the pus passes between the pillars of the diaphragm with the aorta, follows the iliac vessels into the iliac fossa, and points above POUPART'S ligament, or passes into the pelvis along the internal iliac, and from that to the gluteal region along the gluteal artery, through the great sacro-sciatic notch. The source of a psoas abscess is usually spinal caries of the lower dorsal region; also, perinephritic collections of pus, or from an empyema; more rarely, from sacro-iliac disease, or suppuration following a primary psoriasis.

The Lumbar Plexus of Nerves is placed in the substance of the psoas muscle, and in psoas abscess, therefore, any or all of its branches may be irritated, giving rise to pain in the distribution of the nerve. This is specially the case with the genito-crural nerve, in young persons, the irritation thus caused producing persistent erections of the penis. The branches of the lumbar plexus are:—

1. Ilio-hypogastric } Derived from the first lumbar nerve.
2. Ilio-inguinal } Derived from the first lumbar nerve.
3. Genito-crural—Derived from the second and third lumbar nerves.
4. External Cutaneous—Derived from the second and third lumbar nerves.
5. Anterior Crural—Derived from the second, third, and fourth lumbar nerves.
6. Obturator—Derived from the third and fourth lumbar nerves.

The plexus is formed by the first three lumbar nerves, with a part of the fourth. The rest of the fourth and the fifth unite to form the *lumbo-sacral cord*. The branches leave the psoas thus:—

- | | | |
|--|---|--|
| Ilio-hypogastric | } | Pierce the <i>outer</i> border of
the muscle. |
| Ilio-inguinal | | |
| External Cutaneous | | |
| Anterior Crural | | |
| Genito-crural—Pierces the <i>anterior</i> surface. | | |
| Obturator—Pierces the <i>inner</i> border. | | |

In Dorsal Abscess, the pus follows the intercostal arteries and reaches the surface along the posterior branches. It is most often met with in upper and mid dorsal disease.

An Iliac Abscess forms a swelling between the crest of the ilium and the femoral vessels, and does not extend into the thigh at all. In this case look for disease of the lumbar spine, the sacroiliac joint, necrosis of the ilium, or suppuration around the cæcum or sigmoid flexure. In a perityphilitic abscess, and abscess round the sigmoid flexure, the pus is *not* beneath the iliac fascia but above it, and therefore does not spread down the thigh, but fills out the corresponding iliac fossa and bulges at the femoral ring. In a case of iliac abscess with, at the same time, signs of hip joint disease, it is most probably due to disease of the acetabulum.

Pelvic Abscess.—This is an abscess associated with the boundaries or contents of the true pelvis. Such abscesses may “point” in the groin in the position of an iliac abscess, in the inguinal canal, or pass into the scrotum or the labia in the female; in the one case, the cord or vas deferens is the guide by which the abscess travels, in the other, it is the round ligament of the uterus. A pelvic abscess may also escape through one of the sciatic foramina and appear as a deep abscess in the buttock; in this case the arteries that pierce the pelvic fascia will guide the pus—gluteal, sciatic, or pudic. The abscess may be due to disease of the acetabulum, suppuration in the cellular tissue in front of the bladder or around the rectum, and abscess of the seminal vesicles spreading along the vas to the inguinal canal and into the scrotum. In the female pelvic cellulitis is extremely common, and the abscess may spread up along the round ligament; the usual causes in the female are—difficult labour, miscarriage, or gonorrhœa.

Lumbar Abscess.—This is an abscess that makes its way through the muscles or fascia of the posterior abdominal wall, being guided along some of the structures that pierce it, as the ilio-hypogastric and last dorsal nerves with their accompanying arteries; it usually points in the region of the triangle of PETIT, at the outer border of the erector spinæ. It may be caused by disease of the spine, or a perinephritic abscess may open in this region, and the right side abscesses may be connected with the cæcum.

In lower lumbar and upper sacral disease the pus may enter the sheath of the pyriformis, follow the sacral nerves, and point in the buttock beneath the gluteus maximus, or pass into the

ischio-rectal fossa, or even into the rectum. In disease of the tuber ischii, the pus is found in the line of the hamstrings, as these muscles arise from that bone.

The course of the different forms of abscess depends on, or is determined by—(1) The tube or compartment of fascia in which it originally finds itself, or into which it has penetrated, as in psoas abscess. (2) Gravity, *e.g.*, a psoas, or gluteal abscess reaching as low as the knee or even the heel; or which might have been a psoas abscess had the patient preserved the erect posture, becoming a *lumbar* from the patient resting chiefly on his back. (3) The weakest parts of the fascia enclosing the abscess, or it may detach it from a part where it is least firmly adherent, as a psoas passing into the pelvis posteriorly. (4) The presence of the fascial sheaths round arteries and veins through muscular layers—*e.g.*, an abscess from hip disease passing to the buttock along the internal circumflex or obturator arteries, also lumbar and dorsal abscesses. (5) The presence of like tubes near nerves, as a psoas passing into the pelvis along the lumbo-sacral cord. These various structures act as weak points, and predispose to the various paths that such abscesses often take.

CHAPTER XLV.

GYNÆCOLOGICAL OPERATIONS.

OVARIOTOMY.

Chief instruments required.—Scalpel, probe-pointed bistoury, scissors, ten pairs of WELLS'S or PÉAN'S artery forceps, NÉLATON'S volsella forceps, trocar for tapping cyst, with elastic tubing, blunt hooks, clamp and cautery, carbolised silk ligatures, sutures of carbolised silk, or silk worm-gut, threaded to a needle at each end, for stitching up the abdominal wound, glass drainage tube, hand mirror or bull's-eye lantern, sponges, eight large and four small—one should be large and flat—large forceps for adhesions, spatulæ, dissecting forceps, sponge holders, porcelain trays for instruments, tenacula, needles on fixed handles, aneurism needle, needle holder, carbolic lotion, and dressings.

Preliminary.—The operation should be performed about a week or ten days after a menstrual period. It is usually done when the tumour is about the size of a six months' child, but may be done earlier if it be diagnosed. Do not mistake pregnancy for an ovarian tumour; if in doubt, wait till the tumour is at least nine months old. The bowels should be cleared out by an aperient dose of castor oil, given two nights before the operation, followed by an enema early in the morning of the operation. The patient should take a bath the night before the operation. The temperature of the operating-room should be about sixty degrees Fahrenheit. The patient should be clothed with loose, warm, night-clothes, and long woollen stockings. The abdomen is washed, and shaved if necessary, at the point where the incision is to be made, and covered by a waterproof, with an oval hole in it, six inches by eight; the edges of the opening are spread with a coating of

adhesive plaster, so as to adhere to the skin and protect the patient's dress from blood, lotion, etc. Take care that the bladder is emptied by the catheter before the patient is placed on the table. Take a careful note of all the sponges and self-holding forceps to be used at the operation, and on no account should sponges be torn up during the operation.

Position of the Patient.—She is placed on her back, on an ordinary table, with her shoulders slightly elevated, and her feet towards the window, in order that the light may be reflected into the wound. Her legs and chest should be warmly covered, and hot water-bottles should be laid at her feet and sides. The operator stands on her right side, with his back to the window.

The Chief Steps of the operation are:—

1. Make an incision, four or five inches long, in the *linea alba*, beginning about an inch below the umbilicus. Cut through the skin and fascia, fat, and *linea alba*; secure all bleeding vessels, and then divide the *fascia transversalis*, extra-peritoneal fat, and peritoneum.
2. Having exposed the cyst, plunge in WELLS'S or TAIT'S trocar, and evacuate its contents as far as possible; the hand may also be introduced into the cyst, and septa broken down. Place two or three sponges into the pelvic cavity, and also above the tumour.
3. Seize the collapsed cyst wall with NÉLATON'S forceps, and pull it out of the abdomen; the assistant meanwhile, by means of the large, flat sponge, and pressure upon the abdominal wall, prevents the intestines from protruding.
4. Transfix the pedicle with a blunt needle, armed with a double carbolised silk ligature, avoiding all obvious veins; it may be tied in two or three portions, according to its size and vascularity. KEITH secures the pedicle by means of the ordinary cautery, with cautery-clamp. The clamp alone is seldom used now-a-days. With the cautery, or ligature, the pedicle is dropped back into the abdomen; with the clamp, it is treated

extra-peritoneally. Great care is required in the treatment of adhesions, especially when adherent to the abdominal or pelvic viscera.

5. When the pedicle and adhesions are secured, and the tumour removed, search for the other ovary, and remove it if it be distinctly cystic.
6. Take out the sponges and examine them for signs of bleeding, carefully cleanse the peritoneum, for no serum or blood should be left in the abdomen. Search for bleeding points by means of the hand mirror or bull's-eye lamp, and secure them. Remove all forceps and sponges, and count them.
7. Place the flat sponge in the incision, and sew up the abdominal wound with carbolised silk, or silk worm-gut, threaded to a needle at each end, introducing the needles from the peritoneal side, and avoiding the recti muscles. Pass all the sutures, remove the sponge, and then tighten them. Take care that they bring the divided edges of the parietal peritoneum into apposition, otherwise ventral hernia may follow.
8. In simple cases, no drainage tube is required, as the peritoneum is sufficiently absorbent; in cases with strong and numerous adhesions, a glass drainage tube should be passed into the pouch of DOUGLAS. The tube should have a broad flange of india-rubber, and over its end a sponge should be placed to soak up the serum.

The patient is now carried back to bed, which must previously be warmed for her; she is to be covered with light, warm clothing, and hot bottles placed around her, if necessary, and her knees supported by pillows. Little food is allowed for thirty-six hours, but hot water may be allowed *ad libitum*, a little milk being added in the course of twenty-four hours; and later, beef-tea may also be allowed. The bowels should be kept at rest, and she should take liquid food only, for at least a week. If the patient is restless after the operation, morphia may be given hypodermically at bedtime.

The Ovary consists of three parts, each of which may give rise to cysts:—

1. The **Oöphoron**, or ovary proper; the egg-bearing part.
2. The **Paroöphoron**, which is lodged in the concavity of the oöphoron, and usually known as the hilus. It is almost entirely composed of the remains of the Wolffian body, in various stages of retrogression.
3. The **Parovarium**.—It is connected with the paroöphoron, and consists of a series of vertical tubes, the persistent remains of the excretory ducts of the Wolffian body. It consists of three parts—(a) A distal series of tubules, attached by one end only—KOBELT'S tubes; (b) a row of tubes, connected by one end with the paroöphoron, while the other end joins (c) a common collecting canal, the representative of the segmental duct in the adult female, known as GÆRTNER'S duct. Parovarian cysts are situated above the ovary proper, while the Fallopian tube arches over their upper border.

UTERINE FIBROIDS.

These tumours consist of fibrous tissue and non-striped muscle in varying proportions, and are more properly called *fibro-myomata*, or they may even be pure *myomata*. In the first instance they all spring from the muscular coat of the uterus, but as they increase in size they may assume one of three positions, or varieties.

Varieties.—1. **Subperitoneal**, when they grow outwards into the peritoneal cavity, and either fill up the abdominal cavity or become jammed in the pelvis. This variety does not cause hæmorrhage or increase of menstruation. If it is not too large it may be removed as in ovariectomy, securing the pedicle as there described, or stitching the peritoneum over the face of the stump. When large or numerous, perform "Hysterectomy."

2. **Interstitial**, where the tumour remains and continues to grow in the wall of the uterus, and does not become pedunculated. They are soft or firm: the soft form causes great hæmorrhage. For their treatment we may (1) perform BATTEY'S operation, or

(2) LAWSON TAIT'S operation, (3) do Hysterectomy, or (4) adopt APOSTOLI'S treatment.

3. **Submucous**, when the tumour projects into, and dilates, the uterine cavity; they lie just below the mucous membrane, and may be sessile or pedunculated. When pedunculated, they are known as fibroid polypi. They act as foreign bodies, and cause uterine contractions and great hypertrophy of the muscular coat of the uterus. The usual treatment is to dilate the cervix, divide the mucous membrane, and shell out the sessile variety, or divide the pedicle and remove the polypoid form.

These fibroid tumours develop during the period of active sexual life, being greatest probably between the ages of thirty and forty. They do not begin before puberty, nor after the menopause; their growth, in fact, being usually arrested after the menopause, though the menopause is often delayed when they are present. They very often cause sterility.

The Surgeon may have to interfere because of the severe hæmorrhage they often cause, or on account of their rapid increase in size, and severe pressure symptoms on the abdominal or pelvic viscera, especially the bladder and urethra; he must be prepared to remove the entire body of the uterus if necessary—"hysterectomy." Ergot of rye has often a beneficial effect on fibroids: it acts in two ways—by diminishing the blood supply, and by favouring the pedunculation and expulsion of the submucous variety.

Natural Terminations.—(1) Before the menopause, they may continue to grow, or remain stationary; after the menopause, they usually atrophy and disappear. Pregnancy may also cause their disappearance. 2. They may degenerate—as fatty degeneration, become œdematous, inflamed, and gangrenous, or they may become calcified, or ossified, forming "**womb-stones.**" (3) The submucous form may become pedunculated by the uterine contractions; or (4) they may become extruded, from the pedicle being torn across.

HYSTERECTOMY.

In this operation the body of the uterus is removed along with the tumour—in short, amputation of the uterus at the os internum. This operation is a very serious one, and should not be performed except when the growth of the tumour is rapid, the patient young

and far from the menopause, or when hæmorrhage is great and frequent, or the patient actually crippled by the weight and pain of the tumour, and other operations, as BATTEY'S operation or LAWSON TAIT'S operation, are out of the question. For the proper performance of this operation, the cervix should not be the seat of fibroid growth, for then it will be very difficult to clamp the pedicle properly.

The Chief Steps of the operation are:—

1. Make a sufficiently large abdominal incision, as in ovariectomy; the bladder must be watched for, as it is often raised up with the tumour. In order to assist the definition and separation of the bladder, it is advised that it should *not* be emptied before the operation, as it is in ovariectomy.
2. Draw out the uterus, and take care that no sessile growths are wrenched off while so doing, as the raw surface bleeds freely. Should such an accident happen, the assistant must keep a sponge pressed against the raw surface till the uterus is removed. Separate all adhesions very carefully, and then—
3. Attend to the pedicle. On account of the dangers from hæmorrhage and peritonitis, it is usually treated by the extra-peritoneal method, in all cases where a part of the uterus is cut away; for then, not only is the pedicle large, but there is great risk of septic infection from the vagina through the uterine canal. It may be secured either by using KOEBERLÉ'S *serré-nœud*, or KEITH'S or TAIT'S clamp. In the former case, the stout wire is passed round the neck of the tumour, about the level of the os internum, and drawn tight. The pedicle is then transfixed by two stout pins, which lie outside the abdominal wound, one on each side, the points of the pins being specially guarded; the pins prevent the pedicle from slipping back into the abdomen.
4. The mass is next cut away above the wire, the intestines being protected by sponges, and blood prevented from passing into the abdomen as far as possible by the

assistant closely following the knife with a sponge and sopping up the blood. After removal of the mass Dr KEITH scoops out and disinfects the cervical canal, and applies a solution of perchloride of iron to the stump. The stump is then placed at the lower angle of the abdominal incision.

5. Carefully clean out the peritoneal cavity as in ovariectomy, and then close the abdominal wound by sutures brought close up to the pedicle. The clamp wire is tightened day by day, the stump meanwhile being kept clean and dry, and dusted with iodoform. The distal end of the pedicle usually separates in about three weeks.

It would be rarely possible, or advisable, to perform this operation for malignant disease of the uterus, as malignant disease usually attacks the cervix—the very part that is left in this operation. On the subject of Hysterectomy for uterine fibroids, Dr THOMAS KEITH thus writes:—"What I now plead for is, that for a time all bloody operations for the treatment of uterine fibroids should cease, and that Dr APOSTOLI's treatment,* as practised by him, should have a fair trial. . . . Hysterectomy, remember, which is performed every day for a complaint that rarely of itself shortens life, kills every fourth or fifth woman who is subjected to it. This mortality must cease; it is not a question of Surgery, it is a question of humanity."

REMOVAL OF THE OVARIES.

The removal of the ovaries is known as "*Batley's Operation*," or *Oöphorectomy*. In this operation the ovaries alone are removed. The name, properly speaking, should be restricted to cases where the ovaries removed are of normal size, or, at least, not the seat of large tumours.

This operation may be required—(1) In cases of severe dysmenorrhœa, with serious general symptoms; (2) to check the growth of uterine fibroids, especially when they are the cause of severe hæmorrhage, uncontrollable by other means; (3) hysterio-epilepsy; and (4) prolapsed and fixed ovaries. *BATLEY'S* object,

* Treatment by Electricity.

when he performed this operation, was to bring on a premature menopause; experience, however, has since shown that it does not do so. The operation may be performed:—

I. Through the Vagina—

1. An incision is made in the posterior vaginal wall, behind the cervix, and in the middle line, for about an inch and a half.
2. The peritoneal cavity is then opened and the ovary hooked down, either by the finger or polypus forceps.
3. The pedicle is then ligatured close to the hilus with fine carbolised silk and the ovary cut off. The other ovary is treated in the same way.
4. Pass a drainage tube, close the wound if thought necessary, and irrigate twice daily with a weak antiseptic solution.

II. They may also be removed through an opening in the Abdomen—

1. Make an opening into the abdomen, as in ovariectomy.
2. Pass in the fingers and feel for the fundus of the uterus, and then follow the Fallopian tube till the ovary is reached.
3. Draw the ovary out, transfix the broad ligament with fine carbolised silk, and ligature near the hilus; and then cut the pedicle about half-an-inch to the ovary side of the ligature, and remove the ovary. Treat the other ovary in the same way. See that there is no bleeding from the pedicle before it is dropped into the abdomen.
4. Close the incision as in ovariectomy.

TAIT'S OPERATION.

In this operation the “uterine appendages”—Fallopian tubes and ovaries—are removed. He makes a two-inch abdominal incision, frees adhesions, taps any cysts present, and then pulls the tubes up to or through the abdominal incision, ligatures with the Staffordshire knot, and removes the tube and ovary. The

pedicle is then dropped back, and a glass drainage tube introduced. If the tube cannot be removed, the opening in it is carefully stitched to the abdominal incision.

TAIT believes that removal of the uterine appendages will arrest menstruation. The operation may be required—(1) To control hæmorrhage in the case of fibroid tumours, and to stop their growth or cause their atrophy; (2) menstrual epilepsy; (3) chronic ovaritis; (4) salpingitis, hæmatosalpinx, pyosalpinx and hydro-salpinx. In the latter cases, the tubes are removed because they are diseased, and the ovaries because they are probably diseased as well, and because they are of no use without the tubes. In fibroids, both ovaries and tubes are removed, in order to check the hæmorrhage. It may also be performed for tubal or ovarian dysmenorrhœa (“**appendage dysmenorrhœa**”).

The leading signs of this condition are—(1) Premenstrual pain, often severe; (2) more or less continuous pelvic pain; (3) profuse menstruation; (4) sterility; and (5) dyspareunia.

EXCISION OF THE WHOLE UTERUS.

(FREUND'S OPERATION.)

This operation has been performed in the case of malignant disease of the uterus. It may be performed:—

I. By Abdominal Incision (FREUND'S method).—The mortality in this method is very high, and therefore most operators have given it up in favour of the vaginal method. The abdomen is opened, the uterus separated and fixed, and then each broad ligament is ligatured in three parts, the lowest ligature passing through the lateral fornices of the vagina. The uterus is next cut away from the broad ligaments, the peritoneum divided all round the cervix, and its connection with the fornices severed, and the whole organ removed. The ends of the ligatures are brought through the hole in the roof of the vagina, and a drainage tube introduced into the same opening.

II. Through the Vagina.—In the first instance, the vagina must be thoroughly disinfected. The operation is performed with the patient in the lithotomy position, and a douche is so arranged that a stream of warm carbolised water may continually irrigate

the vagina. A strong wire is passed through the cervix, in order to pull down the uterus towards the vulva; the labia are held aside, and the sides of the vagina separated if necessary.

The **Chief Steps** of the operation (after Sir SPENCER WELLS) are—

1. Division and loosening, and pushing up, to the extent of a half to three-quarters of an inch of the vaginal mucous membrane, behind, in front, and all round the cervix.
2. Pushing upwards, or separation of the bladder and ureters from the neck and anterior surface of the body of the uterus, as in the abdominal method, but the peritoneum is not cut into.
3. Opening of DOUGLAS'S pouch and the introduction of a sponge to keep up the small intestines. Two fingers of the left hand may also be introduced and passed over the fundus, into the interval between the uterus and the bladder, and an incision then made from the front of the cervix down upon the fingers, dividing the peritoneum anteriorly. In this way the uterus is now freed in front and behind.
4. The next step is to secure the uterine arteries on both sides, by ligature or by the pressure forceps. Each broad ligament may be ligatured in two parts, and an additional ligature put round the whole for safety.
5. Next divide the broad ligaments and other attachments; remove the uterus and examine the pedicles for bleeding points, and secure them at once.
6. Remove the sponges and bring the pedicles into the wound in the roof of the vagina, and fix in position by suture, and introduce a T-shaped drainage tube between the pedicles into the peritoneal cavity. Lastly, arrange the ligature threads or forceps, and plug the vagina loosely with iodoform gauze.

Sir SPENCER WELLS lays great stress upon two points in this operation—(1) The extreme care necessary in the separation of the bladder and ureters from the uterus; neither should be

wounded, and care should be taken not to ligature one or both ureters. (2) The second point he insists upon is the substitution of forcipressure for the ligature; they must be left on for twenty-four, thirty-six, or even forty-eight hours, until all danger of bleeding has ceased. Such a plan is simpler than ligature, more secure, takes much less time, and saves much trouble and suffering to the patient after the operation.

CÆSARIAN SECTION.

This operation consists in making an incision through the abdominal and uterine walls for the extraction of a living child.

Indications.—When the conjugate at the brim is two inches or less, with a transverse of only three inches, as sometimes seen in cases of rickets or malacosteon; also in cases where ovarian tumours are associated with pelvic deformities. It is also indicated in cases of cancer of the cervix, because dilatation is but slowly and dangerously effected, from the risk of lacerations, hæmorrhage, and blood poisoning. In some cases this operation is performed where the life of the child is of more value than the life of the mother. It may even be practised on the dead woman, from five to twenty minutes after the last breath, after the seventh month of pregnancy, with a chance of saving the child.

Best Time to Perform.—After labour has begun, in cases requiring this operation, the sooner it is performed the better. The best time is that which immediately precedes the rupture of the membranes, *i.e.*, after labour has begun, but before the close of the first stage. Should labour be anticipated, it will be necessary to start uterine action before beginning the operation, in order to make the uterus contract afterwards and prevent “flooding.”

Operation.—The rectum and bladder must be emptied before beginning the operation. An assistant must fix the uterus with his two hands applied to the sides of the abdomen. The Surgeon then makes an incision, at least five to seven inches long, in the *linea alba* between the umbilicus and the pubes. The various tissues are cut through, and the bleeding points secured as in ovariectomy. Make a small opening in the peritoneum, introduce a couple of fingers of the left hand, on the palmar aspect of which

a probe-pointed bistoury is slid, so as to enlarge the incision; the uterus is now exposed. Open the uterus in the centre of the anterior wall; and to allow of this, it may be necessary for the assistant to twist it a little round, so that this point may be opposite the abdominal wound. In this way the large vessels at the *sides* are avoided. Make a small incision at the upper part, then introduce the left index finger, and enlarge the wound with a probe-pointed bistoury; it is necessary to do this *quickly*, because of the great hæmorrhage. The assistant in the meantime must jam the uterine incision against the abdominal one, especially at the upper and lower angles, to prevent blood passing into the abdominal cavity. Extract the child, taking the head out first; because, if the legs were taken first, the uterus might contract and imprison the head, while the cold, acting on the child's legs and body, might induce inspiratory efforts and suffocate it. Strip off the placenta and membranes artificially, pass a sponge probang of some size through the cervix uteri and out at the vagina, so as to secure a free exit for lochial or other discharges. The peritoneal cavity must then be carefully cleansed, the wound in the uterus stitched with silk separately, or else fixed to the abdominal wound; a glass drainage tube is then passed into the abdominal wound.

The dangers of this operation are—(1) Hæmorrhage, (2) shock, and (3) peritonitis.

LAPARO-ELYTROTOMY.

(THOMAS'S OPERATION.)

In this operation the cervix is reached by an incision through the lower part of the abdominal wall and upper part of the vagina, and through it the fœtus is extracted.

Its advantages over Cæsarian Section are — (1) That the peritoneum is not opened into, and (2) that the uterine wall is not incised, so that one of the chief risks of Cæsarian Section—hæmorrhage—is avoided.

The cases requiring the operation are those necessitating Cæsarian Section, when the mother is alive. It should not be performed in cases of tumours obstructing the pelvic cavity, carcinoma, nor

fibroid of the uterus, nor when the head is firmly impacted in the pelvic brim. It cannot be performed twice on the same side. The operation is performed on the right side, since the presence of the rectum on the left side is against the operation on that side. Four special assistants are necessary, besides the one who administers chloroform.

Position of the Patient.—She is placed on her back, with the pelvis raised, and in the same position as for ovariectomy. Before beginning the operation, the cervix must be dilated as far as possible. The operator stands on the right side. An assistant, standing on the left side, draws the uterus upwards, and to the left, as far as possible, while the Surgeon makes the incision. The incision begins one inch above the anterior superior spine of the ilium, and is carried downwards and inwards, in a slightly curved direction, parallel with POUPART'S ligament, to a point about two inches above, and a like distance external to, the spine of the pubes—*i.e.*, about the middle of POUPART'S ligament. The incision is almost the same as that for ligature of the right external iliac artery by ABERNETHY'S incision. It must not approach any nearer the spine of the pubes, lest the round ligament or the deep epigastric artery be wounded. The superficial epigastric is necessarily divided, and must be secured at once. The skin, superficial and deep fascia, the aponeurosis of the external oblique, the internal oblique, and the transversalis muscles are divided, and the fascia transversalis exposed. Secure all bleeding points, and then open this fascia. Next separate the peritoneum from the transversalis and iliac fascia, and direct an assistant to keep the peritoneal sac, with the intestines, well out of the way, for the rest of the operation, by means of a warm, soft, aseptic cloth. Another assistant now passes a rigid catheter into the bladder, and holds it against the posterior wall of the bladder, or the anterior wall of the vagina. A blunt, bulbous instrument of some size is next passed up the vagina, and the vagina pushed by it above the ilio-pectineal line; *on* this an incision is made by PAQUELIN'S cauterium, heated to a red-heat only, as far below the uterus as possible, to avoid the large venous plexus at its upper part, and parallel with the ilio-pectineal line. Through the opening thus made the catheter is felt in the bladder, and then the vagina is *torn* through as far forwards and backwards

as may be done with safety. The catheter is now withdrawn, and the uterus is turned to the left, the cervix lifted into the incision by the fingers, the membranes ruptured, and the child extracted.

Risks of this Operation.—(1) Wound of the deep epigastric at the inner end of the incision, (2) opening into the pouch of DOUGLAS, (3) wound of the bladder, and (4) wound of the ureter.

Before concluding the operation, the bladder should be injected with milk to make sure that it has not been wounded. One of the difficulties of the operation is hæmorrhage from the vaginal walls, but by the use of PAQUELIN'S cautery this risk is much diminished.

The **Arteries** are branches from the hypogastric, the inferior vesical, the internal pudic, and the hæmorrhoidal. The **Veins** form a plexus round the whole vagina, but are specially marked at its upper and lower ends.

SHORTENING THE ROUND LIGAMENTS.

(ALEXANDER-ADAMS'S OPERATION.)

This is an operation advised for the relief or cure of prolapsus uteri; by shortening the ligaments, it is said, the displaceable segment is drawn up and fixed.

The bowels and bladder are emptied, the patient placed on the table, chloroformed, and the pubes shaved. An incision is made upwards and outwards from the pubic spine, two inches in length, in the line of the inguinal canal. The incision divides skin and fascia, and opens into the external abdominal ring. The end of the ligament is then grasped and pulled out gently as far as possible, and fixed in its new position by stitches. The other side is treated in an exactly similar manner.

I have tried this operation on the dead body, and was specially impressed by two facts—(1) The difficulty in certainly finding the round ligaments, and (2) the still greater difficulty of appreciably shortening them when found. The ligaments are not like pieces of string drawn through tubes, but are firmly adherent throughout their whole extent, first to the sides of the inguinal canal, and then to the pelvic cellular tissue, so that it is next to impossible to shorten them in such a way as at all likely to benefit a prolapsed uterus.

PORRO'S OPERATION.

This is a modification of the old Cæsarian Section, the difference being that the uterus and its appendages are removed, after the child is extracted. LAWSON TAIT calls it "amputation of the pregnant uterus."

Its special advantages, as compared with the older operation, are—(1) It lessens the risk of hæmorrhage. (2) It avoids the risk of effusion into the abdominal cavity; instead of leaving the incised uterus, with the wound probably gaping, with all the attendant risks of septic peritonitis, it is fixed externally in such a way that it can be readily dressed. (3) The Surgeon can choose the period for the performance of the operation, because, as the uterus is removed, it is not necessary to wait till uterine contractions have commenced, as in the old Cæsarian Section. For this reason the operator can make his own arrangements, and have skilled assistance at a definite hour. (4) It saves the woman from the risk of again becoming pregnant. It is required in the same class of cases as the older operation.

The best time to perform the operation is when the uterus is fully developed, and some days before labour sets in; at this period there is less risk to the bladder than if one waited till the labour had begun, as the bladder, during labour, is an abdominal organ, and, therefore, more apt to be injured, and the incision has to be made higher up. Further, the operator is not troubled by the contractions of the uterus, and its wall is less vascular.

LAWSON TAIT thus performs the operation—"No special instruments are required—nothing but a knife, some artery forceps, a piece of rubber drainage tube, without perforations, two or three knitting needles, and a little perchloride of iron."

"My method of operating is to make an incision through the middle line large enough to admit my hand, and then I pass a piece of rubber drainage tube (without any holes in it) as a loop over the fundus uteri, and bring it down so as to encircle the cervix, taking care that it does not include a loop of intestine. I then make a single hitch and draw it tight round the cervix, so as to completely stop the circulation. I give the ends of the tube

to an assistant, who keeps them well on the strain, so as to prevent the loose knot from slipping, the reason of this being that, should there be any bleeding, and any necessity for further constriction, I could secure this in a moment, without undoing any knot, and the simplicity of this method greatly commends it. I then make a small opening in the uterus, and enlarge it by tearing with my two forefingers, seize the child by a foot, and remove it. I then remove the placenta, and by that time the uterus has completely contracted, and is easily drawn through the wound in the abdominal wall. The constricting tube will now probably require to be tightened, and the second hitch of the knot may be put on at the same time, and the work is practically done. Stuff a few sponges into the wound to keep the cavity clear of blood, and pass the knitting needles through the flattened tube and through the cervix, and in this simple way a clamp of the most efficient kind is at once made. The uterus is removed about three-quarters of an inch above the rubber tube. The usual stitches are put in, the wound closed round the stump, which, of course, is brought to the lower part of the opening, and then the stump is dressed with perchloride of iron in the usual way."

The Chief Steps of this operation, then, are:—

1. Making the abdominal incision.
2. To open the uterus.
3. To extract the child.
4. To draw the emptied uterus out of the abdomen.
5. To transfix and ligature the uterus, just below the os internum, by KOEBERLE'S *serré-nœud*, or you may use KEITH'S or TAIT'S clamp. If the elastic ligature is used, it must be passed after making the abdominal incision.
6. Next amputate the uterus, with the ovaries and tubes, about three-quarters of an inch above the ligature, or *serré-nœud*.
7. Fix the stump at the lower angle of the abdominal wound, and dress with perchloride of iron.
8. Close the abdominal wound around the stump in the usual way.

“Sänger's Operation” is Cæsarian Section, with removal of a wedge-shaped portion of the uterine wall on each side of the incision. The peritoneum is stripped aside, and the wedge-shaped mass cut out, the apex of the wedge being towards the uterine cavity. In this way two flaps of peritoneum are left, one on each side of the original incision, and when the wound is closed the peritoneal flaps are tucked in, just as in LEMBERT'S suture of the intestine, and stitched together. This ensures rapid union between the cut surfaces.

“Müller's Ablation” is an operation performed in some cases of uterine fibroids; in this operation the abdomen is opened, the tumour, and the uterus containing a non-viable fœtus, removed. There is no question here of the life of the child, the maternal complications being so grave as to preclude the pregnancy going to term.

“Myomotomy” is abdominal section, and removal of fibroids by ligature and closure of the incision, in the hope that pregnancy may go on to term. This operation should only be performed—(1) When the fibroid is attached in an accessible situation; and (2) when its presence is causing either intolerable pain, or discomfort from distension. It was first performed by KNOWSLEY THORNTON in 1879.

CHAPTER XLVI.

ATTACHMENT OF MUSCLES.

ORIGIN, INSERTION, AND NERVOUS SUPPLY OF THE MORE IMPORTANT MUSCLES MENTIONED IN THE PRECEDING PAGES.

HEAD AND NECK.

1. *Platysma Myoides*.—*Arises* from the clavicle and acromion, and from the fascia covering the upper part of the deltoid, pectoral, and trapezius muscles; the fibres pass upwards and inwards, and are *inserted* into the lower jaw, angle of the mouth, and cellular tissue of the face, interlacing with many of the facial muscles. The muscle lies immediately beneath the skin, and therefore above the deep fascia. The external and anterior jugular veins, and the superficial branches of the cervical plexus, lie just beneath it. **Nerves**.—The facial and superficial branches of the cervical plexus.

The **special** use of the platysma is probably to assist the venous return from the head and neck. It will be observed that the muscle follows the outline of the neck, so that its points of attachment are above the level of its muscular belly. When, therefore, the muscle contracts, its centre part rises up, like the string of a bow, and so relieves the external and anterior jugulars from pressure, raising up the skin and superficial fascia.

2. *Sterno-Cleido-Mastoid*.—*Arises* from the upper and anterior part of the sternum, and posterior surface of the inner third of the clavicle, and is *inserted* across the mastoid process of the temporal bone, and the outer half of the superior curved line of occipital bone. **Nerves**.—Spinal accessory and branches from the cervical plexus.

In order to find out the relation of this muscle to tumours of the neck, the patient should lie on his back, and then raise the

head. This at once puts the muscle in action, and we then see whether the tumour is over or under it. Another method is to make the patient turn his head forcibly to the opposite side, while the Surgeon pushes his chin in a contrary direction. Beneath the upper third of this muscle we find HUTCHINSON'S "sub-mastoid potato tumour."

3. **Sterno-Hyoid.**—*Arises* from the back of the sternum, first costal cartilage, and clavicle, and is *inserted* into the body of the hyoid bone. **Nerve.**—Descendens noni.

4. **Sterno-Thyroid.**—*Arises* from the back of the first piece of the sternum, and is *inserted* into an oblique line on the side of the thyroid cartilage. **Nerve.**—Descendens noni.

5. **Omo-Hyoid.**—*Arises* from the upper border of the scapula, close to and on the transverse ligament, and is *inserted* into the body of the hyoid bone. **Nerve.**—Descendens noni.

This muscle consists of two bellies, united by a central tendon; the bellies, it will be remembered, take part in the subdivision of the anterior and posterior triangles of the neck. In use it probably resembles the platysma, assisting the venous return from the *deep veins* of the neck, just as the platysma assists the venous return from the *superficial veins*. For this reason it is divided into two bellies, with a tendon between; the posterior belly passes over the deep veins in the posterior triangle, while the anterior passes over the deep veins in the anterior triangle—notably the internal jugular. When either belly contracts, it shortens and tends to rise up off the deeper parts, and takes the deep cervical fascia with it; the posterior belly contracts from the scapula to the central tendon, while the anterior contracts from the central tendon to the hyoid bone. If there were no central tendon, and were the muscle to contract as a whole, it would press upon the deep veins and retard the venous return, instead of assisting it. But, with the two bellies, when it contracts, the deep cervical fascia is raised up and the pressure upon the veins relieved.

6. **Thyro-Hyoid.**—*Arises* from the oblique line of the thyroid cartilage, and is *inserted* into the body and great cornu of the hyoid bone. **Nerve.**—Special branch from ninth (hypo-glossal).

7. **Masseter.**—*Arises* from the zygomatic arch and malar bone, and is *inserted* into the angle and ramus of lower jaw.

8. **Temporal.**—*Arises* from the temporal fossa, and is *inserted* into the apex and inner surface of the coronoid process.

9. **Internal Pterygoid.**—*Arises* from the pterygoid fossa, especially the inner surface of the external pterygoid plate, and is *inserted* into the angle and inner surface of ramus.

10. **External Pterygoid.**—*Arises* from the under surface of the great wing of the sphenoid and the outer surface of the external pterygoid plate; *inserted* in front of the neck of the condyle of the lower jaw, and into the inter-articular fibro-cartilage. **Nerves.**—The above four muscles are supplied by the third division of the fifth cranial nerve.

11. **Digastric.**—*Arises* from the groove in the mastoid process, perforates the stylo-hyoid, and is attached to the body of the hyoid bone by a central tendon; *inserted* into the under surface of the lower jaw close to the symphysis. **Nerves.**—Posterior belly, by the facial; the anterior, by the mylo-hyoid branch of the inferior dental (fifth).

12. **Scalenus Anticus.**—*Arises* from the anterior tubercles of the transverse processes of the third, fourth, fifth, and sixth cervical vertebræ; *inserted* into the tubercle on the inner margin of the first rib, between the grooves for the subclavian artery and vein.

13. **Scalenus Medius.**—*Arises* from the posterior tubercles of the transverse processes of all the cervical vertebræ except the first; *inserted* into the upper surface of the first rib behind the groove for the subclavian artery.

14. **Scalenus Posticus.**—*Arises* from the posterior tubercles of the transverse processes of the lower cervical vertebræ; *inserted* into the outer surface of the second rib. **Nerves.**—The scaleni are supplied by supra-clavicular twigs of the brachial plexus.

15. **Trapezius.**—*Arises* from the external occipital protuberance, inner third of superior curved line, ligamentum nuchæ, the spinous processes of the last cervical and all the dorsal vertebræ, and the supra-spinous ligament; *inserted* into the posterior border of the outer third of the clavicle, inner border of acromion, and upper lip of the spine of the scapula. **Nerves.**—The spinal accessory and deep branches of the cervical plexus.

16. **Latissimus Dorsi.**—*Arises* from the spinous processes of the lower six dorsal vertebræ, the posterior layer of the lumbar

aponeurosis, and through this to the lumbar and sacral spines, the outer lip of the iliac crest, the last three ribs, interdigitating with the external oblique, and sometimes from the lower angle of the scapula; *inserted* into the bottom of the bicipital groove of the humerus. **Nerve.**—The long subscapular.

17. **Levator Anguli Scapulæ.**—*Arises* from the posterior tubercles of the transverse processes of the third, fourth, and fifth cervical vertebræ; *inserted* into the posterior border of the scapula above the spine. **Nerves.**—Two or three deep branches of the cervical plexus, and a branch from the nerve to the rhomboids (brachial plexus).

18. **Rhomboideus Minor.**—*Arises* from the ligamentum nuchæ and spinous processes of the last cervical and first dorsal vertebræ; *inserted* into the posterior border of the scapula opposite the root of the spine.

19. **Rhomboideus Major.**—*Arises* from the spinous processes of the four or five upper dorsal vertebræ; *inserted* into the posterior border of the scapula below the spine. **Nerves.**—Both minor and major are supplied by a special supra-clavicular branch of the brachial plexus.

20. **The Superior Constrictor.**—*Arises* from the lower third of the internal pterygoid plate, from the hamular process, from the pterygo-maxillary ligament, and from the lower jaw; it is *inserted* into the median raphé behind.

21. **The Middle Constrictor.**—*Arises* from the greater and lesser cornua of the hyoid bone, and from the stylo-hyoid ligament; it is *inserted* into the median raphé.

22. **The Inferior Constrictor.**—*Arises* from the oblique line of the thyroid cartilage and from the side of the cricoid cartilage; it is *inserted* into the median raphé.

The three constrictors overlap from below upwards, the inferior overlapping the middle, and the middle overlapping the superior. Between the middle and the superior we find (1) the glosso-pharyngeal nerve, (2) the stylo-pharyngeus muscle, and (3) the stylo-hyoid ligament. Between the middle and the inferior we find (1) the superior laryngeal artery, (2) the internal branch of the superior laryngeal nerve, and (3) the external branch of the same nerve. Passing below the inferior we find (1) the recurrent

laryngeal nerve, and (2) the inferior laryngeal branch of the thyroid artery. Between the base of the skull and the superior constrictor there is a semi-lunar interval, known as the "*space of Morgagni*." It is filled up by the specially strong submucous coat of the mucous membrane of the pharynx; two muscles are seen in this space—the levator palati and the tensor palati, and between them is situated the orifice of the Eustachian tube—and two arteries passing into the pharynx—a branch from the ascending pharyngeal artery, and another from the inferior palatine.

23. **Rectus Capitis Anticus Major.**—*Arises* from the anterior tubercles on the transverse processes of the third, fourth, fifth, and sixth cervical vertebræ (same origin, therefore, as the scalenus anticus), and is *inserted* into the under surface of the basilar process, close to the median line. (For the other recti and obliques, see vol. ii., page 230.)

24. **Longus Colli.**—This muscle consists of two oblique portions, and one vertical. (1) The **inferior oblique part** *arises* from the bodies of the first and second dorsal vertebræ, and is *inserted* into the transverse processes of the fifth and sixth cervical. (2) The **superior oblique part** *arises* from the anterior tubercles of the third, fourth, and fifth cervical vertebræ, and is *inserted* into the anterior tubercle of the atlas. (3) The **vertical portion** *arises* from the bodies of the three lower cervical and the three upper dorsal vertebræ, and is *inserted* into the bodies of the second, third, and fourth cervical. At the lower part of the neck the vertebral artery lies between this muscle and the scalenus anticus.

25. **Splenius.**—*Arises* from the lower half of the ligamentum nuchæ, the spine of the seventh cervical and the upper six dorsal vertebræ. *Insertion*—Splenius capitis, across the mastoid process and the outer third of the superior curved line; the splenius colli has the same insertion as the origin of the levator anguli scapulæ—the posterior tubercles of the upper four cervical vertebræ.

26. **Complexus.**—*Arises* from the transverse processes of the upper six dorsal vertebræ and articular processes of the lower cervical, and is *inserted* into the occipital bone between the superior and middle curved lines. This muscle has a tendinous intersection about its middle, and is pierced by the great occipital nerve (= the internal branch of the posterior primary division of the

second cervical nerve), and also by the posterior division of the third cervical nerve. Its most internal part is often named the *Biventer cervicis*, as it consists of two fleshy bellies with an intervening tendon. Between this muscle and the underlying semi-spinalis colli, we find the profunda cervicis artery anastomosing with the princeps cervicis, and the vertebral; also the posterior branches of the cervical plexus of nerves. It further forms the immediate roof of the sub-occipital triangle (see vol. ii., page 230).

CHEST.

27. **External Intercostals.**—Eleven in number on each side; they are placed between adjacent ribs, and extend from the tubercles of the ribs to the point of union of the rib with its cartilage. From this point to the sternum, a membrane extends, called the anterior intercostal membrane. The fibres pass downwards and forwards.

28. **Internal Intercostals.**—Equal in number to the anterior, but the fibres of which are directed obliquely downwards and backwards; they extend from the angles of the ribs to the edge of the sternum. The gap thus left behind is completed by the posterior intercostal membrane. The **intercostal nerves** lie between the two muscular layers, as far as the mid-axillary line; but at this point they pierce the internal intercostal muscle very obliquely, and opposite the cartilages they are placed between the internal muscle anteriorly, and the pleura and triangularis sterni muscle posteriorly. The internal mammary artery is also in front of these nerves. The **intercostal arteries** lie between the muscles practically all the way round. In each space one artery comes forwards, while two pass backwards. *Passing forwards*, in the upper two spaces, the vessels come from the superior intercostal artery; in the lower nine, from the aorta. *Passing backwards*, in the upper seven spaces, the vessels are derived from the internal mammary artery; in the lower four, from the musculo-phrenic. As far as the mid-axillary line, the single vessel lies under cover of the lower edge of the rib, but at this point each divides into two twigs, which pass forwards along each edge of the space and anastomose with the corresponding anterior intercostals.

29. **The Triangularis Sterni Muscle.**—*Arises* from the inner surface of the ensiform cartilage and lower part of the sternum, and from the cartilages of the last three or four true ribs, and is *inserted* into the cartilages of the second, third, fourth, and fifth ribs. Lying in front of this muscle, we find the internal mammary arteries and the intercostal nerves; while its posterior surface is partially covered by the pleuræ, and part of it bounds the anterior mediastinum.

ABDOMEN.

30. **External Oblique.**—*Arises* from the outer surfaces of the lower eight ribs by eight digitations—the upper five interdigitate with the serratus magnus, the lower three with the latissimus dorsi; *inserted* into anterior half of the outer lip of the iliac crest, POUPART'S ligament, GIMBERNAT'S ligament, triangular fascia, front of pubes, and the whole length of the linea alba.

31. **Internal Oblique.**—*Arises* from the outer half of POUPART'S ligament, anterior two thirds of the middle lip of the iliac crest, and from the lumbar aponeurosis; *inserted*, the lower fibres join with the lower fibres of the transversalis to form the conjoined tendon, which is inserted into the crest of the pubes and the ilio-pectineal line: also into lower border of the cartilages of the four lower ribs, and the linea alba.

32. **Transversalis.**—*Arises* from the outer third of POUPART'S ligament, anterior two thirds of the inner lip of the iliac crest, outer surfaces of the cartilages of the lower six ribs, and by three lamellæ—from the tips of the spinous processes of the lumbar vertebræ, the tips of the transverse processes, and from the bodies of the vertebræ at the roots of the transverse processes, forming the *fascia lumborum*; *insertion* into linea alba, pubic crest, and ilio-pectineal line (conjoined tendon).

33. **Quadratus Lumborum.**—*Arises* from the ilio-lumbar ligament and iliac crest; *inserted* into the inner half of the last rib and into the tips of the transverse processes of the upper four lumbar vertebræ. **Nerves.**—The above four muscles are supplied by the lower six intercostal, the last dorsal, the ilio-hypogastric, and the ilio-inguinal nerves.

34. **Psoas Magnus.**—*Arises* from the front of the transverse processes of the lumbar vertebræ, from the inter-vertebral discs, and from the tendinous arches bridging across the four lumbar arteries; *inserted* into the lesser trochanter of the femur. **Nerves.**—From lumbar plexus. The *action* of this muscle is to flex the thigh and rotate it outwards, resembling in this respect the biceps muscle of the upper extremity.

35. **Iliacus.**—*Arises* from the iliac fossa, ilio-lumbar ligament, base of sacrum, and capsule of the hip joint; *inserted* along with the psoas magnus. **Nerve.**—The anterior crural. The psoas and iliacus muscles give that peculiar heave of the leg and foot observed in adults, where the entire lower limb has been paralysed in infancy (*infantile paralysis*).

36. **Transversus Perinei.**—*Arises* from the inner aspect of the ascending ramus of the ischium, and blends with its fellow of the opposite side in the central point of the perineum.

37. **Accelerator Urinæ or Bulbo-Cavernosus.**—This muscle takes origin from the central point of the perineum, and from the septum between the muscles of the two sides, and is *inserted*—the **posterior** fibres are attached to the superficial aspect of the anterior layer of the triangular ligament; the **middle** envelop the corpus spongiosum, and blend with the muscle of the opposite side on its upper surface; while the **anterior** pass along the sides of the corpora cavernosa, and are *inserted* into an aponeurosis on the dorsum of the penis.

38. **Erector Penis or Ischio-Cavernosus.**—This muscle lies upon the crus penis; it *arises* from the inner aspect of the tuber ischii, and is *inserted* by an aponeurosis into the anterior portion of the crus.

39. **Compressor or Constrictor Urethræ.**—It *arises* from the pubic arch, close to its junction with the ramus of the ischium. It passes above and below the urethra, and blends with its fellow of the opposite side in the middle line. The part enveloping the urethra is sometimes called GUTHRIE'S muscle (the *compressor urethræ* proper). A second part is known as WILSON'S muscle, or the *levator urethræ*, and consists of two small slips passing from the back of the pubis, and is *inserted* into the central point of the perineum; it is supposed to sling up the urethra. A third

part is known as the deep transverse muscle, and extends to the central point of the perineum.

The above four muscles are *supplied* by the pudic nerve.

40. **Levator Ani.**—*Arises* from the posterior surface of the pubis in front, behind from the spine of the ischium, and between these points from the “white line” of the pelvic fascia. From these points it passes downwards and inwards towards the middle line of the pelvic floor, and is *inserted* into the tip of the coccyx—the median raphé in front of that point, the sides of the lower part of the rectum, being connected with the fibres of the external sphincter, and partly with those of the internal, and again beneath the neck of the bladder, prostate, and urethra, blends with its fellow in the median raphé. The anterior portion of the muscle, arising from the pubic bone, is sometimes separated by a cellular interval from the rest of the muscle, and hence is often called the *levator prostate*. **Nerve.**—The fourth sacral.

UPPER EXTREMITY.

41. **Pectoralis Major.**—*Arises* from the anterior surface of the inner half of the clavicle, front of the sternum, cartilages of all the true ribs except the first and seventh, and aponeurosis of the external oblique, and is *inserted* into the outer lip of the bicipital groove. **Nerves.**—The external anterior thoracic nerve, and a branch from the internal.

42. **Pectoralis Minor.**—*Arises* from the third, fourth, and fifth ribs, near their junction with the cartilages, and is *inserted* into the coracoid process, inner border. **Nerve.**—The internal anterior thoracic.

43. **Serratus Magnus.**—*Arises* by nine digitations from the outer surfaces of the eight upper ribs, the second having two digitations, and is *inserted* into the anterior surface of the base of the scapula, especially at the upper and lower angles. **Nerve.**—The posterior thoracic, or nerve of BELL.

When this muscle is paralysed, the vertebral border of the scapula leaves the ribs and stands out markedly on the surface; it is also somewhat closer to the spines of the vertebræ, and the scapula is slightly higher than on the paralysed side. These points become much more marked when the arm is raised. The

arm cannot be raised above a right angle, because the scapula cannot be fixed. The patient is unable to push so strongly on that side, nor can the hand be advanced so far in front of the patient as on the healthy side.

44. **Deltoid.**—*Arises* from the outer third of the anterior border of the clavicle, outer border of acromion, and lower edge of spine; *inserted* into the middle of the outer surface of the shaft of the humerus. **Nerve.**—Circumflex. A bony deposit may sometimes take place in the tendon of insertion of this muscle in infantry soldiers, from pressure of the butt-end of the rifle, forming a so-called “exercise-bone,” a kind of exostosis.

45. **Subscapularis.**—*Arises* from the ventral surface of the scapula, and is *inserted* into the lesser tuberosity of the humerus. **Nerves.**—The short and middle subscapulars.

46. **Supra-Spinatus.**—*Arises* from the supra-spinous fossa and upper surface of spine, and is *inserted* into the upper facet on the great tuberosity of humerus. **Nerve.**—The supra-scapular.

47. **Infra-Spinatus.**—*Arises* from the infra-spinous fossa, ridges, and fascia, and is *inserted* into the middle facet on great tuberosity. **Nerve.**—The supra-scapular.

48. **Teres Minor.**—*Arises* from the upper two thirds of the dorsal surface of the axillary border of the scapula, and is *inserted* into the lower facet on great tuberosity. **Nerve.**—Branch of the circumflex, with ganglion.

49. **Teres Major.**—*Arises* from the dorsal surface of the inferior angle of the scapula; *inserted*, inner lip of the bicipital groove of the humerus. **Nerve.**—The middle subscapular.

50. **Biceps Flexor Cubiti.**—*Arises*, tip of coracoid process and apex of glenoid cavity (long head); *inserted*, back part of the bicipital tubercle of the radius. **Nerve.**—The musculo-cutaneous. The chief action of this muscle is to flex and supinate the forearm. Like the deltoid, the tendon may ossify, forming a so-called “exercise bone.”

51. **Coraco-Brachialis.**—*Arises*, tip of the coracoid process; *inserted*, inner surface of middle of the shaft of the humerus, opposite deltoid. **Nerve.**—The musculo-cutaneous. The musculo-cutaneous nerve pierces this muscle, and is often known as the *perforans Casserii*.

52. **Brachialis Anticus.**—*Arises*, lower half of the inner and outer surfaces of the shaft of the humerus and septa; *inserted*, base of coronoid process of the ulna. **Nerves.**—The musculo-cutaneous and musculo-spiral.

53. **Triceps.**—*Arises*, below the glenoid fossa of the scapula, posterior surface of the shaft of the humerus, above and below the musculo-spiral groove. **Nerve.**—The musculo-spiral.

54. The following five muscles all *arise* from the inner condyle of the humerus, inter-muscular septa, and fascia of forearm, with **special origins** as follows:—

(a) **Pronator Radii Teres.**—Inner surface of coronoid process; *inserted* into the middle of the outer surface of the shaft of the radius. **Nerve.**—The median. This muscle, when suddenly brought into very active use, as in lawn tennis, is apt to be sprained—"lawn tennis sprain," or "lawn tennis arm."

(b) **Flexor Carpi Radialis.**—No **special origin**; *inserted*, front of base of the second and partly of the third metacarpal bones. **Nerve.**—The median.

(c) **Palmaris Longus.**—No **special origin**; *inserted*, apex of the palmar fascia. This muscle is often wanting. **Nerve.**—The median.

(d) **Flexor Sublimis Digitorum.**—*Arises*, inner edge of coronoid process of the ulna, above the pronator radii teres, and the oblique line in front of the radius; *inserted*, sides of the second phalanges. **Nerve.**—The median.

(e) **Flexor Carpi Ulnaris.**—*Arises*, aponeurosis attached to the posterior edge of the ulna; *inserted*, pisiform bone, fifth metacarpal bone, and annular ligament. **Nerve.**—The ulnar.

55. **Flexor Profundus Digitorum.**—*Arises*, upper two thirds of the anterior and inner surfaces of the shaft of the ulna, aponeurosis attached to the posterior edge of the ulna, and half the interosseous membrane; *inserted*, bases of the third phalanges. **Nerves.**—The ulnar and anterior interosseous branch of median.

56. **Flexor Longus Pollicis.**—*Arises*, upper part of the anterior surface of the shaft of the radius, the interosseous membrane, and sometimes from the inner edge of the coronoid process of the

ulna; *inserted*, base of phalanx of thumb. **Nerve.**—The anterior interosseous of the median.

57. **Pronator Quadratus.**—*Arises*, lower part of ulna; *inserted*, lower part of radius. **Nerve.**—The anterior interosseous from the median.

58. **Supinator Longus.**—*Arises*, upper two thirds of the external condyloid ridge of the humerus; *inserted*, base of styloid process of radius. **Nerve.**—The musculo-spiral. This muscle is a feeble supinator, but is a fairly powerful flexor, when the elbow joint is flexed and the arm held between pronation and supination.

59. **Extensor Carpi Radialis Longior.**—*Arises*, lower third of external condyloid ridge of humerus and septa; *inserted*, back of base of the second metacarpal. **Nerve.**—The musculo-spiral.

60. **Extensor Carpi Radialis Brevior.**—*Arises*, external condyle, lateral ligament, fascia, and septa; *inserted*, back of base of third metacarpal.

61. **Extensor Communis Digitorum.**—*Arises*, external condyle, fascia, and septa; *inserted*, bases of second and third phalanges of the fingers.

62. **Extensor Minimi Digiti.**—*Arises*, as last; *inserted*, joins corresponding tendon of the common extensor.

63. **Extensor Carpi Ulnaris.**—*Arises*, external condyle, fascia, and septa, and aponeurosis attached to the posterior border of the ulna; *inserted*, base of metacarpal bone of little finger.

64. **Supinator Brevis.**—*Arises*, common tendon, orbicular ligament of radius, and depression below lesser sigmoid cavity; *inserted*, posterior and outer surfaces of radius above the oblique line.

65. **Extensor Ossis Metacarpi Pollicis.**—*Arises*, middle third of posterior surfaces of both radius and ulna and interosseous membrane; *inserted*, base of first metacarpal bone.

66. **Extensor Primi Internodii Pollicis.**—*Arises*, posterior surface of radius below the previous muscle, and interosseous membrane; *inserted*, base of first phalanx of thumb.

67. **Extensor Secundi Internodii Pollicis.**—*Arises*, posterior surface of the ulna below the ossis, and interosseous membrane; *inserted*, base of terminal phalanx of thumb. The extensor muscles of the thumb are often sprained by such movements as

wringing clothes: there is swelling along the course of the tendons and on placing the hand over the part, while the patient moves the thumb, a peculiar silky rustling may be felt. It is often known as "washerwoman's wrist," or "washerwoman's sprain."

68. **Extensor Indicis.**—*Arises*, posterior surface of the ulna below the previous muscle; *inserted*, joins corresponding tendon of common extensor.

The previous *eight* muscles are supplied by the posterior interosseous division of the musculo-spiral nerve.

LOWER EXTREMITY.

69. **Tensor Fascia Femoris.**—*Arises*, anterior superior spine and crest of ilium behind it; *inserted*, ilio-tibial band. **Nerve.**—The superior gluteal.

70. **Sartorius.**—*Arises*, anterior superior spine and notch below; *inserted*, upper part of inner surface of tibia, covering gracilis and semi-tendinous. **Nerve.**—The middle or internal cutaneous branch of anterior crural.

71. **Rectus Femoris.**—*Arises*, anterior inferior spine and above brim of acetabulum; *inserted*, upper border of the patella. **Nerve.**—The anterior crural.

Cricket Thigh.—This is an affection of the rectus femoris that arises during the game of football. It is probably due to a sudden strain put on the muscle, not accustomed to the special action it is called upon suddenly to perform. The patient is apt to think it is due to a blow from the opponent's head, elbow, or knee; he has to stop because of the pain and lameness. In the language of the cricket field, his "**pope or poop is taken.**" The rectus femoris is felt tense and rigid, and stands out; and this condition is brought about *suddenly*, and is not due to mere inflammatory effusion, though effusion follows the accident, and may spread round the whole thigh. Its exact nature is doubtful; it may be due to a bruise, partial or complete rupture, and *may* be caused by a blow with the head, elbow, or knee when the muscle is in the act of firm contraction. It is more likely, however, to be due to the sudden strain rupturing a few fibres. It is a very common thing, when a tendon or muscle ruptures, for the patient to think that he has been struck suddenly by some one—as in

rupture of the tendo achillis, "lawn tennis leg," and in the accident now under consideration.

72. **Vastus Externus.**—*Arises*, anterior border and outer surface of great trochanter, outer border of linea aspera and septa; *inserted*, outer border of patella. **Nerve.**—The anterior crural.

73. **Vastus Internus.**—*Arises*, whole length of the side of the linea aspera and septa; *inserted*, inner border of patella. **Nerve.**—The anterior crural. This muscle forms the prominent muscular mass just above the inner side of knee joint; and in cases of knee joint disease, atrophy of this muscle is one of the causes of the great apparent prominence of the internal condyle of femur.

74. **Crureus.**—*Arises*, upper three fourths of the anterior surface of femur; *inserted* into upper border of patella. **Nerve.**—The anterior crural.

75. **Pectineus.**—*Arises*, ilio-pectineal line and surface in front of it; *inserted* into the line from lesser trochanter to linea aspera. **Nerves.**—The obturator and anterior crural.

76. **Gracilis.**—*Arises*, rami of pubes and ischium; *inserted*, upper part of inner surface of the shaft of the tibia, above semitendinosus and below sartorius. **Nerve.**—The obturator.

77. **Adductor Longus.**—*Arises*, by a round tendon just below the crest of the pubes; *inserted*, middle third of inner lip of the linea aspera. **Nerve.**—The obturator. When this muscle is overstretched, as in those who ride much on horseback, it is called " *rider's sprain*;" from its constant use in cavalry soldiers, the tendon is sometimes ossified, forming the " *rider's bone*."

78. **Adductor Brevis.**—*Arises*, front of pubes below the longus; *inserted*, linea aspera and line leading from the lesser trochanter. **Nerve.**—The obturator.

79. **Adductor Magnus.**—*Arises*, outer side of tuberosity of ischium, and rami of ischium and pubes; *inserted*, whole length of linea aspera, crossing obliquely from the outer to the inner side. **Nerves.**—The obturator and great sciatica.

80. **Gluteus Maximus.**—*Arises*, superior curved line, crest above this, side of sacrum and coccyx, great sacro-sciatic ligament; *inserted*, ilio-tibial band and line leading from the great trochanter to the linea aspera. **Nerves.**—The inferior gluteal from the small sciatic, and special branches from the sacral plexus.

81. **Gluteus Medius.**—*Arises*, between superior and middle curved lines and iliac crest; *inserted*, outer surface of the great trochanter. **Nerve.**—The superior gluteal.

82. **Gluteus Minimus.**—*Arises*, between middle and inferior curved lines; *inserted*, anterior border of great trochanter. **Nerve.**—The superior gluteal.

83. **Pyriformis.**—*Arises*, front of sacrum, between the first, second, third, and fourth sacral foramina, edge of great sacro-sciatic foramen, and great sacro-sciatic ligament; *inserted*, posterior part of upper border of the great trochanter. **Nerve.**—From the sacral plexus.

84. **Obturator Internus.**—*Arises*, inner surface of true pelvis, round about and over the obturator membrane; it is joined by the gemelli, and *inserted* into the upper border of the great trochanter. **Nerve.**—Special branch from sacral plexus.

85. **Quadratus Femoris.**—*Arises*, outer edge of tuberosity of ischium; *inserted*, linea quadrati on back of the great trochanter. **Nerve.**—Special branch from sacral plexus.

86. **Obturator Externus.**—*Arises*, outer surface of obturator membrane, and bone round; *inserted*, digital fossa of the femur. **Nerve.**—The obturator.

87. **Biceps Flexor Cruris.**—*Arises*, lower and inner facet on tuberosity of ischium and outer lip of linea aspera; *inserted*, head of fibula. **Nerve.**—The great sciatic.

88. **Semi-Tendinosus.**—*Arises*, with long head of biceps, from the tuberosity of the ischium; *inserted*, upper part of the inner surface of shaft of tibia, below the gracilis and beneath the sartorius. **Nerve.**—The great sciatic.

89. **Semi-Membranous.**—*Arises*, upper and outer facet on the tuberosity of the ischium; *inserted*, posterior part of the inner tuberosity of the tibia, and blends with the internal semilunar cartilage, fascia of popliteus muscle, and posterior ligament of the knee joint. **Nerve.**—The great sciatic. In twists or sprains of the knee joint, there is very usually a tender point over the internal semilunar cartilage, probably from rupture of a few of the fibres of this tendon attached to that structure.

90. **Tibialis Anticus.**—*Arises*, outer tuberosity and upper two thirds of the shaft of the tibia and the interosseous membrane;

inserted, internal cuneiform and base of first metatarsal. **Nerve.**—The anterior tibial.

91. **Extensor Longus Digitorum.**—*Arises*, outer tuberosity of tibia, upper three fourths of anterior surface of shaft of the fibula, interosseous membrane, and septa; *inserted*, bases of second and third phalanges of the four outer toes. **Nerve.**—The anterior tibial.

92. **Extensor Proprius Hallucis.**—*Arises*, middle three fifths of the anterior surface of the shaft of the fibula internal to the common extensor; *inserted*, base of the last phalanx of great toe. **Nerve.**—The anterior tibial.

93. **Peroneus Tertius.**—*Arises*, lower fourth of anterior surface of the shaft of the fibula; *inserted*, base of the fifth metatarsal. **Nerve.**—The anterior tibial.

94. **Peroneus Longus.**—*Arises*, head and upper half of the antero-external surface of the shaft of the fibula; *inserted*, outer side of base of the first metatarsal and internal cuneiform bone. **Nerve.**—The musculo-cutaneous branch of external popliteal.

95. **Peroneus Brevis.**—*Arises*, middle third of the antero-external surface of the fibula; *inserted*, base of fifth metatarsal. **Nerve.**—The musculo-cutaneous.

96. **Gastrocnemius.**—*Arises*, upper and back part of the condyles of the femur; *inserted*, forms part of the tendo achillis. **Nerve.**—The internal popliteal. A few fibres of this muscle are not uncommonly ruptured, especially in middle-aged gentlemen, during the game of lawn tennis; this is known as the "lawn tennis leg." The patient usually thinks he has received a blow from behind from some one's racket.

97. **Soleus.**—*Arises*, back of head and upper third of the posterior surface of the fibula, oblique line and inner border of the tibia, and a fibrous arch between the two bones; *inserted*, forms part of the tendo achillis. **Nerve.**—The internal popliteal.

98. **Popliteus.**—*Arises* from a depression on the outer condyle of the femur; *inserted*, triangular surface on the back of the tibia above the oblique line. **Nerve.**—The internal popliteal.

99. **Flexor Longus Hallucis.**—*Arises*, lower two thirds of the posterior surface of the shaft of the fibula; *inserted*, base of last phalanx of great toe. **Nerve.**—The posterior tibial.

100. **Flexor Longus Digitorum.**—*Arises*, posterior surface of the shaft of the tibia, below the oblique line and internal to the tibialis posticus; *inserted*, bases of the last phalanges of the four outer toes. **Nerve.**—The posterior tibial.

101. **Tibialis Posticus.**—*Arises*, posterior surface of the shaft of the tibia below the oblique line and external to the digitorum, interosseous membrane, and upper three fourths of the inner surface of the shaft of the fibula; *inserted*, tuberosity of scaphoid. **Nerve.**—The posterior tibial.

102. **Extensor Brevis Digitorum.**—*Arises* from the upper surface of the greater process of the os calcis, from the calcaneo-astragaloid and anterior annular ligament, and is *inserted* into the four inner toes, joining the expansion of the extensor tendons—except in the great toe, where it is attached to the base of the first phalanx. The fleshy belly of this muscle gives a sensation extremely like fluctuation, so much so that it is occasionally opened in the belief that an abscess exists. This muscle is much better developed in races that habitually go bare-footed, and is well seen in many of the older works of sculpture. The muscle is fast disappearing before the advance of the modern followers of St Crispin.

CHAPTER XLVII.

TERMS USED IN EYE SURGERY.

Abscission.—The removal of the cornea, with the front part of the sclerotic, as for staphyloma, leaving the posterior part of the globe, with the muscular attachments, to form a movable stump for an artificial eye. To prevent the escape of the contents of the eye, pass four or five curved needles through the base, with silk ligatures attached, and then cut off the protruding parts just in front of the needles; the middle needle is then drawn through, and the suture thus left in position tied; and so for the others. In the old form the sutures were difficult to introduce, the contents apt to escape, and a shrunken, useless stump left.

Amaurosis.—Complete blindness of an eye, without apparent cause.

Amblyopia.—Dullness of sight, short of complete blindness, without apparent physical cause, and with little or no ophthalmoscopic change in the fundus. A very common form is from excessive smoking—*tobacco amblyopia*—usually accompanied by a central colour scotoma, especially for the red and green rays. It is scarcely necessary to point out how important this fact is for all persons who have to do with railway, or naval signals.

Ametropia.—Any permanent defect in the refraction of the eye.

Anchyloblepharon.—Union of the contiguous margins of the eyelids.

Anisometropia.—Unequal refraction in the two eyes.

Arcus Senilis.—A condition caused by fatty degeneration of the corneal tissue, just within its margin. It forms two crescents, which by-and-by meet; it begins beneath the upper lid, and is a senile change, no matter what the patient's age may be.

Asthenopia.—Weakness of the eyes, or any condition in which the eyes cannot be used for long together; in the morning the patient sees well enough, but the eyes soon feel fatigued. There are two forms—(1) **Accommodative**—from insufficiency of the ciliary muscle in hypermetropia, as it is constantly overtaxed in efforts to see near objects. The symptoms are heat, with discomfort, or actual pain in the eyes, a desire to close them, and after the patient reads a short time the letters seem to run together. (2) **Muscular**—from insufficiency of the internal recti in myopia; there is defective power of convergence of the optical axes, as the balance between the action of the ciliary muscle and the internal recti is disturbed.

Astigmatism.—A form of ametropia due usually to irregular curvature of the cornea. It may be *regular* or *irregular*. In **regular**, the meridians of greatest and least refractive power are always at right angles to each other, and, as a rule, the one of greatest refractive power is vertical, or nearly so; and, of course, the rays passing through this meridian are brought to a focus before the rays passing through the other meridians. In **irregular** it is not so, as this condition is due to the result of corneal wounds or ulcers, conical cornea, etc. **Regular** may be—(1) *Simple*, where one meridian is natural, but the meridian at right angles is either myopic or hypermetropic. (2) *Compound*, where all the meridians are either myopic or hypermetropic, but one is more so than the other. (3) *Mixed*, where, for example, the meridian of least refraction is hypermetropic, and the one of greatest refraction is myopic.

Blepharitis.—Inflammation, with the formation of pustules on the edge of the eyelids, at the points where the eyelashes emerge from the skin, with inflammation of the hair follicles, as well as of the skin.

Blepharospasm.—Spasm of the orbicularis palpebrarum, often very markedly present in superficial strumous ulcers of the cornea (*phlyctenular conjunctivitis*).

Buphthalmos (Ox-Eye).—A disease probably allied to glaucoma, which comes on in very early life, affects both eyes, and causes great defect of sight. The eye is enlarged in all its diameters, the anterior chamber very deep, the cornea usually hazy, and the tension slightly increased.

Cataract.—Opacity of the crystalline lens, from any cause; it is due to some change in the composition or structure of the lens fibres. There are many forms, and below the age of thirty-five years are all soft, but above this age are usually hard. (1) The **Nuclear**, begins in the centre of the lens; usually in old people, and is hard. (2) The **Cortical**, begins in the superficial parts, as lines or triangular patches, shooting in towards the centre. It begins at the edge of the lens, and, like the last, is usually found in old people, and is hard. (3) The **Lamellar** or **Zonular**—In this the nucleus and the superficial layers of the lens are clear, but there is a zone of opacity between them. It is present at birth, and will probably remain stationary for life; the subjects of this condition often suffer from infantile convulsions. If the area affected be not very large, perform an *iridectomy* downwards and inwards. The objection to this is the slight permanent deformity. If the affected area nearly involve the whole cornea then remove by "*solution*," letting the remains of the lens out at the lower part. This is one of the most risky forms of cataract operation. Only do one eye at a time, and watch the result very carefully. (4) **Pyramidal**, or **Anterior Polar**—A small, well-defined spot in the middle of the pupil, at the anterior pole of the lens, due to a previous localised inflammation of the lens capsule and the layers below it; it is stationary, and is the result of perforating ulcer of the cornea, usually from ophthalmia neonatorum. (5) The **Posterior Polar**—This begins as a thin layer at the middle of the posterior surface of the lens. It is often associated with disease of the interior of the eye, as retinitis pigmentosa, disease of the vitreous, severe choroiditis, etc. In the congenital forms of cataract, nystagmus is often present.

For **Traumatic Cataract**, see *Discission*.

"**Cat's Eye.**"—An appearance noticed in glioma of the retina. The pupil has a peculiar glistening appearance, or metallic-like lustre. The patient is usually a child, and the mother or nurse notices the peculiar appearance of the pupil, and consults the medical attendant about it. It is supposed to resemble a cat's eye. In the earlier stages it may be mistaken for **suppurative choroiditis** ("*scrofulous deposit*"). In glioma, however, the tension is *plus*, whereas in suppurative choroiditis it is *minus*.

Further, in glioma the growth goes on increasing, destroys the cornea, and projects from the eyeball; but in suppurative choroiditis the eyeball soon begins to shrink.

Chalazion.—A little cyst or tumour, formed by obstruction to, or overgrowth of, a meibomian gland.

Chemosis.—Effusion into the cellular tissue connecting the conjunctiva with the eyeball, raising it in a ridge around the cornea: it accompanies some of the more severe forms of conjunctivitis, as *ophthalmia neonatorum*.

Coreodialysis.—A tearing away of the iris from its ciliary attachment, as from a blow or concussion, but without rupture of the hard coats of the eye; this takes place because the iris is not very firmly adherent at its insertion (the *ligamentum pectinatum*).

Corelysis.—An operation for the purpose of freeing the iris from posterior adhesions to the front of the lens capsule, either by means of a spatula-like hook to tear them, or fine cannula scissors to cut them, introduced through an incision at the corneal margin, usually at a point opposite to that of the adhesion.

Cyclitis.—Inflammation of the ciliary processes; it is rarely found alone, but is usually associated with inflammation of the iris, sclerotic, or cornea. The signs resemble those of iritis, but vision is more impaired than one would expect for the appearances present, and the eye in the ciliary region is very tender to touch.

Dacryo-Cystitis.—Inflammation of the lachrymal sac.

Discission.—The method of treating cataract by solution. The pupil is first dilated, then a needle is introduced, and the capsule of the lens lacerated, and the lens substance broken up; it is then gradually absorbed by the action of the aqueous humour. It is also called *Keratonyxis*. Severe blows on the eye may also rupture the lens capsule, when the aqueous humour enters and is imbibed by the lens fibres, which swell up, speedily become opaque, disintegrate, and are finally absorbed: this is called *traumatic cataract*.

Distichiasis.—Where there seem to be two rows of eyelashes; one is in the normal position, the other is misdirected and rubs against the globe.

Ectropion.—Eversion of the edge of the lid or lids.

Emmetropia.—Normal vision. When the accommodation is relaxed, parallel rays, or rays from distant objects, are focussed on the retina; but divergent rays, or rays from a near object, are focussed behind the retina.

Entropion.—Inversion of the border of the eyelids, from any cause, such as organic change in the tissue of the lids or spasm of the orbicularis.

Exclusion of Pupil.—Where the whole pupillary margin or the entire posterior surface of the iris is adherent to the lens capsule; also called "*total posterior synechia*."

Hemeralopia.—"Day-blindness;" occasionally met with in persons from the East or West Indies.

Hypermetropia.—The "long sight" of young people. Parallel rays, when the accommodation is relaxed, are not focussed on, but fall behind the retina, and therefore to see *distant* objects the patient must use active accommodation. It is due either to deficient refractive power, or else to shortness of the antero-posterior axis of the eyeball; hence there is a constant strain of accommodation. It always dates from birth and does not increase afterwards, and often causes convergent squint, from the excess of accommodation required. It is measured by the refractive power of the *strongest convex lens* through which he can see distant objects clearly. It may be—(1) **Manifest**, or that part of accommodation that the patient can voluntarily relax, but he never relaxes his power of accommodation completely: this is measured by the strongest convex lens through which he can see distant objects clearly. After having noted this, then put atropia into his eye, when he will now see clearly through a stronger convex lens than before; this is called (2) **Latent hypermetropia** = that masked by accommodative effort, and which he is unable to suspend at will. The manifest and the latent added together give the **Total hypermetropia**.

Hyphæma.—Blood in the lower part of the anterior chamber.

Hypopyon.—Pus in the lower part of the anterior chamber; often associated with the superficial spreading septic ulcer of the cornea ("**Serpiginous Ulcer**").

Irideremia, Congenital.—Congenital absence of the iris.

Iridodesis.—A method adopted by Mr CRITCHETT for making an artificial pupil. A loop of iris is drawn out through a small opening and strangulated by a noose of fine waxed silk ligature; it is difficult to do, but leaves a very neat opening. It is, however, apt to be followed, it may be years after, by inflammation of the iris and ciliary processes—irido-cyclitis, and even sympathetic ophthalmia of the other eye.

Iridotomy, or Iritomy.—Another method of operating for artificial pupil, but is limited to cases where the lens is absent. An incision is made through the cornea and sclerotic junction at a point *furthest* from that part of the eye where the artificial pupil is to be. The iritomy scissors is next introduced closed, and when near the iris it is opened, and the sharp-pointed blade either passed behind the iris or made to perforate it; the iris is then divided by a single snip as nearly as may be across its fibres, which then retract and leave an elliptical opening. It is used after cataract extraction, in cases where the iris has become tightly fixed in the scar tissue, either from iritis or prolapse.

Iris, Tremulous (Iridodonesis).—A condition in which the iris is seen to tremble or shake about with every movement of the eye, having lost its firm posterior support. It is found, therefore, in cases where the lens is displaced, or where the vitreous humour is unusually fluid, as from disease of the choroid, and after cataract extraction.

Keratitis.—Inflammation of the cornea; the common form is interstitial syphilitic keratitis, which shows no tendency either to pus formation or to ulceration. It is most common between the ages of six and sixteen. Its course is very slow, and it is apt to cause myopia.

Leucoma.—A dense, white, opaque spot on the cornea, left after the healing of an ulcer; if the opacity be very faint, it is called *nebula*.

Lippitudo.—A raw irritable condition of the edge of the eyelids, following the loss of all the eyelashes, as in blepharitis ciliaris.

“Live Blood.”—Spontaneous twitching, especially of the lower lid, met with in some cases of hypermetropia, when the digestion is out of order.

Myosis.—Persistent contraction of the pupil; this is found in hyperæsthesia of the retina, in cases also where the vessels of the iris are full of blood, in cases of nervous disease where the sympathetic fibres to the iris are paralysed, or where the third is stimulated, in cerebral concussion, and from the use of drugs, as Calabar bean, locally—opium and chloral hydrate, internally.

Myopia.—“Short-sightedness.” Parallel rays are brought to a focus in front of the retina even when all accommodative efforts are suspended. It is usually due to elongation of the antero-posterior axis of the globe. Distant objects cannot be seen, but near objects can if held close to the eye. The amount is measured by the refractive power of the *weakest concave lens* that enables the eye to discern distant objects distinctly—an object twenty feet off. In myopic patients there is a great liability to liquefaction of, and opacities in, the vitreous, cortical cataract, and detachment of the retina.

Nyctalopia.—“Night blindness,” or want of sight in the dusk; vision is good in bright light, but in the dusk require to be led. This condition is found in *retinitis pigmentosa*, and sometimes in syphilitic choroido-retinitis.

Nystagmus.—Involuntary oscillating movement of the eyes: associated with congenital defects of sight, or defects produced soon after birth—*e.g.*, by ophthalmia neonatorum. It is also found in coal-miners, and in some forms of cord disease.

“**Occlusion**” of Pupil.—When the orifice is filled up by inflammatory products, which organise into a thin membrane.

Onyx.—Pus between the lamellæ of the cornea, which usually sinks to the lowest part.

Ophthalmia.—All forms of inflammation of the conjunctiva are included in this term.

Ophthalmoplegia.—Paralysis of the muscles of the eyeball. (1) **Ophthalmoplegia externa** = paralysis of all the *external* muscles of the eye, met with sometimes in locomotor ataxy, syphilis, diphtheria, cold, and alcohol. (2) **Ophthalmoplegia interna** = paralysis of the three internal muscles of the globe—ciliary muscle, dilator, and sphincter pupillæ. When the *ciliary* muscle alone is affected, it is called *Cycloplegia*; when the muscles of the *iris* alone, *Iridoplegia*.

Panophthalmitis.—Purulent inflammation of the interior of the globe; it usually starts as a septic traumatic cyclitis.

Photophobia.—Fear or intolerance of light; very well seen in superficial strumous ulcers of the cornea.

Photopsia.—An appearance or sense of light, from internal causes (a *subjective* sensation).

Pinguecula.—A small yellowish fatty-like spot close to the inner or outer edge of the cornea.

Presbyopia.—The “long sight” of old people. It is an affection of accommodation, due to weakness of the ciliary muscle, and other alterations in the interior of the eye. Patients thus affected hold objects further from the eye than usual, and try to get into a good light.

Pterygium.—A triangular patch of thickened ocular conjunctiva, the apex of which encroaches upon the cornea.

Ptosis.—Drooping or falling of the upper eyelid, as from paralysis of the third nerve.

Scotoma.—An area of defect or blindness in the visual field.

Staphyloma.—A bulging of the sclerotic or cornea in front, of the sclerotic behind, and therefore spoken of as *anticus* and *posticus*.

Stye (Hordeolum).—A little boil at the edge of the eyelid, due either to suppurative inflammation of the connective tissue or of one of the meibomian glands.

Symblepharon.—Adhesion of the palpebral and ocular surfaces of the conjunctiva, as from burns or scalds, by fire or caustics.

Synechia.—Adhesion of the iris to the lens capsule or the back of the cornea, either by tags here and there or all the way round; if to the lens capsule, it is called *posterior*; to the back of the cornea, *anterior*.

Trachoma.—Another name for granular lids or granular ophthalmia. It is probably due to a micro-organism.

Trichiasis.—A condition where the eyelashes are misdirected and rub against the globe.

“Yellow Gum,” the popular name for *ophthalmia neonatorum*, probably because the pus is yellow, and gums the lids together.

CHAPTER XLVIII.

ADDENDA.

MANY of the points in this Chapter have been inadvertently left out in the body of the book.

Annandale's Operation for Displaced Semilunar Cartilage.—**Instruments required.**—A knife, artery forceps, ligatures, dissecting forceps, blunt hooks, sponges, sutures, needles, and dressings.

A transverse incision is made, parallel with, and just over, the head of the tibia, and the displaced cartilage, on the injured side. The incision extends from near the edge of the ligamentum patellæ backwards for about three or four inches. If this does not expose the cartilage properly, it may be supplemented by another incision, at right angles to it, upwards or downwards as the case may require. The various structures are cut through, till the capsule of the joint is exposed; all bleeding vessels are then secured, and the joint opened. The displaced cartilage is next hooked into the wound, by means of a blunt hook, and stitched to the periosteum of the head of the tibia with catgut sutures. The wound is then closed, and dressed antiseptically. In certain cases, where the cartilage seems affected with fatty degeneration, Professor ANNANDALE removes it altogether. This does not seem to affect the usefulness of the joint in the very least (see vol. i., page 405).

Annandale's Operation for Displaced Cartilage of the Lower Jaw.—A slightly-curved incision, three-quarters of an inch long, is made over the posterior edge of the lateral ligament, and carried down to the capsule. All bleeding vessels are then tied, the capsule opened, and the cartilage seized and drawn into position. It is then stitched to the periosteum and other tissues, at the outer margin, by catgut sutures (see vol. ii., page 41).

Ogston's Operation for Flat-Foot.—In cases of flat-foot, the treatment will necessarily vary with circumstances.

1. In the acute and painful stage, absolute rest is necessary, till all the acute symptoms and pain subside. It is worse than useless to attempt to do anything else in this stage.

2. When the acute symptoms have subsided, and provided "stiff big-toe" be absent, then the proper treatment is calisthenics for the feet. The patient must practise rising on tip-toe several times a-day, and then attempt to walk on tip-toe—in short, he must endeavour to execute the various movements of an accomplished ballet-dancer.

3. In cases where the patient has much standing during the day, he should be provided with an artificial arch, to give him support, *while he is standing*. In the evening he should remove the arch, and practise foot calisthenics. It should be remembered that an artificial arch, while it may prevent the condition becoming worse, will not *cure* the deformity; besides, in many cases, the patient is unable to wear it.

4. In those cases where "stiff big-toe" is present, it will be impossible to adopt calisthenic treatment. For this class of cases, Professor CHIENE'S plan should be adopted—viz., to insert a rigid, slightly-curved steel plate into the sole of the boot. This prevents all pressure on the tip of the big-toe, and, consequently, all movement at the painful joint—the metatarso-phalangeal of the big-toe. In certain cases, OGSTON'S operation may be adopted.

5. **Ogston's Operation.**—An incision is made along the inner side of the foot, into the mediotarsal joint, the soft parts shelled off the bones, so as to expose the articulation sufficiently, and then, by means of an ordinary chisel, the head of the astragalus and the back of the scaphoid are denuded of their cartilage, so as to be adapted for osseous ankylosis. In old cases of the deformity, the head of the astragalus, grown out of shape, has to be rounded off, so that it can be restored to its proper position before the arch of the foot can be replaced in its original shape. An assistant holds the arch in the right position, and then two pegs of carefully disinfected ivory, three inches long, are hammered into two holes drilled through the scaphoid and astragalus. This fixes the arch, and when the spare ends of the pegs have been nipped off, and

the wound sutured, the joint heals, by bony ankylosis, under a plaster-of-Paris bandage (see vol. i., page 407).

Watson Cheyne's Operation for Bunion.—After the parts have been thoroughly disinfected, a longitudinal incision is made over the inner and dorsal surface of the metatarso-phalangeal joint, the soft parts being divided down to the bone. The periosteum on the inner side is then stripped away, and a vertical slice of the thickened bone sawn off, a small portion of the articular surface being also removed. A portion of the subcutaneous tissues on the inner side of the joint may also be removed. The toe is then brought straight and pressed upwards. The wound is next stitched, antiseptic dressings applied, and two splints fixed, one on the inner side to keep the toe inwards, and one beneath to keep it upwards. After the wound has healed the foot may be put up in some permanent dressing—*e.g.*, silicate bandages. Mr CHEYNE states that the essential cause of the *persistence* of a bunion is the thickening of the end of the metatarsal bone, and this thickened mass must be removed before a cure can be attempted. The toe is displaced in a two-fold direction—everted and depressed, so that it must be pressed upwards as well as drawn inwards.

The *original cause* of bunion is badly-fitting boots—narrow-toed and tapering along the inner border of the foot. The big toe is pressed outwards, and the bursa that naturally exists over the ball of the great toe is irritated and becomes inflamed. If the patient will submit to wear easily-fitting, though probably ugly, boots no operation need be performed at all (see vol. ii., page 194).

Bursæ.—In addition to the usually recognised bursæ about the hands and feet, the late Professor SYME pointed out that there was a series of *superficial bursæ*, just under the integument over all the joints of the fingers and toes. Even the so-called adventitious bursæ, met with over the external malleolus in tailors (“**Tailors' bursa**”), and on the outer border of the foot in cases of aggravated talipes equino-varus, he stated, were only enlargements of previously existing bursæ.

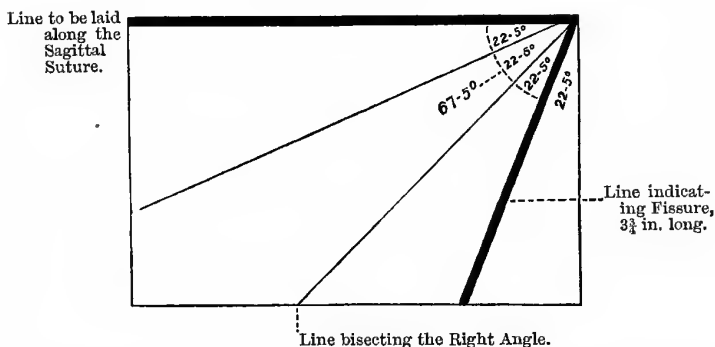
Maclaren's Operation for Varicose Veins.—Dr MACLAREN believes that varicose veins are, to a great extent, due to laxity of the integumentary structures, and that, if this does not predispose to them, it certainly keeps up the condition. As a means,

therefore, of radical cure, in cases of varicose veins of the leg, he removes an elliptical portion of skin from the calf. This braces up and supports the varicose veins, like a well-fitting, natural elastic stocking (see vol. ii., page 173).

Hare's Angle.—Professor HARE states that the fissure of ROLANDO forms an angle of sixty-seven degrees with the sagittal suture. This angle can very easily be found by means of an ordinary half sheet of paper, or the corner of a newspaper for that matter—in short, any piece of soft material cut at a right angle. The right angle is first bisected by carefully doubling the paper over. After this the paper is again folded so as to bisect the

Fig. 235.

HARE'S ANGLE.



angles of forty-five degrees first formed. The right angle is thus divided into four equal angles of 22.5 degrees each. Three of these are added together, which gives an angle of 67.5 degrees, which is near enough for all practical purposes. The edge of the paper is then laid upon the sagittal suture, so that the angle corresponds with the point that indicates the upper end of the fissure of Rolando—viz., half-an-inch behind a point midway between the root of the nose and the external occipital protuberance. The fissure passes downwards and forwards for three and three-quarter inches (Fig. 235; see also vol. ii., page 78).

"Wilde's Line."—This is a line drawn from the apex of the mastoid process upwards at right angles to the sagittal suture. It is about half or three-quarters of an inch from the auricle. It is in this line that "**Wilde's incision**" is made, in cases where it is necessary to cut down to the mastoid process in ear disease, as it is behind the posterior auricular artery. It is also a very useful guide in the operation of trephining the mastoid antrum. The trephine or gimlet is entered in this line, on a level with the upper border of the external auditory meatus, and then worked in a direction parallel with the meatus, *i.e.*, inwards, forwards, and slightly upwards. Mr TREVES introduces a pencil into the meatus, and then keeps the shaft of the gimlet parallel with that. A gimlet is much better than a trephine, as one has more command over it. The antrum varies in **size** from a pea to a small bean. In Fig. 119 (see vol. i., page 576), it is three-sixteenths of an inch in height, and five-eighths of an inch in length.

Its Outer Bony Wall.—The petro-squamous suture closes during the first year of extra-uterine life. Its existence during that period, however, is no doubt a very frequent cause of death from ear disease in the case of children. In the foetus there is hardly any mastoid process, and the outer wall of the antrum is very thin. About this period the mastoid process begins to grow in a peculiar manner. There is a continuous formation of new bone from the periosteum, which is laid down layer after layer on the surface of the old, so that the external and inferior walls of the antrum become gradually thicker and thicker. In a new-born child, the outer wall is only 1 or 2 mm. thick; by the age of five years it is about 6 mm., while at nine or ten years of age, it is about 1 cm. deep (SYMINGTON). In the adult, it is about 1.5 cm. deep, or three-fifths of an inch. The new bone is at first finely cancellous. About puberty this tissue undergoes a process of partial absorption, by which it is converted into a number of communicating air cells, which are lined by a delicate mucous membrane. In the adult, the chances of extension of the inflammation to the lateral sinus are much greater than in children. In children there is a thick layer of fine cancellous tissue between the mastoid antrum and the lateral sinus; but this may be converted in the adult into air cells, some of which are only separated by very

thin bony septa from the sinus (SYMINGTON). Intra-cranial complications more often follow disease of the middle ear on the **right side**, because the right lateral sinus is larger than the left, and consequently the bony wall between it and the mastoid cells is thinner than on the left side (KÖRNER). Middle ear disease in early life is a common cause of **Deaf-mutism**. Mr HULKE has specially pointed out that hemiplegia, coming on with signs of compression many weeks after a head injury, indicates very certainly the existence of a cerebral abscess (see vol. i., page 574).

In opening an **Abscess of the Middle Ear**, an incision is made through the lower and posterior part of the membrane tympani, for reasons already pointed out (see vol. i., page 559). In this connection, observe the **size of the tympanic cavity**. It measures about five lines from before backwards, three lines in the vertical direction, and between two and three in the transverse—that is, not quite a quarter of an inch. The width of the tympanum varies from one-twelfth to one-sixth of an inch (QUAIN). It is a little broader behind and above than it is below and in front. Now, unless the Surgeon be careful, he is apt to introduce the knife too deeply and strike the inner wall, the result being that he punctures or divides the facial nerve, an accident that has actually happened.

Cerebral Abscess.—It is only when the abscess is *circumscribed* that we meet with the characteristic symptoms (see vol. i., p. 570). The moment the pus bursts its limiting wall, whether into the brain substance or into the lateral ventricles, the symptoms entirely change. Instead of low temperature, slow pulse, and coma, we find a high temperature, severe pain, rapid pulse, and delirium; the same symptoms are also observed in pyæmic abscesses—*e.g.*, in ulcerative endocarditis, which has been mistaken for acute mania. The tension in cerebral abscesses is often so great as to be almost past belief. Mr HULKE says he has seen the pus ejected with such violence as not only to bespatter the operator, but to be driven half-way across the operating-room.

Lymphatic Glands of the Neck.—In speaking on this matter (see vol. ii., p. 131), I ought to have pointed out more particularly the glands often found in the *middle line* of the neck. There is one just below the symphysis menti, another about the region of

the crico-thyroid membrane, and a third just above the episternal notch. Any of these may suppurate, when we will have an abscess in the middle line.

Spinal Accessory Nerve.—The *spinal* portion of this nerve arises from the lateral tract of the cord, as low down as the sixth cervical nerve. It ascends *between the ligamentum denticulatum and the posterior roots of the spinal nerves*, enters the skull through the foramen magnum, and joins the **accessory** portion. This nerve supplies the sterno-mastoid, and communicates, in the substance of that muscle, with the *third* cervical nerve. In the occipital portion of the posterior triangle of the neck, it communicates with the *second* and *third* cervical nerves; and, after passing under the trapezius, it is joined by branches from the *third, fourth, and fifth* cervical nerves.

Cerebral Sinuses.—These are fifteen in all—five single and five paired.

The Single Sinuses are:—

1. *The Superior Longitudinal*, which runs along the upper border of the falx major, from the crista galli to the internal occipital protuberance. It commences in a small vein, which enters the skull from the nose through the foramen cæcum. On section, it is triangular, with the base of the triangle upwards. Its tributary veins open into it at acute angles from behind forwards—*i.e.*, contrary to the current of blood in the sinus itself. Within the sinus are small tendinous cords—*chordæ Willisii*.

2. *The Inferior Longitudinal*, which runs along the lower border of the falx major, as far as the tentorium cerebelli, and there opens into the straight sinus.

3. *The Straight Sinus* runs along the junction of the falx major with the tentorium. It is formed by the *veins of Galen* and the inferior longitudinal sinus, and opens into the torcular Herophili, thus connecting the two longitudinal sinuses together. The **veins of Galen** return the blood from the lateral ventricles, the basal ganglia, and the interior of the brain generally.

4. *The Circular Sinus* surrounds the pituitary body in the sella turcica, and forms a communication between the two cavernous sinuses.

5. *The Transverse or Basilar Sinus* crosses the basilar process, and forms a communication between the two inferior petrosals.

The **Paired Sinuses** are :—

1. *The Cavernous Sinuses* (see vol. i., page 519).

2. *The Inferior Petrosal Sinuses* pass from the cavernous sinus and open into the lateral sinus outside the skull, passing through the jugular foramen, in front of the eighth pair of nerves. They groove the contiguous margins of the petrous part of the temporal bone and the occipital bone.

3. *The Superior Petrosal Sinuses* pass from the cavernous sinus along the upper border of the petrous part of the temporal bone to the lateral sinus. The petrosal sinuses are apt to be torn in fractures of the petrous portion of the temporal bone—giving rise to the **passive form** of cerebral hæmorrhage, as opposed to the **active arterial form**.

4. *The Occipital Sinuses* are found along the attachment of the falx cerebelli.

5. *The Lateral Sinuses* are the largest of the cerebral sinuses, and, commencing at the torcular Herophili, take a curved course to the jugular foramen on each side. Each sinus grooves the following bones—occipital, parietal, temporal, and occipital again. The sinuses receive the mastoid veins through the mastoid foramina, and end in the internal jugular veins, practically returning the whole of the blood from the brain. Just external to the jugular foramen, the lateral sinus is joined by the inferior petrosal, this coalescence forming the internal jugular vein.

The most important sinuses, from a Surgical point of view, are the cavernous and the lateral. The former, because of abscesses and tumours in the temporo-sphenoidal lobes, causing pressure upon them; and the latter, because of the great risk of mastoid disease giving rise to septic thrombosis and pyæmia.

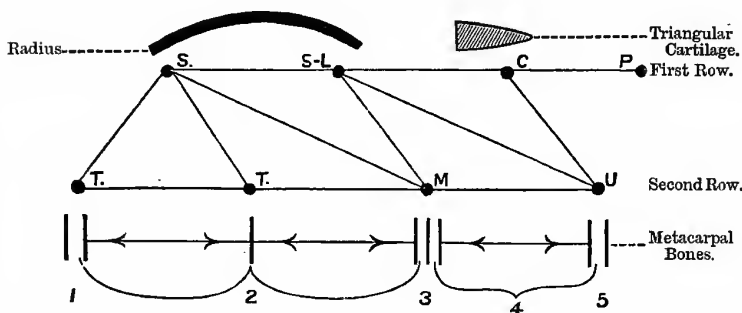
Sinuses differ from Veins—(1) Because they are enclosed in sheaths of dura mater, to which they are firmly attached, so that they remain patent when divided; further, they have no muscular coat. (2) They have no valves. (3) The veins open into them in a direction contrary to the flow of the blood within them.

Articulations of the Carpal Bones.—The bones of the carpus are eight in number, and are arranged in two rows, thus:—

Radius.			
Scaphoid.	Semilunar.	Cuneiform.	Pisiform.
Trapezium.	Trapezoid.	Os magnum.	Unciform.

Fig. 236.

ARTICULATION OF CARPAL BONES.

**Articulations.**—(Fig. 236).**First Row.**

1. *Scaphoid*.—Five bones.
Radius, trapezium, trapezoid, os magnum, and semilunar.
2. *Semilunar*.—Five bones.
Radius, os magnum, unciform, scaphoid, and cuneiform.
3. *Cuneiform*.—Three bones.
Semilunar, pisiform, and unciform. Above, it articulates with the triangular fibro-cartilage.
4. *Pisiform*.—One bone.
The cuneiform.

Second Row.

1. *Trapezium*.—Four bones.
Scaphoid, trapezoid, and the first and second metacarpal bones.

2. *Trapezoid*.—Four bones.

Scaphoid, second metacarpal, trapezium, and os magnum.

3. *Os Magnum*.—Seven bones.

Scaphoid, semilunar, second, third, and fourth metacarpals, trapezoid, and unciform.

4. *Unciform*.—Five bones.

Semilunar, fourth and fifth metacarpals, cuneiform, and os magnum.

Articulations of the Tarsal Bones.—The bones of the tarsus are seven in number :—

Articulations.1. *Os Calcis*.—Two bones.

Astragalus and cuboid.

2. *Cuboid*.—Four bones.

Os calcis, external cuneiform, and the fourth and fifth metatarsals. Sometimes it touches the scaphoid.

3. *Astragalus*.—Four bones.

Tibia, fibula, os calcis, and scaphoid.

4. *Scaphoid*.—Four bones.

Astragalus and the three cuneiform bones. Sometimes it touches the cuboid.

5. *Internal Cuneiform*.—Four bones.

Scaphoid, middle cuneiform, and the first and second metatarsals.

6. *Middle Cuneiform*.—Four bones.

Scaphoid, the internal and external cuneiform, and the second metatarsal.

7. *External Cuneiform*.—Six bones.

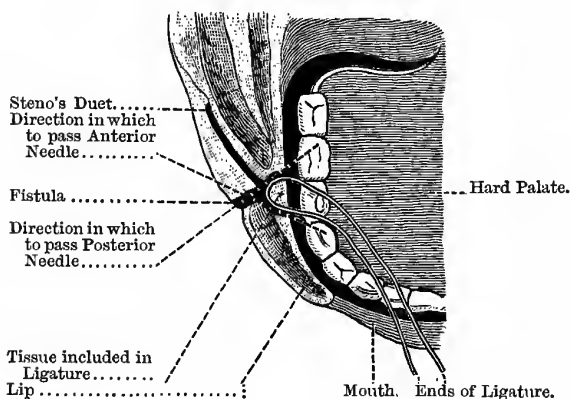
Scaphoid, middle cuneiform, cuboid, and the second, third, and fourth metatarsal bones.

It will be observed, that the tarsal bones, on an average, articulate with *four* bones each, but that the first (the os calcis) articulates with *two less* than the average, while the last (the external cuneiform) articulates with *two more* than the average.

Salivary Fistula.—Deguise's Operation.—As already stated (see vol. ii., page 29), in order to cure this condition, we must make it easy for the saliva to go the right way; in other words, to make the opening into the mouth large and free. A silk thread of some length is taken, and a needle attached to each end. One needle is then passed through the fistula, and directed inwards and backwards through the cheek into the mouth, and the end of the thread brought out; the other needle is next to be passed through the fistula in a similar manner, but must be directed inwards and forwards. In this way a wedge-shaped piece of tissue of the inner surface of the cheek is included in the loop of the thread (Fig. 237).

Fig. 237.

OPERATION FOR SALIVARY FISTULA.



The two ends are then to be tied tightly inside the mouth, and the knot is allowed to ulcerate through the included tissue into the cavity of the mouth. In this way a free opening is secured into the mouth. The fistula will then usually close spontaneously, but if not, Dr DUNCAN'S operation for fistula may be performed (see vol. ii., page 53).

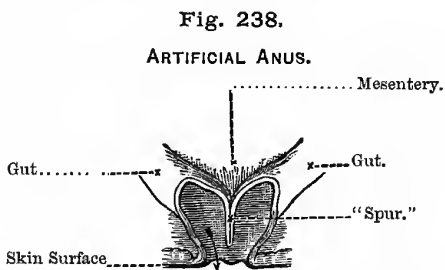
Head in Congenital Syphilis.—In addition to the points already enumerated (see vol. i., p. 535, and vol. ii., p. 85), the following should be noted:—(1) The high and narrow palate—not always

present; (2) the forehead is grooved horizontally, just above the eyebrows; (3) a transverse projection above this; (4) the earthy or muddy complexion; (5) the thin, brittle hair; (6) the thick upper lip, due to prolonged rhinitis; (7) the thickened bones of the head, whereby (8) the vertex is flattened, (9) the forehead is rendered prominent, and (10) the occiput widened. Congenital syphilis is also a common cause of deafness. A highly-arched palate is often found in idiots.

Operation for the Cure of Artificial Anus.—The Stages of the Operation are:—

1. Destruction of the spur or *éperon*.
2. Closure of the fistula.

The “spur” is formed by the posterior part of the circumference of the two ends of the bowel. Their walls, supported one against another, constitute a sort of valvular partition, which prevents the free passage of their contents from the upper to the lower end of the gut (Fig. 238).



The Arrow indicates the course of the contents of the Bowel.

1. The “spur” is to be destroyed by DUPUYTREN’S *enterotome*. Its rapid removal by the knife or scissors, or more slowly by ligature, is apt to open into the peritoneal cavity and set up fatal septic peritonitis. To avoid this, DUPUYTREN uses the *enterotome*. It is composed of two blades, which can be introduced separately—one into the upper, and the other into the lower end of the bowel. The blades are then joined together, as in the case of the midwifery forceps, and firmly pressed together by means of a screw.

This instrument serves a double purpose—(1) It secures adhesion between the adjoining walls of the bowel, and (2) it slowly separates the “spur,” which usually falls off about the end of the seventh or eighth day. The “spur” is seized between the teeth of the instrument and gradually compressed, so that it sloughs off from the wall of the bowel. Before this, however, the peritoneal surfaces are firmly adherent, and the peritoneal cavity thus completely shut off from the cavity of the bowel.

2. The next step is to close the fistula. This is to be accomplished, *not* by paring the edges, but by DUNCAN’S method (see vol. ii., page 53).

Lesions in Cortex and Substance of the Brain.—Lesions of the **cortex** reach their maximum gradually, are incomplete, and more or less limited. A monoplegia, advancing progressively towards a hemiplegia, is very significant of a cortical lesion. It is further very often preceded by, or associated with, monospasm or the “early rigidity” of the paralysed limb; this is indicative of an *irritating*, not a *destroying* lesion. Consciousness is less frequently lost in cortical lesions, and there is often localised pain in the head. Cortical lesions may involve the psychical centres for vision and hearing, inducing “**word-blindness**” and “**word-deafness** ;” that is to say the patient is unable to translate written symbols into ideas, or understand spoken words. The perceiving centres are abolished, although the will power remains.

The features of a lesion of the **substance** (central) of the brain are, roughly speaking, the reverse of the above. Central lesions reach their maximum at once, and are complete, affecting the whole of one side—hemiplegia. It is rarely preceded by, or associated with spasm of the parts affected. The rigidity of the paralysed side is usually “late,” not “early”—the symptoms, in fact, pointing to a *destroying* lesion, rather than an irritating one. Consciousness is usually lost, but there is rarely marked pain in the head. The psychical centres are left intact, though the motor and co-ordinating powers are abolished; the patient knows well enough what to say, but is unable to say it. In short, though he is speechless he is not wordless. A slowly advancing hæmorrhage on the surface of the brain, *e.g.*, from the middle meningeal artery, will illustrate a cortical lesion; while rupture of the lenticulo-striate artery is an

example of a central lesion. If, however, the blood for the middle meningeal artery be poured out very rapidly, then the symptoms will rather resemble a central lesion.

If, along with symptoms of concussion, there be convulsive movements, often of a rythmical character, affecting groups of muscles, or more general convulsions, the injury is probably **laceration** of the surface of the brain. The convulsive movements generally affect the limbs of one side more than the other, and are usually best marked on the side opposite to that on which the brain has been injured.

In **Contusion of the Brain**, the patient exhibits great irritability of manner, lies curled up with all his limbs flexed, his eyelids closed, and resents all interference on the part of attendants (= "**Cerebral irritation**"). There is no heat of head, and the pulse, though weak, is not frequent. There is a marked desire to be "let alone," with muttering, frowning, and grinding of the teeth, if disturbed.

In connection with injuries of the head it should be noted that there may occasionally be permanent **Loss of Memory** of the incidents of a few hours or days preceding the injury (BELL). This may be of considerable medico-legal importance.

INDEX.

INDEX.

- Abdomen, 261
 Colloid cancer of, 337
 Cutaneous nerves, 266
 Protuberance of, 269
 Regions, 261
 Surface anatomy of, 261
 Tapping the, 335
- “Abdominal belt,” 266
 Operations, 271, *et seq.*
 Parietes, anterior, 263
 Lateral, 267
 Posterior, 295
 Ring external, to feel the, 341
 Internal, position of, 342.
 Viscera, 261
 Walls, 263, 267
- Abscess, anal, 396
 Of antrum, 117
 Areola, 226
 In axillary region, 138
 Of breast, in female, 226
 Of bursa patellæ, 178
 About cervical region, 27
 Of cord, 396
 Under diaphragm, 270, 279
 Dorsal, 503
 Ear, middle, 553
 In frontal sinuses, 113
 Gluteal, 503, 504
 Hilton's method of opening, 97, 138
 In hip disease, 168
 Acetabular, 168
 Arthritic, 168
 Femoral, 168
 Iliac, 504
 Ischio-rectal, 394
 Lateral pharyngeal, 27
 Of liver, 314
 Lumbar, 504
 Mammary, 226
 Parotid, 96
 Opening of, 97
 Pelvic, 504
 Pericæcal, 288
 Perineal, 398
 Perinephritic, 329
- Abscess—
 Perityphlitic, 288
 Popliteal space, 174
 Post-pharyngeal, 28
 Prostatic, 447
 Psoas, 501
 Retro-pharyngeal, 28
 Sacro-iliac, 169
 In scalp, 67
 Of spermatic cord, 396
 Submammary, 226
 Supra-mammary, 226
 In temporal fossa, 96
 Thecal, 151
- Abscission of cornea, 540
 Accelerator urinæ (see Muscles)
 Acromegaly, 95
 Acupuncture in sciatica, 162
 Addison's disease, 330
 Adductor longus muscle (see Muscles)
 Adhesions in hernial sac, 351
 Ægophony, 214
 Air in veins, 228
 Air tube (see Larynx and Trachea)
 Alderman's nerve, 127
 Alimentary canal, development of, 290
 Allantois, 268
 Allarton's operation of median litho-
 tomy, 418
 Amphoric breathing, 213
 Amussat's operation for artificial anus,
 296
 Anal canal, 482
 Triangle, 393
 Ulcer or fissure, 482
 Aneurism, popliteal, 175
 Aneurismal varix of splenic vein, 322
 Ankle joint, structures at, 191
 Synovial membranes of, 192
 Annular ligaments of—
 Ankle, 191
 Wrist, 150
 Anterior crural nerve, 164
 Paralysis of, 164
 Tibial nerve, 190
 Anti-cubital fossa, 142

- Antrum of Highmore, 116
 Diseases of, 117
 Dentigerous cysts in, 118
 Dropsy and cystic disease of, 118
 Polypus of, 118
 Suppuration of, 117
 Treatment, 118
 Tumours of, 117
 Anus, abscess near, 396
 Absence of, 291
 With opening of rectum into
 other canals, 292
 Artificial, formation of, 296
 By Amussat's operation, 296
 By Callisen's method, 296
 In cancer of rectum, 301
 In children, 303
 Cure of, 559
 By Littré's operation, 303
 Cancer of, 484
 Closure of, 291
 By septum, 291
 With absence of rectum, 292
 Congenital malformations, 291
 Fissure of, 482
 Treatment of, 483
 Fistula of, 394
 Imperforate, 291
 Prolapse of, 483
 Spasm of sphincter, 483
 Ulcer of, 482
 Aortic orifice, 203
 Aphasia, 203
 Aphonia, 19
 Apoplexy, 241
 Appendage dysmenorrhœa, 514
 Aqueduct of Fallopius, 119
 Arachnoid, the, 233
 Arcus senilis, 540
 Areola, inflammation and abscess of, 226
 Arnold's nerve, 127
 Arteriotomy, from temporal, 43
 Artificial anus (see Anus, artificial)
 Ascites, 336
 Ascitic fluid, 338
 Asthenopia, 541
 Atlas, disease of, 231
 Dislocation of, 244
 Attitude in hip disease, 165
 Auriculo-ventricular orifices, 203, 204
 Axilla, 136
 Abscess of, 138
 Fascia of, 142
 Relation of contents to walls, 138
 Axillary glands, 137
 Nerves, 137, 139
 Veins, 137, 139
 Axis, disease of, 231
 Dislocation of, 244
 Azygos veins, 221
 Baker's cysts, 175
 Base of skull, fractures of, 75
 Battey's operation, 512
 Bell sound, 214
 Belly-ache and spinal disease, 250
 Bend of elbow, 142
 Benign polypus, 113
 Bent arm, after venesection, 146
 Biceps muscle, 136
 Bichromate disease, 116
 Bigelow's operation of lithotrity, 426
 Bilateral dislocation of lower jaw, 39
 Bilateral lithotomy, 419
 Bile ducts, 315
 Bladder, 465
 Atony of, 435
 Cancer of, 470
 Cock's method of puncture, 468
 Conditions of, unfavourable to
 lithotrity, 427
 Congenital malformation of, 269
 Danger of, in lithotrity, 426
 Distance from surface, 404
 Distension of, with overflow, 436
 Extroversion of, 269
 Fasciculated, 469
 Hæmorrhage from, 470
 Irritable, 436
 In boys, 436
 Mucous membrane of, 469
 Papilloma of, 470
 Puncture above pubes, 465
 Through rectum, 465
 Objections to, 466
 Relations to peritonæum, 488
 Rupture of, 468
 Sacculi of, 469
 Sarcoma of, 470
 Sounding the, 409
 Errors in, 410
 Spence's puncture through the
 perineum, 467
 Stone in, 417
 Trigons of, 465
 Tumours of, 470
 Blind fistula in ano, 395
 Piles, 479
 Blood in hæmatocœl, 460
 In urine, 469
 Tests for, 470
 Vomiting of, in fracture of the
 skull, 77
 Blood-vessels of brain, 68
 Breast, 225
 Rectum, 477
 Scalp, 64
 Boys, impaction of calculus in urethra
 of, 435
 Lateral lithotomy in, 415
 Difficulties of, 417

- Brachial artery, in venesection, 146
 Plexus, 139
 Brain, the, 68
 Congenital hernia of membranes of, 83
 Blood-vessels of, 68
 Compression of, 89
 Concussion of, 89
 Contusion of, 561
 Cortex, lesion of, 560
 Emboli, 71
 Extravasation of blood in, 82
 Fissures of the, 78
 Inflammation of, 243
 Injuries of, by *coure coup*, 76
 Laceration of, 561
 Lobes of, 81
 Membranes of, 65
 Motor centres, 79
 Paralysis, from compression or injury, 89
 Protection of, 72
 Skull relations to, 78
 Sight centre, 81
 Substance, lesion of, 560
 Tumours of, 89
 Branchial clefts, 43
 Cysts, 45
 Fistulae, 44
 Breast, abscess of, 226
 Amputation of, 227
 Cancer of, 137
 Axillary glands affected in, 137
 Diagnosis of, 226
 Duct-cancer, 138
 In male, 317
 Operation for, 227
 Pain in, 226
 Breath sounds, 211
 Adventitious sounds, 212
 Bronchial, 212
 In disease, 212
 Vesicular, 211
 In disease, 211
 Bregma, 73
 Broca's convolution, 78
 Bronchi, foreign bodies in, 2
 Right and left, 2
 Bronchocele, 92
 Acute, 92, 94
 Cystic, 92
 Excision in, 93
 Fibrous, 92
 Ligature of thyroid arteries in (see vol. i.)
 Pulsating, 92
 Simple hypertrophy, 92
 Bronchophony, 213
 Bronchotomy, 214
 Reasons for, 215
 Bronchus, foreign bodies in, 2
 Bruit de Diable, 205
 Brunner's glands in burns, 285
 Bryant's method of dividing the muscles of the soft palate, 57
 Buccal cavity in foetus, 50
 Nerve, 121
 Bulb of urethra, arteries of—
 Wounded in lithotomy, 416
 Wound of, in lateral lithotomy, 418
 Median lithotomy, 418
 Bulbar paralysis, 129
 Bulbous urethra, 430
 Bunion, 194
 Watsou-Cheyne's operation for, 550
 Burns, ulcer of duodenum in, 285
 Bursa patellæ, diseases of, 178
 Inflammation of, 178
 Suppuration of, 178
 Tailor's, 550
 Bursæ, diseases of, 178
 About knee, 177
 Loose bodies in, 179
 In neck, 41
 Bursal tumour in floor of mouth, 47
 Cæcum, 285
 In intestinal obstruction, 287
 Cæcal hernia, 379, 391
 Caesarian section, 516
 Calculi, 472
 Chemical characters of, 472
 Calculus in bladder, 405
 Crushing of (see Lithotriety)
 Diagnosis of, 409
 Encysted, 469
 Extraction of—
 By lithotomy (see Lithotomy)
 By lithotriety (see Lithotriety)
 Facets on, 414
 In females, 428
 Removal of, 428
 Hardness of, 410, 472
 High operation, 422
 Impaction of, in urethra of boy, 435
 In kidney, 332
 Operations for (see Lithotomy and Lithotriety)
 Oxalate of lime, 472
 Pain produced by, 417
 Phosphatic, 472
 Shape and size of, 472
 Sounding for, 409
 Errors in, 409
 Structure of, 472
 Symptoms of, 417
 In urethra, 426, 435
 Uric acid and urates, 472
 Varieties of, 472

- Callisen's operation for artificial anus, 296
- Canal of Nuck, hernia in, 343, 379
- Cancer of anus, 484
 In axilla, 138
 Gullet, 24, 271
- Cancrum oris, 64
- Capillary pulse, 203
- Capsule, internal, 72
- Caput obstipum, 132
 Succedaneum, 67
- Carbuncle, facial, 63
- Cardiac areas, 203, 204
 Orifice of stomach, 269
- Cariou teeth, effects of, 61
- Carnochan's operation for neuralgia, 124
- Carotic body, 474
- Carotid tubercle, 4
- Carpus, articulations of, 556
- Cartilages of larynx, 14
 Loose, in knee joint (see vol. i.)
- Castration, 491
- Catheter—
 Bigelow's, 426
 Elbowed, 448
 To pass, in male, 431
 In female, 433
 Use in enlarged prostate, 447
 To tie in a silver, 441
 A soft, 441
- Catheter fever, 443
- Catheter life, 447
- Catheter, à coudée or bi-coudée, 448
- "Cat's eye," 542
- Cephalhæmatoma, 66
 In scalp, 66
 Subapourotic, 67
 Subpericranial, 67
- Cephalhydrocele, 75
- Cerebral abscess, 553
 Arteries, 68
 Irritation, 561
 Siuses, 554
- Cerebral hæmorrhage, 89
 Artery of, 69
 Localisation, 78
- Cerebro-spinal fluid, 72, 77
- Cervical auricles, 47
 Spine, disease of, 231, 244
 Dislocation of, 244
- Charbon, 64
- Chest, 198
 Special forms of, 209
 Barrel-shaped, 209
 Phthisical, 209
 Rickety, 209
 Relation of heart to wall of, 198
 Lungs and pleuræ to, 207
 Tapping the, 217
- Chiene's operation for knock-knee, 180
- Chimney-sweeper's cancer, 453
- Chloroform in hernia, 355
- Cholecystectomy, 320
- Cholecystenterostomy, 320
- Cholecystotomy, 318
- Chorda tympani nerve, 121
- Circle of Willis, 68
- Circocele, 461
- Circumcision, 496
- Claw-foot, hollow, 191
- Cleft palate, 48
 Operations for on hard palate, 57
 On soft palate, 56
- Cloquet's hernia, 389
- Club-foot, 184
- Club hand, 154
- Coccydynia, 249
- Coccygeal body, 474
- Coeliac axis, 260
- Coercion bursa, 161
- Colectomy, 309
- Colloid cancer of abdomen, 337
- Colon, 285
 Malformations of, 291
- Colotomy, 296
 Inguinal, 303
 Lumbar, 296
- Compression of brain, 89
 Of cord, 248
- Concussion of brain, 89
 Pathology of, 89
 Of spinal cord, 248
- Conditions protecting brain from injuries, 72
- Condyle, inner, of femur, 179
- Congenital defect of diaphragm, 392
 Dermoid cyst in floor of mouth, 47
- Exomphalos, 268
- Fistulæ, 43
- Hernia of cerebral membranes, 83
 Diaphragmatic, 392
 Inguinal, 340
- Hydrocele, 457
 Malformations of—
 Anus and rectum, 291
 Bladder, 268
- Phimosi, 496
 Sacro-coccygeal body, 474
- Congestive stricture, 433
- Constrictors of pharynx, 526
- Contracted knee, 176
- Contraction of fingers, 154
- Contre coup, fracture by, 76
 Injury of brain by, 76
- Convulsions of brain—
 Motor centres, 78, 81
 Relation of to skull, 78
- Cord, spermatic, 489

- Cord, spinal, 232
 Concussion, 248
 Injuries, symptoms of, 248
 Corona veneris, 67
 Coronal suture, 73
 Corpus spongiosum, danger of wounding
 in lithotomy, 417
 Striatum, 72
 Corsets, objections to, 316
 Costal cartilages, joints of, 255
 Costo-colic fold, 321
 Costo-coracoid membrane, 141
 Coxalgia (see Hip disease)
 Cranial sutures, 73
 Cranio-tabes, 75, 85
 Cremaster muscle, 490
 Cremasteric artery, 489
 Reflex, 490
 Cretinism, 94
 "Cricket thigh," 535
 Cricoid cartilage, 14
 Crico-thyroid space, 4, 5
 Crural arch, 381
 Canal, 382
 Crushing of spinal cord, 248
 Cryptorchismus, 343
 Curves of the vertebral column, 231
 Curvature of spine, angular, 251
 Cut throat, 22
 Dangers of, 23
 Suicidal, 23
 Cystic brouchocele, 92
 Hygromata, 45
 Sarcocele, 463
 Cystic tumours of antrum, 118
 Lips, 46
 Mouth, 46
 Neck, 45, 47
 Cystitis, 417
 Cystocele, 391
 Cystotomy, 448
 Supra-pubic, 449
 Cysts, dentigerous, 118
 Dermoid, 98
 Hydatid, 314
 Mucous, 46
 In neck, 45, 47
 In thyroid body, 92
 Dangerous area of scalp, 62, 65
 Dartos, 452
 Davies-Colley's treatment of club-
 foot, 187
 Deaf-mutism, 553
 Dental foramen, 31
 Dentigerous cysts, 118
 Dentition in rickets, 85
 Depressed fracture of skull, 74
 Diagnosis, 75
 Treatment, 87
 Dermoids, 98
 Dermoid cysts, 98
 In mouth, 47
 In scalp, 84
 On nose, 116
 Diaphragmatic hernia, 392
 Diphtheria, 4
 Diagnosis from tonsillitis, 34
 Diploic veins, 63
 Direct inguinal hernia, 341
 Dislocation of—
 Jaw, 38
 Spine, 244
 Distinguishing the large bowel from
 the small, 272
 Double hare-lip, 50
 Operation for, 53
 Dropsy of—
 Antrum, 118
 Cardiac, 202
 Hepatic, 202
 Ovarian, 336
 Renal, 202
 Duct-cancer of breast, 138
 Duodenum, 283
 Clinical points about, 284
 Rupture of, 284
 Ulcer of, in burns, 285, 270
 Duodenostomy, 278
 Dupuytren's—
 Contraction of fingers, 154
 Exostosis, 196
 Enterotome, 559
 Lithotome cachée, 419
 Dura mater, 65
 Dysphagia, 24, 274
 Causes of, 24, 274
 Elastic ligature in fistula, 396
 Elbow, bend of, 142
 Triangle at, 142
 Contents of, 142
 Venesection at, 143
 Dangers of, 146
 Veins of, 143
 Embolism in cerebral arteries, 71
 Emissary veins of skull, 62
 Empyema, 222
 Treatment of, Surgical, 223
 Encephalocele, 83
 Encysted hydrocele of—
 Cord, 457
 Testicle, 458
 Enemata in hernia, 354
 Enterectomy, 309
 Enterotomy, 308
 Enterocoele, 379
 Entero-epiplocele, 379
 Enterotome, Dupuytren's, 559
 Epididymis, 451

Epigastric artery, deep, 340, 386
 Pulsation, 200
 Epiplocele, 379
 Epispadias, 269
 Epistaxis, 110
 Treatment of, 111
 Erb's paralysis, 248
 Excision of breast, 227
 Bronchocele, 93
 Intestines, parts of, 309
 Larynx, 21
 Pylorus, 277
 Rectum, 486
 Tongue, 100
 Tonsils, 35
 Uterus, 514
 "Exercise bone," 532
 Exomphalos, 268, 390
 Exophthalmic goitre, 92
 Exostosis, ungual, 196
 Extensor brevis digitorum, 539
 Extensor of finger, rupture of, 155
 Extensors and supinators, paralysis
 of (see vol. i.)
 External inguinal hernia, 344
 Piles, 478
 Urethrotomy, 437
 Extirpation of kidney, 333
 Larynx, 21
 Spleen, 323
 Uterus, 514
 Extravasation of urine, 397
 Extroversion of bladder, 269
 Face, paralysis of, 122
 Facial carbuncle, 63
 Neuralgia, 124
 Paralysis, 122
 Fascia—
 Axillary, 142
 Bicipital, 143
 Cervical, 134
 Colles's, 397
 Iliac, 501
 Ilio-psoas, 501
 Lata, 170, 380
 Lumborum, 235
 Obturator, 487
 Parotid, 96
 Pelvic, 487
 Perineal, 397
 Prevertebral, 135
 Propria of—
 Femoral hernia, 382
 Inguinal hernia, 345
 Recto-vesical (pelvic), 487
 Scalp, of, 64
 Thigh, 170
 Transversalis, 500
 Fasciculation of bladder, 469

"Fatty hernia," 384
 Tumours in crural canal, 384
 Diagnosis from hernia, 384
 In scrotum, 457
 On spermatic cord, 457
 Females, calculus in, 428
 Lithotomy in, 428
 Lithotripsy, 428
 Femoral coxalgia, 165
 Hernia, 380
 Ligament, 381
 Femur, trigone of, 175
 Ferguson's method of dividing muscles
 of palate, 57
 Fever, urethral, 437
 Fibrous stricture of œsophagus, 24, 271
 Fifth nerve, on face, 29
 Auriculo-temporal nerve, 32
 To expose, 32
 Inferior dental, trunk of, 31
 To expose, 31
 Infra-orbital, 30
 Lingual nerve, 32
 To expose and divide, 33
 Hilton's plan, 33
 Lucas's plan, 33
 Moore's plan, 33
 Mental branch of inferior dental, 31
 Second division in sphenomaxillary
 fissure and fossa, 30
 Supra-orbital, 29
 To expose, 29
 Fingers, contraction of, 154
 Nerves of, 155
 Fissure of anus, 482
 Parieto-occipital, 81
 Of Rolando, 78
 Methods to find, 78
 Of Sylvius, 80
 Fistula in ano, 394, 482
 Complete, 395
 Incomplete or blind, 395
 Operation for, 394, 396
 Salivary, 28
 Umbilical, 268
 Fistula in neck, 43
 Flat foot, 188, 549
 Ogston's operation for, 549
 Fleishy piles, 479
 Flexor tendons, sheaths of, 149
 Fluctuation, 336
 Wave, 337
 Fluid in antrum, 118
 Fœtal remains, 253
 Fold, gluteal, in hip disease, 167
 Fontanelle, sagittal, œvus of, 84
 Foot—
 Articulations of, 557
 Deformities of, 184
 Drop, 177

- Foot—
 Nerves of, 194
 Perforating ulcer of, 194
 Splay, 188
 Synovial membranes of, 192
- Forameum of Magendie, 73
- Forceps, lithotomy, 406
 Manipulation of, 414
- Fore-arm, paralysis of muscles of, 148
- Foreign bodies in air passages, 2, 3
 In nostrils, 115
 Gullet, 3, 25
- Fossa duodeno-jejunalis, 284
- Fossa, ischio-rectal, 393
 Nasal, 107
- Four-tailed bandage, 40
- Fracture of jaw, lower, 39
 Nasal bones, 76, 110
 Ribs, 215
 Skull, 74
 Spine, 244
- Fracture-dislocation of the vertebral column, 244
- Frontal sinuses, diseases of, 113
- Galen, veins of, 554
- Gall bladder, 318
 Fundus of, 318
 Stones, 318, 320
- Ganglion in hand, 153
 Compound, 153
 Simple, 153
- Gangrene of gut in hernia, 350
- Gastric ulcer, 270
- Gastrocnemius muscle (see Muscles)
 Rupture of (see Muscles)
- Gastro-enterostomy, 270, 278, 284
- Gastrostomy, 271, 274
- Gastrotomy, 271
- Genito-crural nerve, 503
- Genu valgum, 179
 Operations for, 180, 181
 Three stages of, 180
- Girdle pain, 243, 246
- Glabella, 73
- Gland, mammary (see Breast)
 Parotid, 95
 Thyroid, 90
- Globular piles, 479
- Glottis, œdema of, 12
- Gluteal bursa, 161
- Gluteus maximus, structures under, 160
- Goitre (see Bronchocele)
 Exophthalmic, 92
- Gorget, 406
 Groin, glands in, 159
- Gullet (see Esophagus)
- Gum-elastic tube in lithotomy, 408
- Gustatory nerve, division of, 32
- Guthrie's muscle, 530
- Hæmatocele, 460
 Blood in, 460
 Diagnosis of, 460
 Spontaneous and traumatic, 460, 461
- Hæmatoma of scalp, 66
 On septum nasi, 116
- Hæmaturia, 469
- Hæmorrhage, from bladder, 470
 In excision of tongue, 99
 From kidneys, 470
 In lateral lithotomy, 420
 In median lithotomy, 418
 Nasal (see Epistaxis)
 From piles, 479
 From prostate, 469
 In tracheotomy, 6
 From tonsils, 35
 From urethra, 469
- Hæmorrhoids (see Piles)
- Hæmothorax, 216
- Hahn's tube, 99
- Hallux rigidus, 194, 549
 Valgus, 194
- Ham, bursa in, 177
- Hamstring tendons, division of, 176
- Hand, clubbed, 154
 Ganglion of, 153
 Middle line of, 157
 Palmar furrow, 157
 Synovial sheaths of, 149
- Hard palate, 50
- Hare-lip, 48
 Age for operations in, 51
 Double, 50
 Operations for, 51
 Single, 50
- Hare's angle, 551
- Head, diseases of, 84
 In rickets, 85
 In congenital syphilis, 85, 558
 Tapping the, 73
- Head injuries, loss of memory after, 561
- Headache and spinal disease, 250
- Heart, course of blood through, 201
 Development of, 206
 Dullness of, absolute, 200
 Deep, 199
 In dilatation, 200
 In hypertrophy, 200
 In pericarditis, 200
 Relative, 199
 Superficial, 200
 Effect of valve disease, 201
 Examination of, 204
 Hypertrophy of, 199
 Malformations of, 206, 207
 Murmurs of, 204
 Classification, 204
 Diagnosis, 204

- Heart, murmurs of—
 Endocardial, 205
 Exocardial, 205
 Percussion of, 200
 Relation of to surface, 198
 Size of, 200
 Sounds of, 201
 Accentuation, 201
 Reduplication, 201
 Valves of, position, 203
 Weight of, 200
- Hemiplegia, 203
- Hernia, 339
 Causes, 346
 Chloroform in reduction of, 355
 Conditions presented by, 339
 Congenital, 376
 Contents of, 339
 Coverings, 339
 Diaphragmatic, 392
 Direct, 341, 344
 Fatty, 266
 Femoral, 380
 Incarcerated, 340
 Infantile, 377
 Inflamed, 340
 Inguinal, 340
 Into funicular process, 378
 Internal, 284
 Irreducible, 339
 Lumbar, 392
 Mesenteric, 284
 Meso-colic, 284
 Oblique, 344
 Obstructed, 339
 Obturator, 390
 Omental, 351, 391
 Operation with opening sac, 348
 Division of stricture, 351
 Exposure of sac, 350
 Management of adhesions, 351
 Opening sac, 350
 Treatment of sac, 359
 Wounds of arteries, 386
 Operation without opening sac, 347
 Objections to, 348
 Radical cure of, 356
 Macewen's operation, 364
 Spanton's operation, 359
 Wood's operation, 357
 Reducible, 339
 Reduction—
En bissac, 352
En masse, 352
 Sac of, 339
 Signs of, 339
 Strangulated, 340
 Gangrene in, 350
 Mechanism of, 340
 Operation for, 347
- Hernia, strangulated—
 Reduction of, 354
 In mass, 352
 Persistence of symptoms
 after, 352
 Treatment of, 358
 Seat of stricture, 347
 Taxis in, 354
 Treatment of, 361
- Hernia, truss for, 355
 Measurements for, 356
- Hernia—Special forms of, 376
 Of bladder, 391
 Of cerebral membranes, 83
 Cæcal, 391
 Cloquet's, 389
 Diaphragmatic, 392
 Direct, 344
 Encysted, 378
 Femoral, 380
 Canal, 382
 Contents of, 379
 Diagnosis of, 384
 Fascia propria of, 382
 Opening sac in, 350
 Operation for, 384
 Relations of, 387
 Ring, 382
 Sheath, 381
 Taxis in, 382
 Treatment of, 384
- Hour-glass hernia, 379
- Inguinal, 340
 Congenital, 376
 Direct, 341
 Coverings of, 345
 Relations of, 344
 Encysted, 378
 External, 344
 Fascia propria of, 345
 Infantile, 377
 Oblique, 344
 Coverings of, 345
 Relations of, 344
 Operation for, 361
 Seat of stricture, 347
 Taxis in, 354
 Varieties of, 340
- Laugier's, 389
 Littre's, 389
 Lumbar, 392
 Mesenteric, 284
 Meso-colic, 284
 Obturator, 390
 Coverings of, 390
 Relations of, 390
 Of ovary, 343
 Scrotal, 344
 Of tunica vaginalis, 376
 Encysted, 378

- Hernia—
 Umbilical, 390
 Operation for, 391
 Ventral, 392
 Herniotomy, 347
 Herpes zoster, 242
 Hesselbach's triangle, 340
 Hey's ligament, 381
 High operation of lithotomy, 422
 Hilton, division of lingual nerve, 33
 Hip joint disease, 164
 Acetabular, 165
 Arthritic, 165
 Attitude in, 165
 Diagnosis of, 166
 Dislocation in, 167
 Femoral, 165
 Forms of, 165
 Pain in the knee in, 165
 Histrionic spasm, 123
 Hollow claw-foot, 191
 Holt's treatment of stricture, 437
 Housemaid's knee, 177
 Howse's incision in gastrotomy, 272
 Hydatids, 314
 In liver, 314
 Fluid in, 337
 Hydrancephalocele, 83
 Hydrocele, 453
 Acupuncture in, 460
 Acute, 454
 Discutient lotions in, 460
 Encysted, of the epididymis, 458
 Of cord, 457
 Treatment, 458
 Infantile, 457
 Of neck, 45, 475
 Of spermatic cord, 457
 Of tunica vaginalis, 453
 Congenital, 457
 Coverings of, 456
 Diagnosis of, 459
 From encysted hydrocele, 453
 From fatty tumour, 457
 Hernia, 456
 Fluid in, 454
 Injections in, 455
 Tapping in, 454
 Treatment of, 459
 Varieties of, 453
 Hydrocephalus, 73
 Tapping in, 73
 Hydromyelia, 255
 Hydronephrosis, 328
 Hydrophobia, 129
 Hydrops pericardii, 217
 Tapping in, 217
 Hydrorrachis, 255
 Hydrosarcocele, 457
 Hydrothorax, 216
 Tapping chest in, 217
 Hygroma, 45, 475
 Hypertrophy of—
 Prostate, 445
 Thyroid gland, 92
 Hypochondriac region, 261
 Hysterectomy, 510
 Hysterical stricture of the œsophagus, 24, 271
 Ileo-cæcal valve, 286
 Ileum, 284
 Iliac abscess, 504
 Fascia, 501
 Incision in imperforate anus, 293
 Imperforate anus, 291
 Rectum, 292
 Impermeable stricture, 440
 Operation for, 440
 Incarcerated hernia, 340
 Incontinence of urine, 436
 Indian rhino-plastic operation, 112
 Indirect hernia, 344
 Infantile hernia, 377
 Paralysis, 242
 Inferior dental nerve, dividing the, 31
 Maxilla, dislocations of, 38
 Fracture of the, 39
 Thyroid veins, 9
 Infra-orbital nerve, 30
 Inguinal canal, 341
 Colotomy, 303
 Hernia, 340
 Inion, 74
 In-knee, 179, 548
 Intercostal arteries, 528
 Nerves, 528
 Intermaxillary bones in hare-lip, 53
 Management of, 53
 Internal condyle of femur, 179
 Hernia, 284
 Jugular vein, 42
 Piles, 479
 Popliteal nerve, 179
 Urethrotomy, 443
 Intestinal obstruction, 285, 288
 Amussat's operation for, 286
 Callisen's operation for, 296
 Colotomy for, 296
 Littré's operation for, 303
 Intestine, adhesions of, in hernia, 351
 Management of, 351
 Congested, in hernia, 350
 Constricted, in hernia, 363
 Diverticulum from, 290
 Gangrenous, in hernia, 350
 Management of, 351
 Hernia of, 379
 Removal of portions, 309

- Intestine—
 Rupture of, 284
 Small, 282
- Intestines, 282
 Development of, 290
 Large, 285
 Malformation of, 291
 Small, 282
- Intra-cranial suppuration, 88, 553
 Intra-thoracic tumours, 218
 Intubation of larynx, 12
 Intussusception, 287
 Inversion of testicle, 453, 454
 Iodine in bronchocele, 93
 Injection of, in hydrocele, 455
- Irreducible hernia, 339
 Ischio-rectal abscess, 394
 Ischio-rectal fossa, 393
 Isthmus of thyroid, 4
 Division of, 94
- Jaundice, 315
- Jaw, lower—
 Dislocation of, 38
 Fractures of, 39
 Treatment of, 40
 Subluxation of, 41
 Treatment of, 548
- Jejunostomy, 278
 Ileo-cæcal valve, 286
- Jejunum, 284
- Joints, displaced cartilages in, 548
 Operation for—
 In lower jaw, 548
 In-knee, 548
- Jugular vein—
 External, venesection from, 41
 Internal, 42, 555
- Kidney, the, 324
 Affections of, simulating stone in bladder, 417
 Calculous pyelitis, 329
 Dissection to expose, 326
 Floating, 333
 Hæmorrhage from, 470
 Hilus of, 324
 Hydronephrosis, 328
 Movable, 333
 Operations on the, 331
 Pyonephrosis, 329
 Pelvis of, 325
 Relations of to—
 Colon, 327
 Duodenum, 327
 Surface, 325
 Rupture of the, 327
 Sarcoma of, 327
 Size, 324
 Stone in, 332
- Kidney—
 Surgical operations on the, 331
 Aspiration of, 331
 Exploration of, 331
 Nephrectomy, 333
 Abdominal, 334
 Lumbar, 333
 Nephro-lithotomy, 332
 Nephrorraphy, 333
 Nephrotomy, 331
 Tumours of, 326
 Vessels of, point of origin, 260
 Weight, 324
- Knee, arteries of, 177
 Bursæ about, 177
 Contracted tendons, 176
 Pains and sigmoid flexure, 165
- Knives, hernia, 348
 Lithotomy, 406
 Method of holding, 406
- Knock-knee, 179
 Chiene's operation for, 180
 Macewen's operation for, 181
 Ogston's operation for, 180
- Kocher's excision of the tongue, 103
 Results of excision of thyroid body, 94
- Koerberle's serré-nœud, 511, 521
- Lambda, 73
 Lambdoid suture, 73
 Laparo-elytotomy, 517
 Laparotomy, 307
 Laryngeal obstruction, 4
 Laryngotomy, 3, 11
 Laryngo-tracheotomy, 3
 Larynx, 14
 Arteries of, 17
 Cartilages of, 14
 Excision of the, 21
 Intubation of, 12
 Joints of, 17
 Movements of, 17
 Muscles of, 16
 Nerves of, 17
 Paralysis of, 18
 Seen with laryngoscope, 18
 Tumours of, 21
 Ulcerations of, 21
 Ventricle of, 15
- Lateral lithotomy (see Lithotomy)
- Lawn tennis arm, 533
 Leg, 538
 Sprain, 533
- Leg, lymphatics of, 196
- Lembert's suture, 310
- Levator ani—
 Relation to fistula in ano, 395
 Palati, 57
- Lighterman's bottom, 161

- Linea alba**, 266
 Semilunaris, 265
 Transversa, 263
Lingual nerve, division of, 32
Lips, congenital malformations of, 50
 Cysts of, 46
Lithectasy, 428
Lithic acid calculi, 472
Litholapaxy, 426
Lithotome cachée, 419
Lithotomy, 405
 Arteries that may be wounded, 420
 Gum-elastic tube in, 408
 Instruments for, 405
 Preparation of patient, 409
 Bilateral, 419
 Lateral, 405
 Accidents during, 416, 420
 After treatment in, 414
 In boys, 415
 Difficulties in, 415, 417
 Dangers, 416
 Difficulties, 416
 In entering the bladder,
 415
 Extraction of stone in, 414
 Hæmorrhage—
 After, 416
 During, 414, 420
 Incision, external in, 412
 In prostate, 413
 Parts divided in, 412, 413
 Parts that may be wounded,
 416, 420
 Peritonitis, after, 417
 Position of knife in, 413
 Of patient in, 411
 Sounding for stone, 409
 Wound of—
 Arteries, 416
 Bladder, 416
 Bulb, in, 417
 Rectum, 416
 Median, 418
 Compared with lateral, 418
 Difficulties of, 418
 Ease and simplicity of, 418
 Indications for, 419
 Operation, 418
 Wound of—
 Bulb in, 418
 Rectum in, 418
 Supra-pubic, 422
 Urethral, in female, 428
 Vaginal, 428
Lithotrite, 426
 Bigelow's, 426
 To pass the, 427
Lithotrity, 425
 Breaking stone in, 428
Lithotrity—
 Catheter for, 426
 Conditions influencing choice of,
 427
 Cystitis after, 426
 Dangers in, 426
 Impaction of fragments in urethra,
 426
 In children, 427
 Introduction of lithotrite, 427
 Operation of, 428
 Seizure of stone, 428
 Brodie's method, 428
 Civiale's method, 428
Litré's operation for intestinal obstruction, 303
Liver, 311
 Abscesses in, 314
 Bile ducts, 315
 Enlargements of, 314
 Hydatids of, 314
 Operations on, 318
 Relations of, 311
 To surface, 311
 Size, 311
 Tumours, 313
 Weight, 311
 Wound of, 312
Lordosis, in hip disease, 166
Lumbar incision for artificial anus, 296
 Fascia, 295
 Plexus of nerves, 503
 Region, hernia in, 392
Lungs, 208
 Relations of to surface, 208
 Roots of, 29
 Relations of, 219
 Wound of, 313
Lymphatics of abdomen, 500
 Of abdominal walls, 269
 Of arm, 146
 Of groin, 159
 Of head, 130
 Intestines, 293
 Mamma, 227
 Of neck, 131, 553
 Leg, 196
 Pelvis, 500
 Penis, 499
 Prostate, 446
 Rectum, 478
 Testicle, 453
 Thorax, 256
 Tongue, 107
Macewen's operation for hernia, 364
 For knock-knee, 181
 Osteotome, 182
Maclaren's operation for varicose veins, 527

- Magendie, foramen of, 72, 73
 Malignant nasal tumours, 114
 Pustule, 64
 Sarcocele, 463
 Stricture of—
 Oesophagus, 24, 271
 Rectum, 484
 Tumours of thyroid body, 92
 Malformations of gut, 290, 291
 Malposition of testis, 344
 Mamma, 225
 Clinical points, 226
 Excision of, 227
 Spence's test, 226
 Thomas's operation, 229
 Mammary abscess, 226
 Gland, 225
 Blood-vessels and nerves of, 225
 Lymphatics of, 227
 Marian operation, 418
 Mastoid abscess, 553
 Process, 552
 Meatuses of the nose, 108
 Meckel's diverticulum, 268, 291
 Ganglion, 124
 Median basilic vein, 143
 Why selected for venesection, 143
 Cephalic vein, 143
 Median lithotomy, 418
 Median nerve, 148
 Paralysis of, 148
 Mediastina, 218
 Abscess of, 220
 Tumours and swellings of, 220
 Signs of, 221
 Medio-bilateral lithotomy, 419
 Melon-seed bodies, 153
 Membranes of brain, 65
 Hernia of, 83
 Membranous urethra, 429
 Meningeal arteries, 68
 Meninges of the brain, 65
 Of spinal cord, 232
 Meningitis, 243
 Meningocele, 83
 Meningo-myelocele, 252
 Mesenteric arteries, 260
 Mesentery, 282
 Meso-cæcum, 285
 Meso-nephron, 333
 Micturition and spinal injuries, 245
 Middle ear, abscess of, 553
 Miner's elbow, 161
 Monro, foramen of, 73
 Moore's division of gustatory, 33
 Morbus coxæ, 165
 Morgagni, space of, 527
 Morphœa, 242
 Morton's treatment of spina bifida, 254
 Solution, 254
 Motor centres on cortex, 78
 Mouth, floor of, 102
 Development of, 48
 Mucous nasal polypi, 113
 Müller's ablation, 522
 Muscles of mastication, 38
 Origin and insertion of, 523
 Peroneal, 189
 Spine, upper part of, 230
 Tibials, 186
 Musculo-cutaneous nerve, 190
 Musculo-spiral nerve, 147
 Myelitis, spinal, 242
 Myelocele, 252
 Myomotomy, 522
 Myxœdema, 94
 Nævus of fontanelle, 84
 Scalp, 84
 Nares, anterior, 108
 Posterior, 108
 Nasal bones, fracture of, 110
 Cavity, 108
 Floor, 107
 Fossæ, 107
 Mucous membrane, 108
 Nerve and connections, 108, 109
 Polypi, 113
 Septum, 107
 Tumours of, 113
 Naso-pharyngeal tumours, 114
 Removal of, 114
 Neck, congenital cysts of, 475
 Congenital fistulæ, 43
 Fascia of, 134
 Hydrocele of, 41
 Lymphatic glands of, 131, 553
 Middle line of, 4
 Nélaton's operation for—
 Hare-lip, 51
 Obstruction of gut, 308
 Nephrectomy, 333
 Nephro-lithotomy, 332
 Nephroraphy, 333
 Nephrotomy, 331
 Nerve stretching, 123, 162
 Nerves—
 Cranial, 119
 Facial, 119
 Fifth section of, 124
 Glosso-pharyngeal, 127
 Gustatory section of, 32
 Hypoglossal, 129
 Intercostal, 528
 Pneumogastric, 127
 Recurrent laryngeal, pressure on,
 220
 Spinal accessory, 128
 Nerves of spinal cord, points of exit, 247
 Nervous affections of larynx, 18

- Neuralgia, facial, 33
 Section of nerves in, 29
 Stretching affected nerve, 29
- Nose—
 Abscess of, 116
 Bleeding from, 110
 Fœtid discharge from, 115
 Foreign bodies in, 115
 Nerves of, 109
 Plastic Surgery of, 112
 Polypi of, 113
 Regions of, 108
 Restoration of, 112
 Septum, deviation of, 108
 Tumours of, 116
 Walls of, 107
- Nuck, canal of, 343, 379
- Oblique inguinal hernia, 344
 Obstetrical paralysis, 248
 Obturator artery, 386
 Hernia, 390
 Nerve, 164
- Occipital nerve, great, 230
 Occipito-frontalis, suppuration under, 67
 Œdema of glottis, 12
 Œsophageal bougie, to pass, 25
 Œsophagotomy, 25
 Œsophagostomy, 25
 Œsophagus—
 Dysphagia from pressure on, 271,
 274
 Lymphatics of, 25
 Relations of, 23
 In neck, 23
 In thorax, 24
 Stricture of, 24, 271
 Cancerous, 24, 271
 Drunkard's, 25, 271
 Fibrous, 24, 271
 Gastrostomy for, 25
 Hysterical or spasmodic, 24,
 271
- Ogston's operation for—
 Knock-knee, 180
 Flat-foot, 549
- Olecranon, enlargement of bursa over,
 161
- Omentum in hernia, 351
 Omohyoid muscle, 524
 Uses of, 524
- Omphalocele, 390
 Oöphorectomy, 512
 Ophthalmoplegia, 546
 Optic neuritis, 89
 Orbit, hæmorrhage into, 76
 Orchitis, syphilitic, 463, 464
 Organic stricture of œsophagus, 24, 271
 Of urethra, 433, 442
- Otic ganglion, 126
- Ovarian dropsy, 336
 Fluid in, 337
 Pain, 491
- Ovarian tumours, 509
 Diagnosis, 336
 Excision of, 506
 Treatment of, 506
- Ovaries, hernia of, 343
 Removal of, 512
- Ovariectomy, 506
 Mode of performing, 507
 After treatment, 508
 Preparation of patient, 506
- Ovary, the, 509
- Overflow of urinc, 436, 445
- Ox-eye, 541
- Ozæna, 115
 Simple, 115
 Strumous, 115
 Syphilitic, 115
- Pain in calculus, 417
 In hip joint disease, 165
 In sacro-iliac disease, 165
- Palate, dermoids of, 58
 Development of, 50
 Hard, fissures of, 50
 In idiots, 57
 Plastic Surgery of, 56
 Soft, 57
 In syphilis, 57
- Pampiniform plexus, 489, 461
- Pancreas, 279
 Atrophy of, and diabetes, 282
 Cancer of, 280
 Cysts of, 281
 Relations of, 279
- Papillomata of bladder, 470
 Kidney, 328
 Larynx, 21
- Paracentesis (see Tapping)
- Paralysis of—
 Anterior crural, 164
 External popliteal, 190
 Facial, 122
 Great sciatic, 164
 Internal popliteal, 179
 Median, 148
 Obturator, 164
- Parametritis, 489
- Paraphimosis, 497
 Treatment of, 497
- Paraplegia dolorosa, 243
 Paraplegia from spinal disease, 251
- Parieto-occipital fissure, 81
- Paronychia, 153
- Parotid abscess, 96
 Duct, wound of, 28
 Excision of, 97
 Fascia, 96

- Parotid gland—
 Diseases of, 96
 Structures in, 96
 Inflammation of, 97
 Region, 95
 Tumours of, 96
 Parotitis, 97
 Parovarian fluid, 337
 Parrot's nodes, 85
 Patella, disease of bursa, 178
 Pectoriloquy, 213
 Whispering, 213
 Pedicle of uterine fibroids, 510
 Pelvic blood-vessels, 491
 Fascia, 487
 Peritoneum, in female, 488
 In male, 488
 Pelvis, diffuse cellulitis, 417, 489
 Floor of, 488
 Kidney, of, 325
 Penile urethra, 480
 Penis, the, 493
 Amputation of, 497
 Nerves of, 495
 Structure of, 433, 442
 Wound of dorsal artery, 420
 Of vein, 444
 Perforating ulcer, 194, 253
 Pericardium, tapping the, 217
 Pericranium, 65
 Attachments of, 65
 Blood under, 66
 Pus under, 67
 Perimetritis, 489
 Perineal abscess, 398
 Cystotomy, 448
 Fascia, 397
 Fistula, 437, 442
 Incision in imperforate anus, 293
 Section for stricture, 437, 440
 Vessels and nerves, 403
 Perinephritic abscess, 329
 Perineum—
 Depth of, 404
 Dissection of, 393
 Divisions of, 393
 In female, 393, 402
 Nerves of, 403
 Operation for rupture, 53
 Perityphlitis, 288
 Abscess after, 288
 Varieties of, 288
 Peritoneum in descent of testicle, 342
 In misplaced testicle, 344, 453
 Wound in lumbar colotomy, 301
 Peroneal nerve, 190
 Pes cavus, 191
 Petit's triangle, 296, 392
 Phantom tumour, 263
 Pharyngotomy, 26
 Pharynx, 27
 Abscess behind, 28
 At side, 27
 Aneurism pressing on, 27
 Foreign bodies in, 28
 Openings into, 27
 Relations of, 27
 Scalds of, 3
 Phimosis, 495
 Acquired, 496
 Congenital, 496
 Circumcision for, 496
 Dilatation in, 496
 Slitting prepuce for, 496
 Phosphatic calculi, 472
 Phthisis with fistula in ano, 394
 Pigeon breast, 209
 Piles—
 Blind, 479
 Bleeding, 479
 Causes of, 478
 Cautery, 480
 Crushing, 480
 Excision, 480
 External, 478
 Fit of, 479
 Injection of, 481
 Internal, 479
 Ligature of, 480
 Treatment of, 479
 External, 479
 Internal, 480
 Plastic Surgery of lips, 51
 Nose, 112
 Palate, 56
 Platysma myoides, 523
 Uses of, 523
 Pleura, air in, 216
 Blood in, 216
 Relation to surface, 207
 Tapping the, 217
 Plugging nostrils, 111
 Pneumonia, suppurative, 105
 Pollock's method of dividing muscles
 of soft palate, 57
 Polypus of antrum, 118
 In frontal sinuses, 113
 Nasal, 113
 Fibrous, 114
 Malignant, 114
 Mucous, 113
 Pharyngeal, 114
 Pope or poop, taking the, 555
 Popliteal bursa, 178
 Nerve, external, 190
 Internal, 179
 Space, 175
 Post-pharyngeal abscess, 28
 Pott's disease of spine, 251
 Puffy tumour, 88

- Poupart's ligament, 158
 Strictures under, 158
- Prepuce, the, 494
 Circumcision of, 496
 Slitting up for phimosis, 496
- Prolapse of rectum, 483
- Prostate, the, 444
- Prostate gland, abscess of, 447
 Cancer of, 435
 Dilatation of, in lithotomy, 418
 Enlargement of, 445
 Inflammation of, 447
 Lymphatics of, 446
 Nerves of, 446
 Mechanical effects, 445
 Retention of urine from, 445, 447
 Symptoms of, 445
 Treatment of, 447
 Structure of, 446
- Prostatectomy, 448
- Prostatic plexus of veins, 444
- Psoas abscess, 501
 Muscle, 530
- Pterion, 73
- Ptosis, operation for, 66
- Pudic artery, 420
- Pulmonary cavities, tapping, 214
- Pulsating bronchocele, 92
- Pulse, capillary, 203
 Venous, 202
- Puncture of bladder, 465
 Above pubes, 465
 Through perineum, 467
 Per rectum, 465
- Punctured fracture of skull, 74
- Pus in urine, 471
 Tests for, 472
- Pyelitis, calculous, 329
- Pyelo-nephritis, 329
- Pylorus, 275
 Excision of, 277
 Loreta's operation, 276
 Stricture, 275
- Pyonephrosis, 329
- Pyuria, 471
- Radical cure of hernia, 355
 Of varicocele, 462
- Railway spine, 249
- Râles, dry, 213
 Moist, 212
- Ranula, 45, 46
 Varieties, 46
- Reaction of degeneration, 239
- Rectangular staff, 405, 406
- Rectum, 476
 Abscesses near, 396
 Absence of, 292
 Arrangement of vessels of, 477
- Rectum—
 Ballooned rectum, 484
 Cancer of, 484
 Excision of, 486
 Finger in, what felt, 485
 Fistulous openings into, 395
 Malformations of, 291
 Nerves of, 478
 Occlusion of, by septum, 292
 Opening into other canals, 292
 Polypi of, 485
 Prolapse of, 483
 Puncture of bladder through, 465
 Relations of, 477
 Sphincters of, 482
 Diseases near, 482
 Stricture of its three parts, 481
 Vessels of, 477
 Wound of, in lithotomy, 416, 418
- Rectus abdominis muscle, 263
 Sheath of, 264
 Contents of, 265
- Reducible hernia, 339
- Reflex act, 239
- Reflexes, abdominal, 249
 Aukle, 250
 Cremasteric, 249
 Epigastric, 249
 Gluteal, 249
 Knee, 249
 Plantar, 250
- Regnoli's excision of tongue, 102
- Resection of small gut, 309
- Respiration, frequency of, 210
 Rhythm of, 210
- Respiratory movement, types of, 211
- Retention of urine (see Urine)
- Rhinoplastic operations, 112
- Ribs, to count, 206
 Fracture of, 215
 Complications of, 216
- Rickets, head in, 75
 Symptoms of, 269
- Rider's bone, 536
 Sprain, 536
- Rigidity, 241
 Early, 241
 Late, 241
- Rima glottidis, 16
 State of in breathing and singing, 16
- Rolando, fissure of, 78
 How to find, 78, 80
- Rougé's operation, 115
- Round ligaments of uterus—
 Shortening of, 519
- Sac of hernia, 339
 Changes of fluid in, 350
 Opening the, 348, 350
 Treatment of, 359

- Sacculated bladder, 469
 Sacro-iliac joint, 169
 Disease of, 169
 Diagnosis, 169
 Symptoms of, 169
 Sagittal fontanelle, 73
 Suture, 73
 Salivary calculi, 46
 Fistula, 28, 558
 Sanger's operation, 522
 Saphena vein, varix of, 172, 173
 Long, 172
 Short, 176
 Saphenous opening, 380
 Sarcocoele, 463
 Cystic, 463
 Malignant, 463
 Simple, 463
 Syphilitic, 463
 Table contrasting, 464
 Tubercular, 463
 Sarcoma of antrum, 117
 Of nose, 115
 Of parotid gland, 97
 Saw, Hey's, 86
 Scalp, the, 62, 64
 Diseases of, 84
 " Dangerous area," of, 62, 65
 Dermoide cysts of, 84, 85
 Fatty tumour of, 84
 Injuries of, 62
 Nævus of, 84
 Veins of, 63
 Wounds of, 62
 Dangers of, 62
 Scalpels in lithotomy, 406
 Scarpa's triangle, 159
 Glands of, 159
 Swellings in, 160
 Schneiderian membrane—
 Thickening of, 113
 Diagnosis of, 113
 Sciatic nerve, great, 161
 Course of, 161
 Stretching the, 162
 Scoop lithotomy, 414
 Scrofulus testicle, 464
 Scrotal hernia, 340
 Tumours, 459
 Scrotum, cancer of, 453
 Sédillot, excision of tongue, 104
 Gastrostomy, 272
 Seminal tubes, 451
 Septic broncho-pneumonia, 101
 Septum crurale, 382
 Of nose, abscess of, 116
 Lateral deviation of, 108
 Serpiginous ulcer of cornea, 544
 Serratus magnus, 531
 Paralysis of, 531
 Sheaths of flexor tendons, 149
 Shoulder-tip, pain and liver trouble, 317
 Sigmoid flexure, 286
 Sinus, frontal, disease of, 113
 Skull, fractures of, 74
 Of base, 75
 By contre coup, 76
 Contusion of, 75
 Depressed, 74
 Fissured, 74
 Hæmorrhage in, 76
 Necrosis of, 67
 Punctured, 74
 Signs of, 76
 Simple, 74
 Sinuses of, 75, 554
 Sutures of, 73
 Trephining the, 86
 Vault, 74
 Vomiting of blood in, 76
 Watery fluid discharged in, 77
 Sounding for stone, 409
 Southey's drainage trocar, 335
 Spanton's operation for hernia, 359
 Spasmodic stricture of œsophagus, 24,
 271
 Of urethra, 433
 Spermatic artery, 489
 Cord, 489
 Division of, in castration, 492
 Hydrocele of, 457
 Relation of, to hernia, 344
 Varix of, 461
 Spermatocele, 459
 Fluid in, 459
 Spermatozoa in fluid of encysted hydro-
 cele, 458
 Spina bifida, 184, 251
 Occulta, 253
 Treatment of, 254
 Varieties of, 252
 Spinal accessory nerve, 128, 554
 Spinal cord, 232
 Centres in cervical enlargement, 247
 Concussion of, 248
 Conduction in, 236
 Coverings of, 232
 Exit of spinal nerves, 247
 Grey matter, functions of, 238
 Injuries of vertebral column, 244,
 248
 In railway collisions, 249
 Length of, 233
 Lesions of, 236
 Meningocele, 252
 Motor path, 235
 Strands, 234
 Protection of the, 244
 Sensory path, 236
 Strands, 234

- Spine, the, 230
 Caries of, 251
 Concussion of, 248
 Curves of the, 231
 Dislocation of, 244
 Fractures of, 244
 Signs and symptoms of, 245
 Injuries and defæcation, 245
 And micturition, 245
 And respiration, 244, 248
 Pott's disease of, 251
 Trephining the, 250
- Spitting of blood, 203
- Splay foot, 188, 549
- Spleen, 321
 Extirpation of, 323
 Percussion of, 322
 Relations of, 321
 Rupture of, 323
 Size, 321
 Tumours of, 322
 Weight, 321
- Splenic vein, aneurismal varix of, 322
- Spontaneous hæmatocele, 461
- Stab of chest behind, 312
- Staff for lithotomy, 405
 Chiene's, 406
 Rectangular, 406
- Staphyloraphy, 56
- Stenson's duct, 28
- Sterno-mastoid muscle—
 Dividing the, 133
 Relation of to tumours, 523
- Sternum, holes in, 255
- Stiff big toe, 195, 549
- Stomach, 269
 Arteries of, 270
 Dilatation of, 276
 Proximity, to heart, 270
 Relations, to abdominal wall, 269
 Relations of, 270
 Stricture of, 271
- Stone in bladder, 417
 In kidney, 328
- Strangulated hernia, 340, 347
- Stricture in hernia, 347
 Of œsophagus, 24, 271
 Of rectum, 484
 Of urethra, 433
- Stye, 547
- Subarachnoid space, 65
- Subdural space, 65
- Sublingual bursa, 47
- Submammary abscess, 226
- Submastoid potato tumour, 524
- Submental excision of tongue, 102
- Suboccipital triangle, 230
 Nerve, 230
- Sulcus of Rolando—
 Rules to find, 78
- Suppuration—
 In antrum, 117
 In axilla, 138
 Of breast, 226
 Of bursa patellæ, 178
 In hip joint disease, 168
 Of kidney, 329
 In sacro-iliac disease, 169
- Supra-mammary abscess, 226
- Supra-pubic cystotomy, 449
 Lithotomy, 422
 Indications for, 422
- Supra-renal—
 Capsules, 330
 Nerves, 330
 Size, 330
 Weight, 330
- Surgical kidney, 329
- Sutures of—
 Apposition, 229
 Button, 229
 Hare-lip, 56
 Lembert's, 311
 Support, 229
- Sylvian fissure, 80
- Syme's operation for stricture, 437
 Staff, 439
- Synovial cysts, 175
 Membranes of foot, 192
 Of hand, 147
- Syphilitic orchitis, 463, 464
 Ozæna, 115
 Sarcocœle, 463
- Syringo-myelia, 255
- Syringo-myelocœle, 252
- Tabes mesenterica, 294
- Table of spines of vertebræ, 256
 Of landmarks in front, 257
- Tagliacotian operation, 112
- Tait, Lawson, cholecystotomy, 318
 Removal of uterine appendages, 513
- Talipes, 184
 Calcaneo-valgus, 188
 Calcaneus, 189
 Cavus, 191
 Equino-varus, 184
 Equinus, 187
 Valgus, 188
 Valgus, spurious (T. planus),
 188, 549
 Varus, 184
- Tapping the—
 Abdomen, 335
 Antrum, 118
 Chest, 217
 Head, 73
 Hydrocœle, 454
 Pericardium, 217
 Pleura, 217

- Tarsus—
 Articulations of, 557
 Synovial membranes of, 192
- Taxis—
 In femoral hernia, 382
 In inguinal, 354
- Teeth, 59
 Extraction of, 61
 Overcrowding of, 60
 Syphilitic, 60
 Strumous, 60
- Temporal abscess, 96
 Artery, arteriotomy from, 43
 Fascia, 96
- Temporo-maxillary articulation, 37
 Dislocations at, 38
 Movements at, 38
 Sphenoidal lobe, 81
- Tendo-achillis, division of, 187
 Bursa beneath, 187
- Tendons, disease of sheaths, 149
 Hamstring, contraction of, 176
- Teno-synovitis, 151
- Tenotomy and the peroneal nerve, 177
 Of hamstrings, 176
 Of sterno-mastoid, 133
- Teratoma, 253
- Testis, 450
 Cancer of, 453
 Chimney-sweep's cancer of, 453
 Coverings, 450, 452
 Cystic disease of, 452, 463
 Descent of, 342
 Development of, 451
 Enchondroma of, 463
 Gummata in, 463
 Inflammation of, 463
 Acute, 454
 Chronic, 463
 In inguinal canal, 344
 In foetus, 342
 Inversion of, 453, 454
 Malposition of, 344
 Nerves of, 453
 Relation to inguinal hernia, 344
 Removal of, 491
 Sarcoma of, 463
 Scrofulous, 464
 Seminal tubes, 451
 Solid enlargements of, 463
 Syphilitic disease of, 463
 Tubercular, 463
 Tumours of, 463
 Undescended, 343
- Tetanus, 129
- Thecal abscess, 151
- Thigh, fascia of, 170
- Thoracic viscera, 198
- Thorax, 198
- Thoracoplasty, 224
- Throat, cut, 22
- Thymus, 9, 10
- Thyroid, the, 90
- Thyroid gland—
 Diseases of (see Bronchocele).
 Division of isthmus, 94
 Duct of, 90
 Malignant tumours, 92
 In tracheotomy, 7
 Cartilage, 14
- Thyroidea ima artery, 91
- Thyrotomy, 3
- Tillaux, triangle of, 272
- Toe—
 Hammer, 195
 Stiff big, 195
 Webbed, 196
- Toes, nerves of, 194
- Tongue, 99
 Cancer of, 106
 Division of lingual nerve for, 32
 Ligature of lingual artery in, 103
 Mucous cyst of, 46
 Nerves of, 107
 Operations on, 99
 Removal of, 99
 By excision, 100
 Hæmorrhage during, 99
 After treatment, 101
 By Kocher's operation, 103
 By Regnoli's method, 102
 By Sédillot's or Syme's method, 104
 Structures divided, 101
 By Whitehead's method, 100, 102
- Tonsils, 34
 Abscess of, 37
 Arteries of, 35
 Bleeding from, 35
 Hypertrophy of, 35
 Lymphatics of, 35
 Nerves of, 35
 Removal of, 35
 Tonsillitis and diphtheria, 34
- Torticollis, 132
 Division of spinal accessory nerve for, 133
 Of sterno-mastoid, 133
- Trachea—
 Foreign bodies in, 2
 Opening in—
 Temporary, 3
 Permanent, 3
 Operations on, 3
 Relations of, 1
 In neck, 2
 In thorax, 2
 Variations in length, 1

- Trachea "tampon," 99
 Tubes, 7
- Tracheal obstruction, 4
- Tracheotomy, 3
 After treatment, 8
 In children, 10
 Difficulties and accidents, 9
 Hæmorrhage in, 9
 High operation, 3, 6, 7
 Indications for, 11
 Low operation, 3, 6, 9
 Operation of, 4
- Trepanning, 86
- Trephining the skull, 86
 Ramus of jaw, 31
 Spine, 250
- Trendelenburg's trachea "tampon," 99
- Triangular ligament of the urethra, 397
- Trigone, 466
- Trophic systems, 240
 Divisions of, 240
- Trusses, 355
- Tubercle of prostate, 447
- Tubercular kidney, 329
 Sarcocoele, 464
 Testicle, 463
- Tumours of—
 Antrum, 117
 Brain, 89
 Crura cerebri, 90
 Larynx, 21
 Naso-pharyngeal, 114
 Neck, 96
 Nose, 113, 116
 Ovaries, 509
 Pons, 90
 Scrotum, fatty, 457
 Spine, 243
 Testis, 463
 Thyroid body, 92
- Tunica albuginea, 450
 Vaginalis—
 Hæmatocele of, 460
 Hernia in, 456
 Hydrocele of, 453
- Tympanic cavity, size of, 557
- Ulcer of anus, 482
 Of duodenum, after burns, 285
 Of foot, perforating, 194, 253
- Ulnar nerve, 148
- Umbilical cord, 267
 Fistula, 268
 Hernia, 268
- Umbilicus, 267
- Urachus, 268
- Uranoplasty, 57
- Urate of ammonium calculus, 472
- Uretero-vaginal fistula, 328
- Ureters, 325
 Double, 325
- Urethra, 429
 Bulb of, wounded, 416, 418
 Calculus in, 435
 Curves of, 431
 Dilatation of, for calculus—
 In female, 428
 In treating stricture, 436
 Examination of, in stricture, 436
 False passages in, 432
 Hæmorrhage from, 444, 469
 Inflammation of, 417
 Laceration of, 432
 Length of, 429
 Membranous, 429
 Narrowest parts of, 430
 Opening the—
 In retention, 467
 In stricture, 437
- Penile, 430
- Prostatic, 429
- Rectum, opening into, 292
- Rupture of the, 397
- Shape of, 430
- Size of, 430
- Stricture of, 433
 Catheterism in, 436
 Accidents attending, 433
 Anæsthetics in, 434
 Congestive, 433
 Treatment of, 433
 Detection of, 436
 Diagnosis, from enlarged prostate, 446
 Dilatation of, continuous, 442
 Examination of the patient for, 436
 Extravasation of urine in, 397
 After gonorrhœa, 433
 Forms of, 433
 Impedes lithotripsy, 427
 Impermeable, 440
 Mechanical results of, 328
 Muscular, 433
 Operations for, 437
 Organic, 434
 Retention of urine from, 435
 Resilient, 437
 Seat of, 434
 Spasmodic, 433
 Treatment of, 433
 Syme's operation for, 437
 Symptoms of, 435
 Treatment of organic, 436, 442
 By dilatation, 436
 Division, 437, 443
 Forceful expansion, 437
- Urethral fever, 437
 Triangle, 397

- Urethrotomy—
 Median incision, 439
 In impermeable stricture, 440
 For permeable stricture, 437
 Combined internal and external, 443
 External, 437
 Internal, 443, 444
 For urinary fistula, 437
 Uric acid calculi, 472
 Urinary calculus, 472
 Fever, 443
 Urine, blood in, 469
 In calculus, 470
 Extravasation of, 397
 Treatment of, 398, 401
 Incontinence of, 436
 Overflow of, 445
 Retention of, 435, 436
 From enlarged prostate, 435, 436
 Aspiration in, 467
 Puncture above pubes in, 465
 Through rectum, 465
 Urethrotomy in, 437
 Uterine appendages, removal of, 513
 Fibroids, 509
 Natural terminations, 510
 Uterus, broad ligament of structures in, 489
 Excision of whole, 514

 Vagina, fistula into, 328
 Varicocele, 461
 Diagnosis of, 461
 Radical cure of, 462
 Varicose veins, 173
 Varix, aneurismal, 322
 Vas deferens, 490
 Rupture of, 490
 Vastus internus, 536
 Venesection on the arm, 143
 On neck, 41
 Veins of Galen, 554
 Veius, hæmorrhage from during lithotomy, 414
 Rectum, arrangement of, 478
 Spermatic varix of, 641
 Venous pulse, 202
 Ventral hernia, 392
 Vermiform appendix, 286
 Excision of, 289
 Vertebral canal, tumours in, 243

 Vertebral column, 231
 Curves of, 231
 Movements of, 232
 Vitello-intestinal duct, 268
 Vocal cords, 15
 False, 15
 Length of, 16
 True, 15
 Vocal fremitus, 211
 Resonance, 213
 Volvulus of sigmoid flexure, 287
 Vomiting of blood in fractured skull, 76, 77

 Washerwoman's sprain, 535
 Wrist, 535
 Watson Cheyne's operation for bunion, 550
 Watson, excision of thyroid, 93
 Weaver's bottom, 161
 Wens, 84
 Wharton's duct, relation to ranula, 46
 White line, in pelvic fascia, 488
 Wheelhouse's operation in urethra, 440
 Whitehead's excision of tongue, 100
 Operation for piles, 480
 Whitlow, 151
 Treatment of, 152
 Wilde's incision, 552
 Line, 552
 Wilson's muscle, 530
 Wölfler's operation, 270
 Womb-stones, 510
 Wood's operation for hernia, 357
 Wool-sorter's disease, 221
 Word-blindness, 560
 Word-deafness, 560
 Wound—
 Of bladder in lithotomy, 417
 Bulb of urethra in lithotomy, 417
 Diaphragm, 312
 Intestine in hernia operation, 350
 Lungs, 313
 Rectum in lithotomy, 416
 Wrist—
 Synovial membranes of, 147
 Anterior annular ligament, 150
 Posterior annular ligament, 150
 Wry-neck, 132

 X-knee, 179

 Yellow gum, 547


CATALOGUE
OF
E. & S. LIVINGSTONES'
MEDICAL
PUBLICATIONS.




15 Teviot Place,
EDINBURGH.

March 1900.

PRINTED BY
E. & S. LIVINGSTONE
MELBOURNE PRESS
EDINBURGH.

To Authors. 

PUBLICATION
OF
Medical and Scientific Works,
BY
E. & S. LIVINGSTONE.



THE SUBSCRIBERS are prepared to undertake the Publication of MEDICAL and SCIENTIFIC WORKS on terms advantageous to Authors.

The rapid sale of Works hitherto placed in their hands enables them to guarantee a favourable reception in the Profession, and by the Trade at home and abroad.

The Printing of their Publications is carried on within their own premises, thereby saving unnecessary expense, and receiving more careful attention.

Applications for ESTIMATES should be addressed to—

E. & S. LIVINGSTONE,
Medical and Scientific Publishers,
EDINBURGH.

Price £2 : 2s. Super-Royal Folio, Cloth.

A MAGNIFICENT WORK.

Makes a Handsome Present to a Senior Medical
Student or Practitioner.

THE
Topographical Anatomy
of the Child.

BY

JOHNSON SYMINGTON, M.D.,

F. R. S. E., F. R. C. S. E.,

*Professor of Anatomy, Queen's College, Belfast; formerly Lecturer on Anatomy,
School of Medicine, and Examiner in Anatomy, University of Edinburgh.*

ILLUSTRATED BY

FOURTEEN BEAUTIFUL AND CORRECTLY COLOURED PLATES (NEARLY ALL
OF WHICH ARE LIFE SIZE) AND THIRTY-THREE WOODCUTS.

THE TOPOGRAPHICAL ANATOMY OF THE CHILD.

OPINIONS OF THE PRESS.

This magnificent work forms one of the most important and most valuable of the recent contributions to human anatomy. Topographical Anatomy is usually considered independently of the age and sex of the subject, and there can be no question that many of its data require reconsideration.

The present work is founded upon the examination of a series of frozen sections of the bodies of children. It is illustrated by fourteen life-sized coloured Plates, and by a number of Woodcuts. Of the excellence and fidelity of the Plates it is impossible to speak too highly. They reflect the greatest credit upon the publishers.

The vertical medial sections and some coronal sections of the thorax are the most valuable. Sections are given of all parts of the trunk; of the skull, to show the orbits and nasal fossæ; of the neck, to show the position of the larynx; of the thorax, abdomen, and pæwia.

The First Part of the work is devoted to a critical explanation of the Plates. The Second Part deals systematically with the more conspicuous results of the author's investigations. The topographical anatomy of the auditory meatus and tympanum, the condition of the spinal curve in children, the topography of the brain, and the relational anatomy of the male and female genital organs, are all dealt with in an able and original manner.

Dr Symington's book abounds in original material. It is a work that no anatomist can afford to overlook. It adds materially to our knowledge of the most practical branch of anatomy, and is a credit to modern scientific research. —*The International Journal of the Medical Sciences*, (October 1887.

Dr Johnson Symington has well filled a gap in our Topographical Anatomy. This department of anatomical science has been worked at most extensively and ably by Pirogoff, Braune, Luschka, and others, in the adult; but the method of frozen sections has hitherto been systematically applied to the child, in one case only, by Professor Dwight. Dr Symington has added to our knowledge by presenting us in this work with fourteen coloured lithographic illustrations, all life-size, and thirty-three woodcuts taken from sections of male and female children, aged four years and a half, five years, six years, and thirteen years, and has given us a large number of very accurate observations on the position of the various organs and viscera, and the changes which they undergo in the earlier periods of life. The horizontal sections have been taken from a girl six years of age, whilst the vertical sections (both coronal and sagittal) are from children of both sexes and various ages. In addition to the illustrations, the work is most valuable for excellent letterpress, treating very fully and minutely of the position of structures at all periods of early life, and it is evident that many of the views generally held in regard thereto will have to undergo considerable alteration. For example, Dr Symington shows that the external auditory meatus is relatively as long in the child as in the adult, when examined in the fresh state in subjects with the entire head frozen; that the spinal cord in the newly-born child ceases at much the same point as in the adult; that the child's neck is not relatively short, but that it is higher in relation to the vertebral column than in the adult. The common assumption that the position of the stomach in the child is vertical is also shown to be erroneous, and is proved by figures taken from an infant four days old, and from a girl six years of age. The portion of the book devoted to the position of the pelvic viscera in male children is of great importance to surgeons, and will be carefully studied in view of operations on the urinary organs in early life. Too much praise cannot be bestowed upon the author for the obvious care and industry with which he has pursued his investigation, and the accuracy and fidelity with which he has reproduced its results. Its dedication to Professor Braune is a most graceful compliment to an anatomist who has done more to advance the knowledge of Topographical Anatomy than any other worker in this special branch. —*The Lancet*, 22nd October 1887.

IN THE PRESS. NEARLY READY.

THE
Conservative Treatment
OF
Tubercular Joint Disease
and Cold Abscess

AS CARRIED OUT AT Breslau BY

Prof. J. VON MIKULICZ, LL.D. Edin.

BY

DR A. HENLE,

Chief Assistant at the Surgical Klinik, Breslau.

WITH PREFACE BY PROFESSOR J. VON MIKULICZ.

TRANSLATED FROM THE GERMAN BY

CHARLES W. CATHCART, F.R.C.S.,

*Senior Assistant Surgeon, Royal Infirmary,
Edinburgh.*

Third Edition, in 2 vols., price 18s.

ILLUSTRATED WITH 238 USEFUL ENGRAVINGS.

APPLIED ANATOMY

BY

JOHN M'LACHLAN, M.D., B.Sc., F.R.C.S.E., etc.

The Book includes what is usually known as—

1. SURGICAL ANATOMY. 2. MEDICAL ANATOMY.
3. OPERATIVE SURGERY.

USED AS A TEXT-BOOK IN THE PRINCIPAL UNIVERSITIES & MEDICAL COLLEGES.

THE *modus operandi* of all the more important SURGICAL OPERATIONS—Instruments required, Duties of Assistants, etc., etc.—are carefully described, as well as Fractures and Dislocations, together with their necessary Treatment.

GENERAL CONTENTS OF VOL. I.

Aneurism and its Treatment—Medical Anatomy of Thoracic Aorta and its Branches—Ligature of Arteries—Amputations—Excision of Bones and Joints—Dislocations and Fractures, with their Treatment—The Eye and Ear.

GENERAL CONTENTS OF VOL. II.

Operations on, and Anatomy of—The Air Passages, The Larynx, Oesophagus, Cut Throat, The Pharynx. Operations on—Nerves, Tonsils, Lower Jaw, Branchial Clefts and Fistula, Ranula, Hare Lip and Cleft Palate, The Teeth, Scalp. Operations—Fractures, and Medical Anatomy of—Cranium and Brain, Thyroid and Parotid Glands, Tongue, Nose, The Antrum, Cranial Nerves, Upper Extremity, Lower Extremity, The Chest. Medical and Surgical Anatomy of—The Mamma, The Spine, The Spinal Cord. Medical Anatomy of—Spina Bifida, The Abdomen. Operations on, and Anatomy of—Liver, Spleen, Pancreas, Kidney, Hernia, The Perineum. Operations for Stone in the Bladder, The Urethra, Operations on—The Testicle and Hydrocele, Rectum, Penis, Fascia of Abdomen. Gynæcological Operations. Origin and Insertion of Muscles. Explanation of Terms used in Eye Surgery.

APPLIED ANATOMY.

OPINIONS OF THE PRESS.

'It deserves every success.'—Sir GEORGE MACLEOD, Professor of Surgery, University of Glasgow.

'If the medical student of to-day comes to an examination unprepared, and retires without his diploma, he certainly cannot lay the blame of his failure on want of instruction. With systematic courses of lectures constantly increasing in number and severity, with tutorial classes, with extra fees and extra hours, to assist him in assimilating the indigesta moles that is spooned into his unlucky brain, by the constant yearly deciphering of ancient manuscripts, with text-books to be mastered which contain not only all that is really known on any subject, but also all the facts which the respective authors have evolved from their own conceit, and therefore believed to be valuable,—no wonder the poor victim appears at the examination stuffed, not taught, with material, crammed, not digested. To help the student in his difficulties, to guide him in the waste wilderness of his poor lecture-room notes, and to give him a chance of learning something, the student has to find for himself men that can really teach him, and books that convey useful information, information that will bear not only on the work of the examination, but also on his future professional life. Dr M'Lachlan is such a teacher, and his book is of the kind we mean. It is a successful attempt to show how the facts of Anatomy are necessary as a groundwork both of Surgery and Medicine. If mastered it will do the student more good than acres of MSS. dealing with theory and fad, for it makes his anatomy interesting, and the bedside or the operating theatre intelligible, and, except, where vested interests in fees come in, it is pretty generally acknowledged now that the dissecting-room, the laboratory, and the hospital are the real places of study.'—*Edinburgh Medical Journal*.

'The text is copiously illustrated with well executed engravings, numbering altogether 238 as against 74 in the former edition. The author has produced a work which is more fitted to meet the wants of the student and the practising surgeon in the application of anatomy to practice, than any other which has come under our notice.'—*Hospital Gazette*.

'The book is written specially with a view to the requirements of students preparing for the higher examinations; and its successive editions have, in this regard, been each one more perfect than the last. In this issue much new matter and many new illustrations have been added. The work may be cordially recommended to students as a complete and practically useful text-book.'—*Scotsman*.

Just Published. Fifth Edition.

Price 10s. 6d. net.

THE STUDENTS' HANDBOOK
OF THE
PRACTICE of MEDICINE

*DESIGNED FOR THE USE OF STUDENTS
AND JUNIOR PRACTITIONERS.*

BY

H. AUBREY HUSBAND, M.B., C.M.,

B.Sc., F.R.C.S.E., M.R.C.S., L.S.A.,

FORMERLY LECTURER ON MEDICAL JURISPRUDENCE AND PUBLIC HEALTH IN
THE EXTRA-ACADEMICAL SCHOOL, EDINBURGH.

MEMBER OF THE GENERAL COUNCIL OF THE UNIVERSITY OF EDINBURGH ;

EXTRAORDINARY MEMBER OF THE ROYAL MEDICAL
SOCIETY, EDINBURGH ;

AND CORRESPONDING FELLOW OF THE MEDICO-LEGAL SOCIETY
OF NEW YORK.

*ILLUSTRATIONS, TABLES, PRESCRIPTIONS,
AND GLOSSARY.*

The STUDENTS' HANDBOOK of the PRACTICE of MEDICINE.

OPINIONS OF THE PRESS.

'The book before us is an excellent example of its class; the whole of medicine is digested and tabulated, and in fact served up ready prepared at infinite pains to render it easily assimilated.'—*Lancet*.

'The distinguishing features of Dr Husband's handbook are condensation and clearness of diction—qualities which are certain to ensure for the book a favourable reception by those for whom it is intended. We have pleasure in recommending it to our readers as a most useful work to peruse immediately before presenting one's self for a Medical Examination.'—*Students' Journal*.

'The book is not put forth as a systematic treatise upon diseases and their treatment, but under each section will be found a brief statement of the main points connected with all the diseases enumerated in the nomenclature of the Royal College of Physicians, London. From the point of view of the uses to which this Manual is designed, we know of no work that can be put in comparison with it.'—*Provincial Medical Journal*.

'Whether as a handbook for use as an introduction to the systematic study of disease, or for the purpose of refreshing the memory on the eve of an examination, the work is equally to be commended, and one may safely assert that it will retain its well-earned popularity.'—*Hospital Gazette*.

'A Fourth Edition of this handbook needs but little notice. From the time when it was first offered as a help to students working for examination, it has with each edition increased in size and fulness. A special feature of this edition, and one which will commend it to students, is the addition of a set of Tables for diagnostic and other purposes. The increased size of the book is due to these tables, and to additions made to the chapters on the nervous and circulatory systems. It would be altogether undesirable if the excellence of this book were to keep any man in his student days from reading the classical text-books; on the other hand, while the present examination system is in force, such a book as Dr Husband's is a necessity, and his we can recommend.'—*Edinburgh Medical Journal*.

Sixth Edition, Revised and considerably Enlarged.
Illustrated by Coloured Plates, price 10s. 6d. net.

THE STUDENTS' HANDBOOK
OF
FORENSIC MEDICINE, TOXICOLOGY,
AND
PUBLIC HEALTH

BY H. AUBREY HUSBAND, M.B., C.M.,

B.Sc., M.R.C.S., L.S.A., F.R.C.S.E.,

Author of 'Student's Handbook of the Practice of Medicine,' etc.

Used as a Text-book in the principal Universities and Medical Schools in
Great Britain, India, and the Colonies.

'It is intended for students, and is for them very convenient. This edition fully sustains the acceptableness of the work.'—*Lancet*.

'The work is an excellent epitome of the subjects on which it treats, and contains all that the student need know to pass his examinations, or that the ordinary practitioner will require in the course of his practice. . . . As a trustworthy and readable guide to the study of forensic medicine, we can strongly recommend it to both students and practitioners.'—*Student's Journal*.

'The book is one which can be commended, and will in the future, as in the past, doubtless smooth the passage of many medical students through the difficulties of the examination room.'—*Public Health*.

'The work has long enjoyed a pre-eminent reputation as a book useful to students about to proceed to examination in the subjects of which it treats; and men have been known to boast of having secured academic degrees by no more than a cursory perusal of its pages. They toiled not; but, being possessed of this handbook, neither were they spun. The new edition gives the book in an improved shape. The text has been revised, new matter has been added; and some professionally beautiful illustrations now appear in the work. For the rest, this edition keeps the handbook well abreast of its reputation.'—*Scotsman*.

JUST PUBLISHED.

Price 2s. 6d. net.

*ILLUSTRATED BY NUMEROUS WOODCUTS PLAIN
AND IN COLOUR.*

MIDWIFERY NOTES

For the use of Students.

BY

T. A. GLOVER, M.D.(Edin.)

Fellow, Obstetrical Society, London, &c.

Second Edition, price 6s.

THE
Student's Hand-book of Chemistry

By H. LEICESTER GREVILLE,

F.I.C., F.O.S., etc.

This book contains a large amount of information, condensed into Tables; also, the most important Chemical Calculations and Illustrations.

'The tabulation of facts, containing groups of elements and compounds, is a good feature in this book, and likely to prove very useful to the student. The chapters dealing with Organic Chemistry are clear and succinct.'—*Nature*.

'This book has many merits. It is clearly and pleasantly written, is well arranged, and contains a great deal of useful and important fact, much of it embodied in Tables.'—*Lancet*.

'A concise and useful Manual. The work has been revised and made more valuable by the addition of several Tables and much new matter in the text. The calculations are very useful.'—*Scotsman*.

'A series of Tables forms a useful feature of the work.'—*Pharmaceutical Journal*.

'This compact and handy little Manual will be found a useful guide by ordinary and especially medical students.'—*Medical Press and Circular*.

'The work before us, however, may claim some very decided merits. We may venture to say that the author's primary object is to enable the student not so much to "pass" as to "know." He has appended to the treatise a very useful glossary or collection of definitions of the principal terms used in Chemistry.'—*Chemical News*.

'This is an excellent Manual, and is likely to maintain its place among the many manuals of Chemistry. It is likely to be popular with students.'—*Edinburgh Medical Journal*.

'This is an elementary treatise embodying several valuable original features, among them Tables and examples for general Chemical calculations, also Tables in which a great deal of information has been compressed into a small space, making it more accessible to the student.'—*American Chemical Review*.

'The work deals with both Organic and Inorganic Chemistry, and much information has been compressed into small compass. It is well adapted as a hand-book for medical students, being furnished with a copious index, and the text is given in such a form as will render it readily accessible to the student. We commend the work to the attention of Canadian students.'—*Canadian Lancet*

Fifth Edition, Revised and Enlarged, price 6s.

MANUAL OF
Materia Medica and Therapeutics

FOR THE USE OF STUDENTS AND PRACTITIONERS.

By WILLIAM CRAIG, M.D.,

C.M., F.R.S.E., F.R.C.S.E., etc.,

Lecturer on Materia Medica in the Edinburgh School of Medicine,

Examiner at the Royal College of Surgeons, Edinburgh,

Examiner at Edinburgh University.

Used as a Text-book in the principal Universities and Colleges in
 Great Britain, India, and the Colonies.

'As the work stands it forms a very clear and complete guide to the study of the properties and uses of the pharmacopœial preparations, and we can endorse thoroughly the good opinion we were enabled to pass upon the previous edition. The excellent Posological Table is very valuable, as are the hints on Prescription Writing, and the very succinct Index of Diseases with their Remedies. As a compendium of Materia Medica and Therapeutics, of moderate size, but full of information, we know few to surpass, even if to equal, the Manual before us. We have ourselves made a constant companion of the former edition, which has never failed us.'—*Students' Journal*.

'This book contains sound sense and original information, and will prove a good pocket companion for the student.'—*Medical Times and Gazette*.

'Your "Manual" will be useful to me in various ways, teaching included, and I should think it will be regarded as a boon by students preparing for their examination.'—Professor HARVEY, Aberdeen.

'This concise little Manual, though intended primarily to assist students attending the author's own classes, possesses several characteristics which have rendered it more generally popular. Special emphasis is laid upon alterations in nomenclature which might otherwise escape attention. The volume concludes with a Posological Table, a Schedule of Poisons and their Antidotes, together with an Appendix of Contracted Terms in Common Use. It is beautifully printed, and is altogether a very handy and convenient volume for the use of students preparing themselves for examination.'—*British Medical Journal*.

'This being a fifth edition, calls for very little remark. The amount of condensation of material is truly surprising; useful facts are stated so briefly that, *a priori*, it would give the impression of a peculiarly dry and uninteresting introduction to a very difficult subject. The author's hope that the book would be of service to students preparing for their professional examinations can surely only be realised when a concise epitome is required in the few weeks immediately preceding examination, and when the student is already familiar with the subject.'—*Lancet*.

Demy 4to., price 7s. 6d.

Illustrated with 10 Coloured Plates.

NERVES OF THE HUMAN BODY

BY

ALFRED W. HUGHES, M.B. & C.M. Edin.;

F.R.C.S. Edin.; M.R.C.S. Eng.;

Professor of Anatomy, South Wales Medical College, Cardiff.

'An excellent work of reference for students, quite in place in a Medical School library. The drawings are large and bold, demonstrating the distributions and connections of the cranial and spinal nerves with clearness and accuracy. The cranial nerves in particular are well represented. . . . The preparation of "Nerves of the Human Body" must have cost its author much trouble, and Dr Hughes may be congratulated on the result of his labours.'—*British Medical Journal*.

'As regards the work little is left to be desired. As far as the diagrammatic and literal description of the nerves goes, this work is undoubtedly good; and there is no doubt that the anatomical details are an improvement on those usually given. It will be found a help to students in their practical work, and of equal help to the practitioner in his pathological and therapeutic investigations.'—*Provincial Medical Journal*.

'The diagrams are very clear. The text contains a well arranged summary of the main facts of the origin, course, and distribution of the cranial, spinal, and sympathetic nerves. It is a work that may be consulted with confidence by the student, and which he will find a useful aid in gaining a knowledge of the nervous system.'—*Edinburgh Medical Journal*.

'A thoroughly excellent contribution to anatomical literature, will be valuable to those struggling hard with the most difficult subject in human anatomy. The diagrams cannot be praised too much.'—*The Student*.

'Dr Hughes' book, "The Nerves of the Human Body," simplifies the task in a way unknown to the student of Gray and Quain. The diagrams are beautifully executed.'—*Scotsman*.

'Mr Hughes has shown more daylight into that dark subject than any of his predecessors. The book can be safely recommended to all students.'—*College Column*.

'The special feature of the book, is a series of ten beautifully executed Plates of Diagrams, in which the different nerves are very distinctly figured. The work is intended as a special adjunct to the standard text-books of Practical Anatomy, and as such it can scarcely fail to be of great assistance to students who will use it intelligently.'—*Scottish Leader*.

Second Edition, Price 6s.

Revised and Enlarged, with 12 Tinted Plates and 40 Woodcuts.

MANUAL

OF THE

Minor Gynecological Operations and Appliances

By J. HALLIDAY CROOM, M.D.,

F.R.C.P.E., F.R.C.S.E.,

*Lecturer on Midwifery and Diseases of Women, School of Medicine ;
President of the Obstetrical Society, Edinburgh ; and
Examiner in Midwifery in the University of Edinburgh and Royal College
of Physicians, Edinburgh.*

'The descriptions and recommendations of Dr Croom seem entirely familiar, intelligible, and wholesome. A number of well-executed lithographic plates, giving various relations of the pelvic organs, add to the value of the book.'—*American Journal of Obstetrics.*

'The work is admirably adapted as a practical guide to obstetric clinical clerks, house surgeons, and physicians, as well as medical practitioners. It is well arranged throughout, and will, no doubt, retain the hold it has already taken.'—*London Medical Record.*

'The Second Edition is considerably modified, and forms almost a completely new book. The clearness and conciseness of the author make his Manual most useful both for practitioners and students.'—*Bulletin General de Therapeutique.*

'All that is of doubtful value is purposely omitted, and only the methods of examination and treatment recognised as the best are described concisely and with capital illustrations. The book, which embraces all the gynecological operations with the exception of the abdominal, is in a high degree likely to fulfil its aim for students.'—*Centralblatt für Gynækologie.*

'We are glad to see that this valuable Manual has run into a Second Edition. Its arrangement is such as will commend itself both to the student and busy practitioner. We finish the perusal of this work impressed with its simplicity of arrangement and lucidity of expression.'—*Liverpool Medico-Chirurgical Journal.*

'This is an admirable book, for which we are sure the student in midwifery and the diseases of women will be very grateful. We commend it heartily to students, for whose use it is chiefly written, and even practitioners will find it very handy and suggestive in many of the emergencies of practice.'—*Lancet.*

'Both students and practitioners will find in it descriptions, hints, and directions—clear, practical, and useful.'—*Practitioner.*

THIRD EDITION.

Fifth Thousand, price 5s. net.

Illustrated by about 40 Plates (many Coloured) or 109 Figures.

Anatomy of the Brain and Spinal Cord

BY

J. RYLAND WHITAKER, B.A., M.B. (Lond.),
F.R.C.P., L.R.C.S. (Edin.);

*Lecturer on Anatomy, Surgeons' Hall, Edinburgh;
Examiner for the Triple Qualification.*

Used as a Text-Book in the principal Universities and Medical Colleges
in Great Britain, India, the Colonies, U.S.A., and Italy.

Opinions of the Press.

'The book is an excellent Manual for the use of Students and makes a good introduction to the heavier text-books. This Edition is made more valuable by the inclusion of some new matter in the text, and by the addition of many new figures and tables.'—*Scotsman*.

'The book consists of an exceedingly clear account of the central nervous system.'—*British Medical Journal*.

'For a clear and concise description of the nervous centres it has not been surpassed.'—*Journal of Mental Science*.

'We are pleased to see that Messrs E. & S. Livingstone have issued a Second Edition of Dr Whitaker's admirable Anatomy of the Brain and Spinal Cord.'—*Edinburgh Medical Journal*.

Price 4s. 6d. net.

Notes on Pathology

BY J. RYLAND WHITAKER,

B. A., M.B.(Lond.), F.R.C.P., L.R.C.S.(Edin.);

Lecturer on Anatomy, Surgeons' Hall, Edinburgh;
Examiner for the Triple Qualification.

AUTHOR OF 'ANATOMY OF THE BRAIN AND SPINAL CORD.'

Vol. I.—GENERAL. Vol. II.—SPECIAL (*in preparation*).

Used as a Handbook in the principal Universities and Colleges.

'These "Notes," which traverse the whole range of General Pathology, have evidently been compiled with great care. Together, they form an outline of the subject of which it will not be difficult for the student to fill in such details as he gathers from his lecturer or his text-book. The author himself recognises this as the main object of his publication, and we may say at once that he has done his work well, and that it should prove of much utility. In these days of "compendia" of knowledge, where the aim often seems to be to condense into as small a space as possible the facts of science, so that the student may be saved the trouble of learning them step by step, it is gratifying to find a writer who takes a higher view of the kind of assistance that the student needs. The information he conveys in his little work is considerable, and also accurate; in parts even—*e.g.*, in the sections dealing with Inflammation and the Parasites—it is almost, if not quite, as full as is to be found in many a text-book. But it would be difficult for the student to use the work simply for the purpose of "cram." We believe, moreover, that teachers also may be glad of so concise a summary of the subject as Mr Whitaker has given.—*Lancet*.

'This is evidently the first part of what may be described as a useful synopsis for students, and it deals purely with General Pathology. The author has attempted to outline the causation and pathological characters of disease; and in a neat, concise way every subject is dealt with so as to give a concentrated idea of the varieties of disease and the nature of their pathological processes. The arrangement of the book is in Sections—the first of which is devoted to Altered Conditions of the Circulation; another treats of Inflammation and its Results; a third of Retrogressive and Progressive Changes; and the last of Parasites and Parasitic Diseases. As a digest it is a remarkably good book, without padding or unnecessary verbiage, and with a comprehensive survey of causation and the varieties of allied or similar pathological processes. For the student it will prove an admirable memory help, and for the practitioner it will frequently be sufficient when he does not require to dip exhaustively into a subject.—*Glasgow Herald*.

Price 10s. 6d.

THE STUDENTS'
Handbook of Medicine
AND
Therapeutics.

BY ALEXANDER WHEELER,

Clinical Assistant, Out-Patient Department, Edinburgh Royal Infirmary.

Author of "OUR UNSEEN FOES," &c.

Used as a Text-Book in the principal Universities and Colleges.

'It is distinctly designed to refresh the memory on salient points, as well as to enunciate the leading principles of treatment. These aims have been faithfully carried out, and that too with an originality for which it might be thought there could be little scope. Clear, concise, and accurate.'—*Lancet*.

'This excellent little volume . . . Many good coloured and uncoloured diagrams illustrate the book, and we think the young practitioner can hardly make a better investment than the purchase of Mr Wheeler's work. It is up to date in pathology and treatment, and is a model of clear, terse writing.'—*Medical Press and Circular*.

'This is an exceedingly good little work, unpretentious, it is true, but fulfilling far more than it pretends. We have nothing but praise for the work. As a whole, it shows a remarkable power of imparting information in a clear and easily remembered style; and the author's practice of giving explanations and reasons for every step in the treatment of disease strikes us as being particularly suitable for the needs of the men to whom he appeals. We heartily recommend it to the overworked final man.'—*The Student*.

'The volume is carefully compiled and well written, and is, in our opinion, destined to take high rank amongst its competitors. It can be profitably read either by the student on the eve of an examination to refresh his memory, or by the busy practitioner for the same purpose. We venture to predict that a Second Edition will shortly be called for.'—*The Quarterly Medical Journal*.

Price 4s. 6d. net.

ILLUSTRATED WITH 8 COLOURED PLATES.

MANUAL of SURGICAL ANATOMY

BY

ALFRED W. HUGHES,

M.B., C.M., F.R.C.S. Edin.; M.R.C.S. Eng.;

Professor of Anatomy, King's College, London. Author of
'Nerves of the Human Body,' &c.

Used as a Handbook in all the Universities and Medical Colleges.

'This little book contains very terse descriptions of the anatomical facts most important to students about to present themselves for their Final Examination in Surgery. Clearness sometimes, and elegance of diction often, have been sacrificed to brevity. It will commend itself to those for whom it is specially prepared.'—*Lancet*.

'Dr Hughes evidently possesses the faculty of condensing a large amount of information into a small space in a clear and methodical manner. The student will find it a very reliable guide. The work contains a number of excellent illustrations, which will greatly assist the student in learning the relative positions of various structures which he would encounter in the ligature of the principal arteries.'—*Edinburgh Medical Journal*.

'No book could be better adapted for Examination purposes. The book may be safely recommended.'—*Hospital*.

'Here is a simple book plainly written with the main facts of the subject clearly exposed; it is easily understood, easily remembered; it can be read through in half-a-dozen hours. We recommend it to you, its perusal will supply you with many excellent and useful anatomical facts which you ought to know.'—*Dublin Journal of Medical Science*.

'Dr Hughes' book will supply the gap existing betwixt the more elaborate Manuals of Surgical Anatomy on the one hand, and the mere outlines, used for "cramming" purposes, on the other. The work is a useful one, and we have perused it with the result of finding that most of the important points involved in the common work of the Surgeon have been duly noted. The section on Hernia in particular strikes us as being excellently done. The Plates illustrating the book have the relations of Arteries, Veins, and Nerves printed in colours, this plan facilitating easy reference to the details they expound.'—*Glasgow Herald*.

'A brief concisely-written handbook, covering that department of Anatomy which concerns students who seek only the usual Surgical qualifications.'—*Scotsman*.

Demy 8vo, price 4s. 6d. net.

Vaccination Eruptions:

Original Research.

BY THOMAS DOBSON POOLE, M.D.,

Master in Surgery, University of Edinburgh; Fellow of the Obstetrical Society.

'The author classifies eruptions as follows:—(1) Those due to pure vaccine inoculation, (2) those due to mixed inoculation. He enters at length, and very properly, into the question of the qualities of the lymph itself, of its origin and cultivation, and here is the *crux* of the whole question. The question of the artificial cultivation of the lymph is a very important one, and the author suggests a method which we trust may either solve the problem or mature its consideration. The work is one well worthy of consideration.'—*Glasgow Herald*.

'The title of this very interesting work concisely indicates its contents. A good acquaintance with the literature of the subject is shown on every page, and the cited cases are of great interest, especially those in connection with the subject of generalised vaccine eruption (*vaccine généralisée*). The differential diagnosis between vaccination ulcers and primary chancres, also between vaccination eruptions and secondary syphilitic manifestations, is given *in extenso* from Portalier's summary of Fournier's lectures. The author concludes from a study of tuberculosis, including his own experiments, that its transmission by means of official vaccination is "beyond the limits of possibility." In conclusion, this work deserves perusal by all who are interested in the subject of vaccination, therefore by all medical practitioners.'—*British Medical Journal*.

'The author of this little work has made himself well acquainted with most of the reliable literature of recent date bearing on his theme, and has put into a convenient and useful form a great deal of information that could otherwise be obtained only by hunting through a variety of medical periodicals and other publications. The work ought therefore to be welcomed by all who have much to do with vaccination, and especially by public vaccinators, who are the only persons likely to have the opportunity of meeting with some of the very rare vaccinal sequelæ of which he principally treats. A chapter is very profitably devoted to vaccine syphilis. The chapter on tuberculosis is one of the best in the book. Other subjects shortly discussed are leprosy, erysipelas, vaccinia gangrenosa, etc. The work forms a really useful addition to the literature of vaccination, and ought especially to be read by every public vaccinator in the kingdom.'—*Glasgow Medical Journal*.

Price Five Shillings.

THE STUDENTS' HANDBOOK
OF
GYNECOLOGY.

~~~~~  
*Profusely Illustrated.*  
~~~~~

THE MOST PRACTICAL HANDBOOK
EVER PUBLISHED.

—————
Used as an Introductory Text-Book in all the
Universities and Medical Schools.
—————

'Everything is stated in a most clear and concise way, and as the volume is nicely illustrated, it should be of great assistance to final men especially.'—*Dispatch*.

'There are many who have serious doubts as to any real value being obtainable from such condensed forms of imparting information, but they are clearly very popular among medical students. The present volume makes no pretensions to compete with more exhaustive works, but it is hoped it will prove useful to beginners and to those who wish to synopsis and focus the knowledge obtained from larger works. It is clearly and concisely written, and it is surprising to find that it has succeeded so well, in the small space at its disposal, in covering the ground necessary for an elementary knowledge of this progressive and important branch of medical learning.'—*Scotsman*.

4to, price Sixpence net.

SCHEDULES FOR PLANT DESCRIPTION

(Illustrated)

BY JOHN WISHART,

*Lecturer on Zoology and General Biology in Robert Gordon's College, Aberdeen ;
Herbarium Medallist of the Pharmaceutical Society of Great Britain.*

~~~~~  
**USED IN ALL UNIVERSITIES AND COLLEGES.**

'The use of these Schedules by pupils will train their powers of observation and reasoning, and prevent them from being contented with book knowledge.'  
—*Dublin Journal of Medical Science.*

'These tables are admirably adapted and arranged on a scientific principle for building up an instructive record of plant examination.'  
—*Aberdeen Daily Free Press.*

---

BY THE SAME AUTHOR.

Price Two Shillings net.

## THE Botanists' Vade Mecum.

'A very handy little pocket guide to the classification of plants, intended for use during botanical excursions. The matter is very concise and well arranged, and the value of the book is very materially enhanced by an ingenious and novel form of index.'  
—*Guy's Hospital Gazette.*

'This little manual, of a size suitable for the pocket, will form a useful companion to students of botany in their field-days. Its arrangement is concise, and its information conveniently scheduled. A useful ledger-index adds to the convenience of the manual.'  
—*Glasgow Herald.*

'We commend this Vade Mecum as a very useful guide to all botanical excursion students, who will find it an invaluable aid to recognising the characters of the various divisions and natural orders.'  
—*British and Colonial Druggist.*

Price 2s. 6d. net.

**The Rotatory Movements**  
OF  
**The Human Vertebral Column**  
AND THE  
**So-called Musculi Rotatores.**

BY ALFRED W. HUGHES,

M.B. & C.M. Edin.; F.R.C.S. Eng.; F.R.C.S. Edin.;

*Professor of Anatomy, King's College, London; Author of  
'Nerves of the Human Body' and 'Manual of Surgical Anatomy.'*

'The entire work bears evidence of careful observation, and forms a useful contribution to the mechanism of the human skeleton.'—*Edinburgh Medical Journal.*

**NEW EDITION.**

Revised in accordance with the British Pharmacopœia, 1898.

Price One Shilling net.

**PHARMACOLOGICAL TABLES;**

**Appendix on Poisons; Index of Diseases;  
and Medicines arranged according to their Actions.**

By WILLIAM CRAIG, M.D.,

C. M., F. R. S. E.,

*Lecturer on Materia Medica, Edinburgh School of Medicine; Examiner in Materia  
Medica, Edinburgh University; Examiner, Royal College of Surgeons.*

Being a Tabular Arrangement of all the Medicines contained in the  
British Pharmacopœia, with Dose, &c.

'This is a useful little book, containing a tabular arrangement of all the Pharmacopœial preparations, with their doses and methods of administration. A table on Poisons and an Index of Diseases with Appropriate Remedies are included.'—*Lancet.*

Price 1s. 6d. net.

# Materia Medica Tables.

*Designed for the Use of Students.*

BY

A. HERBERT BUTCHER,

L.R.C.P., L.R.C.S. & L.M.,

*Honorary Surgeon to Birkenhead Borough Hospital.*

'This is a small work intended to supply a long-acknowledged want, and will be found to contain much information arranged in an admirably simple manner.'—*Publisher's Circular.*

Price 2s. 6d. net.

# THE STUDENTS' Handbook of Diseases of the Skin.

*Illustrated by Coloured Plates and Wood Engravings.*

'It is clearly and systematically arranged, and the student who masters its contents will have acquired a useful general knowledge of the pathological classification, course, and methods of treatment of all but the rarest diseases of the skin.'—*Manchester Guardian.*

'It will prove of service to the young practitioner, and also to older men in country practices, whose work leaves them but little time for the study of books of greater pretensions. A number of well-executed illustrations increase the working value of the book.'—*The Publisher's Circular.*

Second Edition. Price 6d. net.

Revised in accordance with the British Pharmacopœia, 1898.

# Dose Tables of Materia Medica

Containing all the Doses required for Examinations and Prescribing.

By T. HOMER, L.R.C.S., L.R.C.P. Edin.

Price 1s. 6d. in Paper Boards; or in Cloth, 2s.

## THE CHILD—HOW TO NURSE IT;

*Or the Management of Children and their Diseases.*

By ALEXANDER MILNE, M.D.

'Dr Milne not only describes how the Child should be managed from the hour of birth, but he notes the distinctive characteristics of all the ailments to which Children are liable, and gives instruction as to their proper treatment. A great many works have been published of late years, but there is certainly not one which is more likely to be of use to inexperienced or conscientious parents.'—*Scotsman*.

'This little work will be found to contain copious details on the management of infancy, expressed in language singularly free from technicalities.'—*Courant*.

'We heartily recommend the careful study of Dr Milne's invaluable work.'—*Ladies' Own Journal*.

'To emigrants and others who are at a distance from medical aid, we believe the book will be a "present help in time of trouble."'—*North Metropolitan*.

Price Threepence.

## The Monthly Nurse:

A FEW HINTS ON NURSING.

By H. AUBREY HUSBAND, M.B., C.M., B.Sc., etc.

'It can scarcely be said that a handbook of this kind is not required, and it is certain that a more clearly-arranged little work of the kind could not be found.'—*Scotsman*.

'A little Manual written in the simplest possible style, but containing invaluable advice and instruction for those who have to act as midwives. District visitors who should distribute copies of this pamphlet to poor mothers would save them much unnecessary misery.'—*Literary World*.

'We have very great pleasure in bearing testimony to this excellent little pamphlet. Monthly nursing, as it at present exists, is not at all in a satisfactory condition, and it is a relief to be able to get at some sensible advice and suggestions—Dr Husband supplies them here.'—*Medical Review*.

We supply the above two Works on special terms to District Visitors and Institutions using quantities for distribution.

Second Edition. Price Two Shillings net.

Revised in accordance with the British Pharmacopœia, 1898.

96 pp. Crown 8vo. Bound in Cape Morocco.

# The Students' Practical Materia Medica.

BY

MISS GRACE HAXTON GIFFEN,

L.R.C.P.E., L.R.C.S.E., L.F.P. & S.G.;

*'Bathgate' Gold Medallist in Materia Medica, Royal College of Surgeons; Senior Demonstrator of Anatomy, Ladies' School of Medicine, Edinburgh.*

---

'We recommend this little book.'—*Dublin Journal of Medical Science.*

'It contains a vast amount of information in small compass. Miss Giffen has produced a work which is likely to become popular with students preparing for an examination.'—*Edinburgh Medical Journal.*

'Medical students for whose use this book has been prepared will find it of great assistance. The work is clearly arranged, and is of a handy size for the pocket.'—*Publishers' Circular.*

'This is a very concise and practical manual, a summary and resumé of the principles of pharmacology, and the nature and uses of drugs with their doses. The method of the arrangement of the chapters is simple and intelligible and the doses of officinal preparations are stated under a system of classification which prevents reiteration and more readily impresses the memory.'—*Glasgow Herald.*

'It is at present the most succinct, lucid, and suggestive of all the manuals on the subject.'—*Scotsman.*

'It contains much useful information for those wishing to arrange and revise their knowledge for examination purposes.'—*Medical Press.*



FOURTH EDITION.

Price 2s. net.

**BOTANY NOTES**

SPECIALLY adapted for Students preparing for Professional Examinations in Medicine and Science. The various divisions considered in accordance with the several University Syllabuses.

BY ALEXANDER JOHNSTONE, F.G.S.,

AUTHOR OF 'ZOOLOGY NOTES,'

*Lecturer on Botany, School of Medicine, Edinburgh; and Natural Science Master, Blair Lodge.*

~~~~~

In reviewing 'Botany Notes,' and 'Botany—a Manual,' *The Lancet* says 'This little volume entitled "Botany Notes" traverses the same ground as the other book, but is rather more suitable for use on the evening preceding Exam. It is not too much to believe that, if the student does not receive material aid from the "Botany Notes" now before us, he has but small prospect of receiving assistance from any printed matter whatever.'—*Lancet*.

 Price 3s. 6d. net.
ZOOLOGY NOTES

SPECIALLY adapted for Students preparing for Professional Examinations in Medicine and Science. The various divisions considered in accordance with the several University Syllabuses.

BY ALEXANDER JOHNSTONE, F.G.S.,

AUTHOR OF 'BOTANY NOTES,'

Lecturer on Botany, School of Medicine, Edinburgh; and Natural Science Master, Blair Lodge.

~~~~~

'This useful little manual is divided into three parts. The first part is devoted to General Morphology, Histology, and Physiology, and to the Protozoa and Vermes; the second part treats of Vermes, Mollusca, and Arthropoda; and the third is occupied with Classes from Arthropoda to Man. The plan pursued is that a brief account of each class is given, then in succession the sub-classes and divisions are described, and finally a detailed account of some animal, as the anodonta amongst mollusca, and nephrops amongst crustacea. The descriptions, though short, are accurate.'—*Lancet*.

## THE CATECHISM SERIES.

(NEARLY ALL THE PARTS ARE ILLUSTRATED.)

Price One Shilling net, each Part.

### ANATOMY.

- |                         |  |                       |
|-------------------------|--|-----------------------|
| Part 1—Upper Extremity. |  | Part 4—The Abdomen.   |
| " 2—Lower Extremity.    |  | " 5—The Thorax.       |
| " 3—Head and Neck.      |  | " 6—Bones and Joints. |

### BOTANY.

[In the Press.]

Price One Shilling net, each Part.

### CHEMISTRY.

- |                   |  |                               |
|-------------------|--|-------------------------------|
| Part 1—Inorganic. |  | Part 2—Inorganic and Organic. |
|-------------------|--|-------------------------------|

Price One Shilling net.

### FORENSIC MEDICINE.

[ONE PART.]

'The aim of the Series is to help the student in preparing his works for examination without the aid of a tutor. The Questions are very suggestive, and are such as are likely to be given at examinations. The Answers are concise and clear. The reading of these books just before going in for an examination will be of considerable use in recalling the most important points to memory.'—*Illustrated Medical News*.

'The arrangement of questions and answers seems to be admirably adapted for fixing the facts in the mind of the student, and for a busy man preparing for examination nothing could be handier than these booklets.'—*Glasgow Herald*.

## THE CATECHISM SERIES.

---

Price One Shilling net, each Part.

### MIDWIFERY.

[TWO PARTS.]

---

'Messrs E. & S. Livingstone have made a desirable addition to their Catechism Series of Medical Handbooks. The little work just issued deals with the all-important subject of Midwifery, and is complete in two Parts of the usual size and price. Within this small compass there is no inconsiderable amount of useful matter relative to amongst other things—menstruation, pregnancy, parturition, instrumental deliveries, præternatural and complex labours, foetal complications, puerperium, and the feeding of the infant. This information, conveyed in answers to the many questions set, is intelligently put, carefully prepared, and accurate in detail. The letterpress is interspersed here and there with sketches. To say that these small books will be of help in memorising important points, and of special service when preparing for an examination, is but to reiterate what has been so often expressed in regard to other volumes in this capital series.'—*Dispatch College Column.*

'Like some of our famous medical contemporaries, we are not altogether in love with the pernicious cram-book. Some men think that by vigorous grinding of a cram-book, for a week or two previous to an exam., work can be easily got up. No greater mistake can be made: slow but sure "absorption" is the only royal road to the happy condition of knowing one's work. After work has been properly got up, we know of no better way of refreshing one's memory of details than by a judicious use of books such as those produced by Messrs E. & S. Livingstone in their Catechism Series. Midwifery, Part I., is a very commendable little volume, and its sections bearing on the pathology of pregnancy and the pelvis, normal and abnormal, are first-class. Part II. is very good on instrumental delivery and the pathology of puerperium, whilst a short chapter on the feeding of the youngster contains much valuable information for men hoping soon to be let loose on the public. As an aid to systematic reading to seniors, we can really recommend those little volumes. They are thoroughly in accordance with the principles and practice of Midwifery as taught in this School.'—*The Student.*

## THE CATECHISM SERIES.

---

Price One Shilling net, each Part.

### MATERIA MEDICA.

- Part 1—Mineral Waters, Foods, and Inorganic.  
 " 2—Inorganic.  
 " 3—Orders and Plants and Vegetable.

Price One Shilling net, each Part.

### PHYSIOLOGY.

- Part 1—Chiefly Histology.  
 " 2—Circulation.  
 " 3—Blood; Respiration.  
 " 4—Digestion.  
 " 5—Intestines; Blood Glands; Kidneys.  
 " 6—The Skin, Animal Heat, Voice and Speech, Smell and Taste.  
 " 7—Eye, Ear, and Cranial Nerves.  
 " 8—Spinal Cord, Brain, Reproduction, Physiological Chemistry.

Price One Shilling net, each Part.

### PUBLIC HEALTH.

- |                          |                               |
|--------------------------|-------------------------------|
| Part 1—Water.            | Part 5—Medicine, Food, Water- |
| " 2—Air and Ventilation. | Closets, Disinfectants,       |
| " 3—Sewage.              | Warming, Hospitals,           |
| " 4—Vital Statistics.    | etc.                          |

'We have pleasure in recommending the series to all who are interested in a certain impending and rapidly approaching event.'—*Student.*

'These manuals are the best things of the kind in existence.'—*Scottish Review.*

## THE CATECHISM SERIES.

---

Price One Shilling net, each Part.

### SURGERY.

- Part 1—Hæmorrhage—Repair—Inflammation—Suppuration—Ulceration—Mortification—Erysipelas—Wounds—Burns.
- " 2—Fractures and Dislocations of the Upper Extremity.
- " 3—Fractures and Dislocations of the Lower Extremity—Diseases of Blood-Vessels and Lymphatics.
- " 4—Tumours—Diseases of Bones—Diseases of Joints.
- " 5—Injuries and Diseases of Muscles and Nerves (Club-Foot, Whitlow, Ganglion, &c.)—Venereal Diseases.—REGIONAL SURGERY: Injuries and Diseases of the Head.
- " 6—REGIONAL SURGERY: Face, Nose, Mouth, and Tongue; Oesophagus, Hare-Lip, Neck, Tracheotomy, &c.; Thorax and Mamma.
- " 7—REGIONAL SURGERY: Vertebral Column, Abdomen Rectum, Urinary and Genital Organs, &c.

---

### Surgical Anatomy and Operations.

[TWO PARTS.]

---

### TOXICOLOGY.

[ONE PART.]

---

### ZOOLOGY.

Part 1—INVERTEBRATA.      Part 2—*In the Press.*

~~~~~

'The little works are carefully put together, and will prove of use to students preparing for examinations.'—*College Column.*

'They cannot fail to be popular with students.'—*Hospital Gazette.*

'We recommend these little books to students, for we feel sure they will help to refresh the memory, specially if about to pass an "exam."'—*Journal of Microscopy.*

'We must commend the general accuracy and clearness of the descriptions.'—*Glasgow Medical Journal.*

C 3,0.

THE CATECHISM SERIES.

Price 1s. net, each Part.

Examination Questions

IN

PRACTICE OF MEDICINE

WITH ANSWERS.

PART 1.—GENERAL DISEASES.

PART 2.—SKIN DISEASES.

PART 3.—FEVERS.

Adapted for those who are Preparing themselves for the
Final Examination.

‘We must give the writer credit for having made a judicious selection from the enormous mass of material which he had to sift. The information given under the headings of treatment is often very good indeed. The booklet will be of use for the class of readers for whose benefit it was professedly prepared.’—*Dublin Journal of Medical Science*.

‘These little books are very valuable in refreshing the mind of the student.’—*Daily Free Press*.

[Other Parts will follow.]

THE CATECHISM SERIES.

Price 2s. 6d. net each Part.

PATHOLOGY.

Part 1. GENERAL. Part 2. SPECIAL.

Price 2s. 6d. net. Illustrated.

PHYSICAL TRAINING

Its Theory and Practice

Being an Elementary Treatise on the necessity and effects of exercise.

By H. RIPPON SEYMOUR

Gymnastic and Fencing Master, George Watson's College, Edinburgh.

With an introduction by
WILLIAM TAYLOR, M.D., F.R.C.P.E.

'It gives so much instruction in anatomy and physiology as is necessary for an intelligent understanding of the useful series of exercises it enumerates, and sets forth in a clear and interesting way the advantages that come of a scientific study of physical culture.'—*Scotsman*.

'I can heartily recommend this book to all athletes. It will well repay perusal.'—*The Athletic Times*.

'This is a very praiseworthy attempt to connect the theoretical and practical physical training in one book, and it easily succeeds in being both concise and intelligible.'—*Publishers' Circular*.

Second Edition, price 12s. 6d.

THE
Principles and Practice
of Midwifery

BY ALEXANDER MILNE, M.D.,

Ex-Vice-President of the Edinburgh Obstetrical Society.

'The very favourable reception accorded to the first edition was well merited, the work being thoroughly practical, and very readable—not too diffuse nor exhaustive, yet containing sufficient details for all examination purposes. The Second Edition has been carefully revised, and such additions made as were rendered necessary through recent advances in the obstetric art. We have no doubt that the Second Edition of Dr Milne's Manual will be more popular with medical students than the first.—*Students' Journal.*

'Dr Milne has contrived to condense a great amount of obstetric doctrine, both physiological and pathological, into his book.'—*Lancet.*

'I estimate highly the thought, the labour, and the courage expended in the work.'—Dr J. MATTHEWS DUNCAN, London.

'A very excellent and comprehensive Manual.'—Professor GRAILY HEWITT, London.

'An admirable digest of the subject.'—Professor A. R. SIMPSON, Edinburgh.

'This is the second edition of the handiest, simplest, and soundest of our works on obstetrics. The author is not only an honoured public teacher, whose wisdom, judgment, learning, and skill, have endeared him to his many pupils, who longed to have his instructions in a more permanent form, but he is a medical practitioner of great experience and of recognised skill. Dr Milne has produced a work intended at once for medical students and for the profession, and these show their appreciation of it by taking care that it has a place on their shelves. The leading obstetricians, the medical press, and the teachers in our more eminent medical schools, all highly recommend the work for its comprehensiveness, its soundness, and its real practical helpfulness. In fifty-two chapters, which are as scientific as they are simple, as gracefully written as they are instructive, and as interesting as they are important, the author covers the whole ground of his subject. His definitions, expositions, and instructions, are very clear. Medical students, as well as practitioners, who have not seen this splendid volume, ought to secure it at once. It is sure to please them. The volume is nicely got up, and is profusely illustrated with high-class engravings.'—*Oldham Chronicle.*

Price Two Shillings net.

Handbook of Deductive Logic:

DESIGNED SPECIALLY FOR THE USE OF MEDICAL STUDENTS
PREPARING FOR THEIR PRELIMINARY EXAMINATION.

By REV. DUNCAN STEWART, D.D.,
MINISTER OF SPOTT, DUNBAR.

'Brevity and simplicity are the cardinal virtues in this book, because it has been designed specially for the use of young men intending to study medicine and preparing for their Preliminary Examination. A new feature in it is that not a few of the illustrations are medical, but the fundamental principles of logic being the same the world over, it is adapted to any other class of students. Brevity has been aimed at, but not to the detriment of perspicuity, and whatever help has been had from other writers on logic is mainly due to Jevons. As the work has been confessedly prepared for a purpose, the student is recommended not to pass over any of the questions on the several sections given at the end of the book till he is able to answer them. The questions and exercises are numerous and searching, and fitted to acquaint the student with the likely subjects of examination.'—*Glasgow Herald*.

Price One Shilling net.

A Manual of Dental Education

WITH SOME GENERAL NOTES UPON THE MODERN CURRICULUM OF
THE DENTAL STUDENT.

By ARTHUR TURNER,

Licentiate in Dental Surgery of the Royal College of Surgeons, Edinburgh; Dental Surgeon to the Buckinghamshire General Infirmary; Fellow of the Chemical Society.

'We can recommend it as affording much valuable information to those who think of studying dentistry.'—*Manchester Guardian*.

This is an epitomized guide for those about to enter upon the study of Dental Surgery with a view of obtaining the diploma, and will be found useful.'—*Edinburgh Medical Journal*.

'A manual such as we have now before us will be found most useful for intending dental students. It is a welcome and useful guide.'—*Glasgow Herald*.

Price 4s. net.

YELLOW FEVER

BY JAMES W. MARTIN, M.D.

ILLUSTRATED.

'It gives a very clear and concise account of the chief facts about yellow fever and its congeners among the malarial fevers of the tropics, and discusses its etiology and treatment at some length.'—*Lancet*.

'It presents a full narrative of yellow fever, its geographical distribution, and the clinical features which distinguish it from the intermittent and remittent fevers of the tropics. Dr Martin writes of the disease from a practical acquaintance with it, and his descriptions gain much in vividness thereby. A chart on Mercator's projection helps considerably towards a comprehension of the distribution of the disease, and there are also several charts of pyrexia of malarial origin. The work will be of service to those whose field of labour lies where the disease is prevalent.'—*Glasgow Medical Journal*.

'As the outcome of a practical experience of this tropical scourge, it cannot fail to be an acquisition. Without adding much that is new on the subject Dr Martin reviews and analyses the results of many observers. A number of cases are briefly reported in the appendix; these will help one to realise the condition which is met with in yellow fever patients.'—*Manchester Guardian*.

TEMPERATURE CHARTS:

Suitable for Hospitals, Dispensaries, or
Private Cases.

SPECIMEN COPIES FREE ON RECEIPT OF TWO STAMPS.

SPECIAL SIZES OR KINDS PRODUCED TO ORDER AT MODERATE RATES.

Third Edition. Greatly Enlarged and Improved.

Price One Shilling net.

THE URINE

In Health and in Disease. together with its
Chemical Examination.

By H. AUBREY HUSBAND, M.B., C.M.,

B.Sc., F.R.C.S.E., etc.,

*Formerly one of the Medical Officers of the Royal Dispensary, Edinburgh.
Author of the 'Student's Handbook of the Practice of Medicine,'
'Student's Pocket Prescriber,' &c.*

~~~~~  
WITH NUMEROUS PLATES.

---

Price 1s. 6d.

Illustrated by 26 Woodcuts.

# THE PHYSIOLOGY OF THE EYE,

With an Introductory Chapter on Optics.

By H. CAMPBELL, M.B.,

B.Sc. Lond., M.R.C.P. Lond., M.R.C.S. Eng.

~~~~~  
'This is an admirable little text-book, and will commend itself
to every student of physiology.'

Price One Shilling net,

Puberty and the Change of Life.

A Book for Women.

By J. C. WEBSTER, M.D., M.R.C.P.E.,

Assistant to the Professor of Midwifery and Diseases of Women in the University of Edinburgh.

'It should be read with profit by both mothers and daughters; its teachings are sound, and always on the side of that educated common sense which is but another name for science itself. The author's remarks on the evils attending the educational competition among girls deserve the attention of mothers especially. The health directions set forth in this manual, if followed out, cannot fail to avert much of the preventable pain and misery so characteristic of our modern civilisation.'—*Glasgow Herald*.

'The book is well written; some parts of it unquestionably are calculated to do good to suffering womankind.'—*Birmingham Medical Review*.

Price One Shilling and Sixpence net.

THE DISEASES OF THE EYE.

A Manual for Senior Students and Young Practitioners.

By J. ARTHUR KEMPE, F.R.C.S.,

Late Senior Demonstrator of Anatomy, Surgeons' Hall, Edinburgh.

USED IN THE EDINBURGH MEDICAL SCHOOLS.

'It is a book for those who now require to show a knowledge of the more common eye diseases before passing the final examinations. The arrangement is good, the information explicit, and after the student is done with it as an examination guide he will find it very useful in general practice.'—*Glasgow Herald*.

'This book gives a pithy digest of the symptoms and diagnosis of the commonest diseases of the eye with practical hints as to treatment.'—*Daily Free Press*.

New Edition. Revised and Greatly Enlarged.

Price 1s. 6d. net.

The Students' Pocket Prescriber

By H. AUBREY HUSBAND, M.B., C.M.,
B.Sc., etc.,

Author of 'The Students' Handbook of the Practice of Medicine,' 'The Urine, in Health and in Disease,' etc.

This Book is intended for Students and young Practitioners, and contains much useful information.

The Prescriptions are arranged thus:—

Alteratives.	Emetics and Expectorants.
Antacids.	Gargles and Inhalations.
Antispasmodics.	Lotions, Liniments & Ointments.
Aperients, Cathartics, and	Narcotics and Sedatives.
Anthelmintics.	Refrigerants and Salines.
Astringents.	Stimulants.
Caustics and Counter Irritants.	Tonics.
Diaphoretics and Diuretics.	Uterine Therapeutics.

WITH AN INDEX TO THE PRESCRIPTIONS.

'This little work is intended to remove the difficulties which students experience when commencing to prescribe. The 396 Prescriptions it contains illustrate the treatment applicable to a variety of cases. In the Introduction, the various points which have to be considered in prescribing are given very clearly. A complete List of Diseases, forming an index to the prescriptions, enables the student to select the line of treatment suitable to any particular case. The prescriptions, on the whole, are typical, well constructed, and are brought up to date so as to include combinations of new drugs. The student prescriber will find this book a most useful companion, adapted to his wants, and a veritable pocket-book; it can be easily carried in the waistcoat pocket.'—*British Medical Journal.*

Price One Shilling net.

REFERENCES TO NERVES:

Being Tabular Views of the Motor Nerves to Muscles, the Nervous Supply of the Principal Articulations and of the Skin, the Deep and Superficial Origins of the Cranial Nerves, etc.; with the most important effects following Solution of Continuity of Nerves.

~~~~~  
INVALUABLE TO THE ANATOMICAL STUDENT.

---

Price One Shilling net.

## Morphology of the Vertebrata;

DOG-FISH, COD, PIGEON, AND RABBIT;

WITH DEVELOPMENT OF THE DOG-FISH.

BY D. KNIGHT,

OF THE MUSEUM OF SCIENCE AND ART, EDINBURGH.

~~~~~  
ILLUSTRATED.

Price Sixpence net.

Case-Taking Book for Hospitals;

With Hints on Case-Taking, Normal and Abnormal
Temperatures, Weight of Adult Organs, etc.

~~~~~  
*The Synopsis used in the Royal Infirmary, Edinburgh.*

---

Part I.—Price Sixpence net.

# ATLAS OF CHEMISTRY:

Inorganic and Organic,

DESIGNED FOR THE USE OF

MEDICAL AND SCIENCE STUDENTS, AND SCIENCE TEACHERS IN  
SCHOOLS AND EVENING CLASSES.

By VICTOR V. BRANFORD, M.A.

---

Third Edition, Revised, price Sixpence net.

# Handbook of Animal Classification

FOR THE

Use of Medical and Science Students.

By VICTOR V. BRANFORD, M.A.

---

Price One Penny.

# ALCOHOL:

Its Action on the Body in Health.

By ALEXANDER WALKER, M.D.,

*Late Medical Officer of Health, Putney.*

---

'The author's impeachment of Alcohol is overpowering. The pamphlet ought to be circulated throughout the land by our Temperance Societies.'—*Oldham Chronicle.*

Price 2s. 6d. net.

[An EDITION DE LUXE, printed on Dutch hand-made paper and bound in half-morocco, price 5s. net—only 100 copies printed.]

ILLUSTRATED WITH OVER 100 CHARACTERISTIC SKETCHES & PEN & INK PORTRAITS.

*The Awful and Ethical Allegory*

OF

DEUTERONOMY SMITH

Or, The Life History of a Medical Student.

BY A STUDENT OF MEDICINE.

'Messrs E. & S. Livingstone have favoured us with a copy of the above brochure, and we have great pleasure in commending it to our readers. . . . The chequered career of "D. Smith" is profusely illustrated by a master-hand. Thumb-nail sketches of the Castle, Arthur's Seat, Princes Street, Torchlight Processions ("for behold the keepers of these houses were men of power and riches, and Deuteronomy heard with awe that the greatest of them was as a King in the land"), the sign of the Three Balls, and the Elders of the Temple, are only a few of the more noticeable ones. The vicissitudes of Deuteronomy's Life were many, and will, no doubt, strike a sympathetic chord in the hearts of our readers. Let them gather themselves together within the temple of Thespis, and sit in the high places therein; yea, even in the "gods" on Students' Nights, as did our hero. "Last stage of all" (as the Bard of Avon says) is the brass-plate of Deuteronomy Smith, M.D., F.R.C.S., etc., and we would wish our readers no better luck, even if they have, like our friend, made occasional aberrations from the pathis of virtue.'—*The Student*.

'This excellent series of University sketches are a sort of Pilgrim's Progress of Edinburgh University studentdom, recording the gradual development of the medical, from the crude and chrysalis stage to that of his full-grown and perfect butterfly existence, and the moral of the tale lies in this, that it is of universal application; and the medical of to-day can read in it lessons for himself just as sound as the generation for whom it was written. The humour of the narrative lies largely in this, that it is written in the Biblical style, which gives to the incidents related a *naivete* that is often irresistible.'—*College Column*.

Price Threepence.

DEUTERONOMY SMITH

OR,

The Life History of a Medical Student.

'This is one of the smartest brochures that has emanated from the University for a long time.'—*Evening Express*.





Crown 8vo., 411 pp., price 3s. 6d.

---

# CLAUDE GARTON

A Story of Dunburgh Student Life.

BY

THOMAS J. HENRY, F.R.C.S.E.,

AUTHOR OF 'DEUTERONOMY SMITH.'

---

'This highly interesting story by the author of "Deuteronomy Smith," itself an excellent testimonial, deals with the life and adventures of an Edinburgh medical student. It is written obviously by a man who knows all the ins and outs of our University. Our Professors and customs are faithfully depicted in a skilful and interesting manner. Claude Garton comes up to Edinburgh, or Dunburgh, as it is called in the book, and goes through the usual life of a man up here. We have been unable to find any instance of his being the worse for drink, thereby upholding the well-known sobriety of medical students. He experiences a Symposium, a Rectorial, and Professional Examinations, and finally graduates. One of the best and most faithful descriptions in the book is that of a Police Court the day after a torchlight procession. Garton falls in love with a damsel called Gipsy, who resides in an establishment known as the Royal Britannia, and shortly termed "R.B." It will be seen that the book is well up to date, and deals with incidents of much interest to Edinburgh men. We are introduced to many whose names are curiously familiar. The story is interestingly written, and will be read with avidity by Edinburgh men in particular and medical students in general.'—*The Student*.

'Mr Henry has given us a very striking book, even more powerful, in its way, than George Moore's masterpiece, "Esther Waters." It describes the experiences of a medical student in Edinburgh, from his entry to the day when he is "capped" for his diploma, and each scene stands out distinct and clear, a triumph of detailed and effective realism. "The dissecting room," "The Rectorial election," "The setting of a star," "The mysteries of quackery," "A chloroform case," "Professor Frean performs an operation,"—to read these chapters, and they are a sample of the rest, is never to forget them; it is as though we had been present at the scenes described. Conan Doyle has done nothing

better, and they stand comparison with Mr Henley's poems. The weak points in the book are the story and the hero, but these are throughout subordinate, and their weakness merely goes to show that the author's sense of humour is defective. The defect is not one to be regretted, for, probably, it is the necessary accompaniment of the rare gift which goes along with it. Mr Henry has done for the Medical School of Edinburgh what Tom Hughes did for Rugby; in the work of either there is something to condone, but the something is as nothing when we regard the whole. The book should be in the hands of all medical students, and of all who are interested in the science of medicine. It does not address itself to others, and the "general reader" had, perhaps, better keep away from it.—*Sheffield Daily Telegraph*.

'In "Claude Garton" the career of a medical student during his five years' course at Dunburgh University—the identity of which with the chief of Scottish Universities is thus thinly veiled—is related with unusual ability. So perfect an acquaintance with the customs and routine of the University is revealed as to warrant the belief that the author is describing none other than his own alma mater. Some of the descriptions—especially those of the operating rooms and a couple of operations therein—are, perhaps, rather too realistic to be pleasant; and we can imagine that not a few sensitive readers will turn from the further perusal of the book with disgust. But they will do well to persevere, for the story is one of extraordinary fascination and dramatic power, and it is, moreover, written in excellent, if somewhat grandiloquent English. It is not, however, a hook for boys; it will be better appreciated by grown-up readers.'—*St James' Gazette*.

'The career of a medical student is a subject that does not suggest material for an attractive story, yet here we have not only a readable but really an admirable book. The ways and methods of the hudding doctor the author has hit off to a nicety, and Claude Garton's connection with Dumburgh University is a refreshing episode of life that is strong in its realism. Many types of character are to be found in its pages that have their counterparts in real life. One dwells with appreciation in the society of MacIvor, Mostyn, and Murchiston; though sadness describes the feeling at the fate of poor White. The love entanglements of Claude lend interest, at times pathetic, to the work, while the light that is thrown on the ordinary life of the medical practitioner with his difficulties and disappointments, is lucid and entertaining. Jack Lasting, the champion boozier of the University, serves to illustrate the quackery of to-day in all its hideousness. Mr Henry is to be congratulated on this excellent contribution to the season's literature.'—*Manchester Courier*.

'As a story this can be recommended to all who like their literature clean and wholesome, and yet with a thorough spice of life and sensationalism. It is the career of a medical student as lived at the great university, interwoven with a thrilling and romantic love story. The action never lags, and the glimpses of science we are allowed to get now and again in the operating theatre and dissecting-room, are up-to-date, and redolent of the newest discoveries. It is not only a book to amuse, but one from which something of profit may be gained.'—*Lloyd's Weekly News*.

**PUBLISHED ANNUALLY.**

Crown 8vo, price 2s.; by post, 2s. 3d.

# Medical School Calendar

## FOR SCOTLAND,

*Is the only book that contains all the information required for Graduation in Medicine, Surgery, and Public Health at Edinburgh, Aberdeen, Glasgow, and St Andrews Universities; Fellowship, Membership, and Licence of Royal College of Physicians; Fellowship, Licence, and Licence in Dental Surgery; Diploma in Public Health of Royal College of Surgeons; Triple Qualification of Scottish Conjoint Board; Classes in the Universities and Schools of Medicine, with short Syllabus of each Class; Classes and Schools for Women; Dispensaries, Students' Societies, &c.; also the*

### PROFESSIONAL EXAMINATION QUESTIONS

*set by the Universities, Royal College of Physicians, Royal College of Surgeons, and the Triple Board, for several years past; the Universities Preliminary Examination Questions set in October and March, and the Preliminary Examination Questions set by the Educational Institute of Scotland.*

~~~~~

'It is full of the most useful information. It ought to be a most valuable work of reference for the medical student.'—*Edinburgh Medical Journal.*

'Much time and money may be saved by a careful perusal of this book.'—*Medical Press and Circular.*

'The Medical School Calendar maintains its reputation for comprehensiveness and accuracy of information.'—*Scotsman.*

The book is crammed with information on all subjects which a student requires to know in piloting his way through a course of medical study. A page of well compiled advice to the student as to the most advantageous method of study is given. A glance through the pages of the Calendar shows the extensive provision for medical education in Edinburgh, and is itself the most convincing argument for the necessity of the publication.'—*Edinburgh Evening News.*

